

---

# SPECIALIST VISION-LANGUAGE MODELS FOR CLINICAL OPHTHALMOLOGY

---

Robbie Holland<sup>1</sup>, Thomas R. P. Taylor<sup>2</sup>, Christopher Holmes<sup>3</sup>, Sophie Riedl<sup>4</sup>, Julia Mai<sup>4</sup>, Maria Patsiamanidi<sup>2</sup>, Dimitra Mitsopoulou<sup>2</sup>, Paul Hager<sup>5</sup>, Philip Müller<sup>5</sup>, Hendrik P. N. Scholl<sup>6,7,8</sup>, Hrvoje Bogunović<sup>4</sup>, Ursula Schmidt-Erfurth<sup>4</sup>, Daniel Rueckert<sup>1,5,†</sup>, Sobha Sivaprasad<sup>3,†</sup>, Andrew J. Lotery<sup>2,†</sup>, and Martin J. Menten<sup>1,5,†</sup> on behalf of the PINNACLE consortium

<sup>1</sup>Biomedical Image Analysis, Department of Computing, Imperial College London, United Kingdom

<sup>2</sup>Clinical and Experimental Sciences, Faculty of Medicine, University of Southampton, United Kingdom

<sup>3</sup>Moorfields Eye Hospital NHS Foundation Trust, London, United Kingdom

<sup>4</sup>Laboratory for Ophthalmic Image Analysis, Medical University of Vienna, Austria

<sup>5</sup>Institute for AI in Healthcare and Medicine, Klinikum rechts der Isar, Technical University of Munich, Germany

<sup>6</sup>Institute of Molecular and Clinical Ophthalmology Basel, Switzerland

<sup>7</sup>Department of Ophthalmology, University of Basel, Switzerland

<sup>8</sup>Department of Clinical Pharmacology, Medical University of Vienna, Austria

## ABSTRACT

Clinicians spend a significant amount of time reviewing medical images and transcribing their findings regarding patient diagnosis, referral and treatment in text form. Vision-language models (VLMs), which automatically interpret images and summarize their findings as text, have enormous potential to alleviate clinical workloads and increase patient access to high-quality medical care. While foundational models have stirred considerable interest in the medical community, it is unclear whether their general capabilities translate to real-world clinical utility. In this work, we show that foundation VLMs markedly underperform compared to practicing ophthalmologists on specialist tasks crucial to the care of patients with age-related macular degeneration (AMD). To address this, we initially identified the essential capabilities required for image-based clinical decision-making, and then developed a curriculum to selectively train VLMs in these skills. The resulting model, RetinaVLM, can be instructed to write reports that significantly outperform those written by leading foundation medical VLMs in disease staging (F1 score of 0.63 vs. 0.11) and patient referral (0.67 vs. 0.39), and approaches the diagnostic performance of junior ophthalmologists (who achieve 0.77 and 0.78 on the respective tasks). Furthermore, in a reader study involving two senior ophthalmologists with up to 32 years of experience, RetinaVLM’s reports were found to be similarly correct (78.6% vs. 82.1%) and complete (both 78.6%) as reports written by junior ophthalmologists with up to 10 years of experience. These results demonstrate that our curriculum-based approach provides a blueprint for specializing generalist foundation medical VLMs to handle real-world clinical tasks.

## 1 Introduction

Medical images are central to many clinical decisions regarding patient diagnosis, referral, and treatment. Clinicians spend a significant amount of time transcribing image-based decisions into text in order to store and communicate their findings [1,2]. Visual-language models (VLM), which automatically interpret medical images and generate detailed textual descriptions, have enormous potential to alleviate clinical workloads and increase patient access to high-quality medical care [3,4]. To date, the majority of medical VLMs have been trained to output a finite set of pre-determined textual responses [5,6,7,8]. Only recently, the combination of large language models (LLM) with

---

<sup>†</sup> denotes shared senior authorship

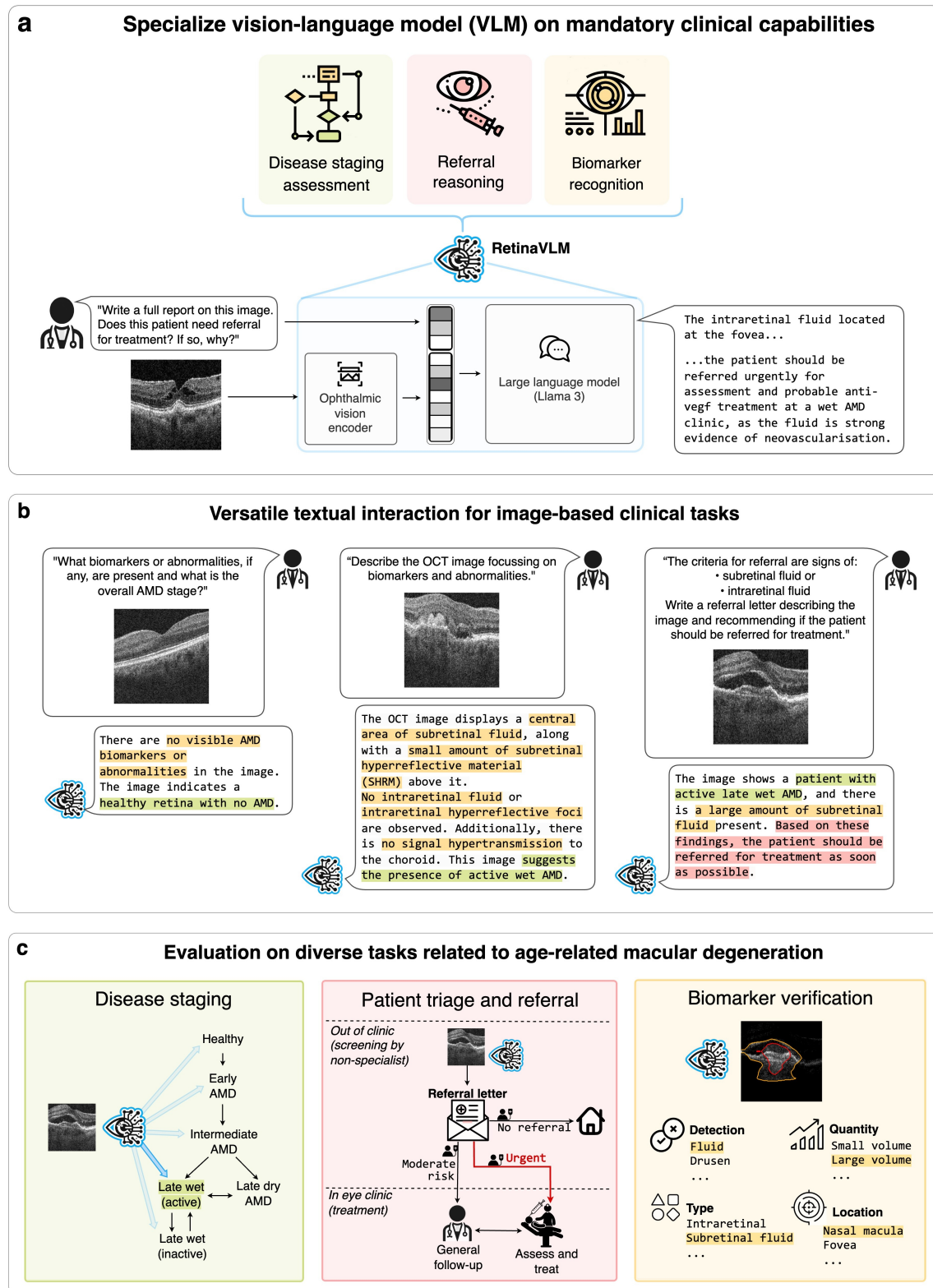


Fig. 1: We introduce RetinaVLM, the first specialist medical generative vision-language model (VLM). (a) Using a needs-driven training curriculum, we trained RetinaVLM in specialist medical skills that medical foundation VLMs are currently lacking (b) RetinaVLM is able to process retinal optical coherence tomography (OCT) images and flexibly respond to text-based queries. (c) Its abilities entail the analysis of imaging biomarkers of age-related macular degeneration (AMD), disease staging, and the referral for treatment.



medical vision encoders has led to the development of more powerful and versatile *generative* VLMs that are able to write comprehensive text reports or answer complex questions [9,10,11].

This current generation of medical language models is fueled by vast amounts of unstructured training data that is extracted from medical textbooks, scientific publications or social media posts of healthcare professionals [9,6,10]. These *foundation* language models have stirred considerable interest among the medical community for their expert-level performance on standardized medical question-answering tasks, such as licensing exams and case studies [12,13]. However, it is unclear whether this general performance translates to clinical utility in specialist medical domains [14]. Despite its impressive scale, the training data of foundation language models has been collected agnostically towards their downstream application and inherently lacks specialist information related to the challenges faced by clinicians in their daily practice.

In this study, we identify this missing piece in foundation models with the aim of developing generative medical VLMs with real-world clinical utility. We propose to deconstruct clinical problems into sets of mandatory capabilities required for their resolution and selectively train VLMs in these skills. We demonstrate the feasibility of this approach in ophthalmology. To this end we introduce RetinaVLM, the first specialist medical generative VLM (see Figure 1a). RetinaVLM is trained using a dedicated curriculum that is specific to the clinical management of age-related macular degeneration (AMD), the leading cause of blindness in the elderly [15,16]. It is able to process optical coherence tomography (OCT) images of the retina and flexibly respond to instructions and questions (see Figure 1b). In extensive experiments, we evaluate RetinaVLM’s utility and versatility regarding disease staging, patient referral and biomarker analysis in AMD (see Figure 1c).

## 2 Results

### 2.1 RetinaVLM, a specialist vision-language model for retinal image analysis

RetinaVLM combines two main components: an ophthalmic vision encoder that processes input OCT images, and a generative LLM that handles textual instructions and outputs the corresponding responses (see Figure 1a). The vision encoder is based on our previous work, in which we found it to perform on par with RETFound [17], a large foundation model for retinal image analysis [18]. We use Meta’s Llama 3 as generative LLM, the best performing model that is openly available at the time of this study [19]. However, without additional training it lacks specialist knowledge related to the analysis of OCT images and the clinical management of AMD. Both these deep neural networks have already been pre-trained on large OCT and natural language datasets, respectively, and we only finetune them in the scope of this study. Additional details about the network architecture and training are included in Section 5.2.

### 2.2 A curriculum to encode specialist ophthalmological knowledge in vision-language models

An intuitive strategy to specialize VLMs while preserving their ability to flexibly interact with text queries is to provide them with a set of medical images and corresponding question-answer pairs. They are then optimized based on the similarity of their predicted answers to the ground truth. However, *visual question-answering* (VQA) datasets do not exist for most medical specializations, including ophthalmology.

Together with a large team of ophthalmologists, which are involved with the patient care and academic research of AMD, we defined a set of required capabilities for accurate image-based clinical management of AMD. They include the identification of AMD biomarkers in OCT images, the linking of these to the AMD disease stage, and ultimately deciding on the required referral and treatment of the patient. We then curated a training curriculum, which consists of 41,926 OCT images, and 479,710 visual questions and answers to progressively specialize VLMs in these capabilities.

**Curriculum part 1: Introduction to retina** The first part of the curriculum, named *Introduction to retina*, primarily covers the appearance of the retina and AMD biomarkers in OCT images. Using automated data collection, we obtained tabular reports for 41,926 retrospectively collected OCT images of AMD patients (see Figure 2a). Each report describes the visible biomarkers, patient’s diagnosis, visual acuity and demographic information in 34 data fields. A full description of the OCT dataset can be found in Section 5.1.1, the list of all tabular data fields and example tabular reports in Figure 7, and the methodology for their automated procurement in Section 5.4.1.

Next, we tasked an independent LLM to generate question-answer pairs based on these reports (see Figure 2c). The model processed the content of the tabular reports – but not the OCT images – to output a numbered list of question-answer pairs. We generated an average of ten question-answer pairs per report that are mostly related to the presence or absence of specific biomarkers (see Figure 2e). The LLM was instructed to create both closed-ended ‘yes or no’ style questions, and simple open-ended questions. Detailed information on the LLM setup can be found in Section 5.4.1.

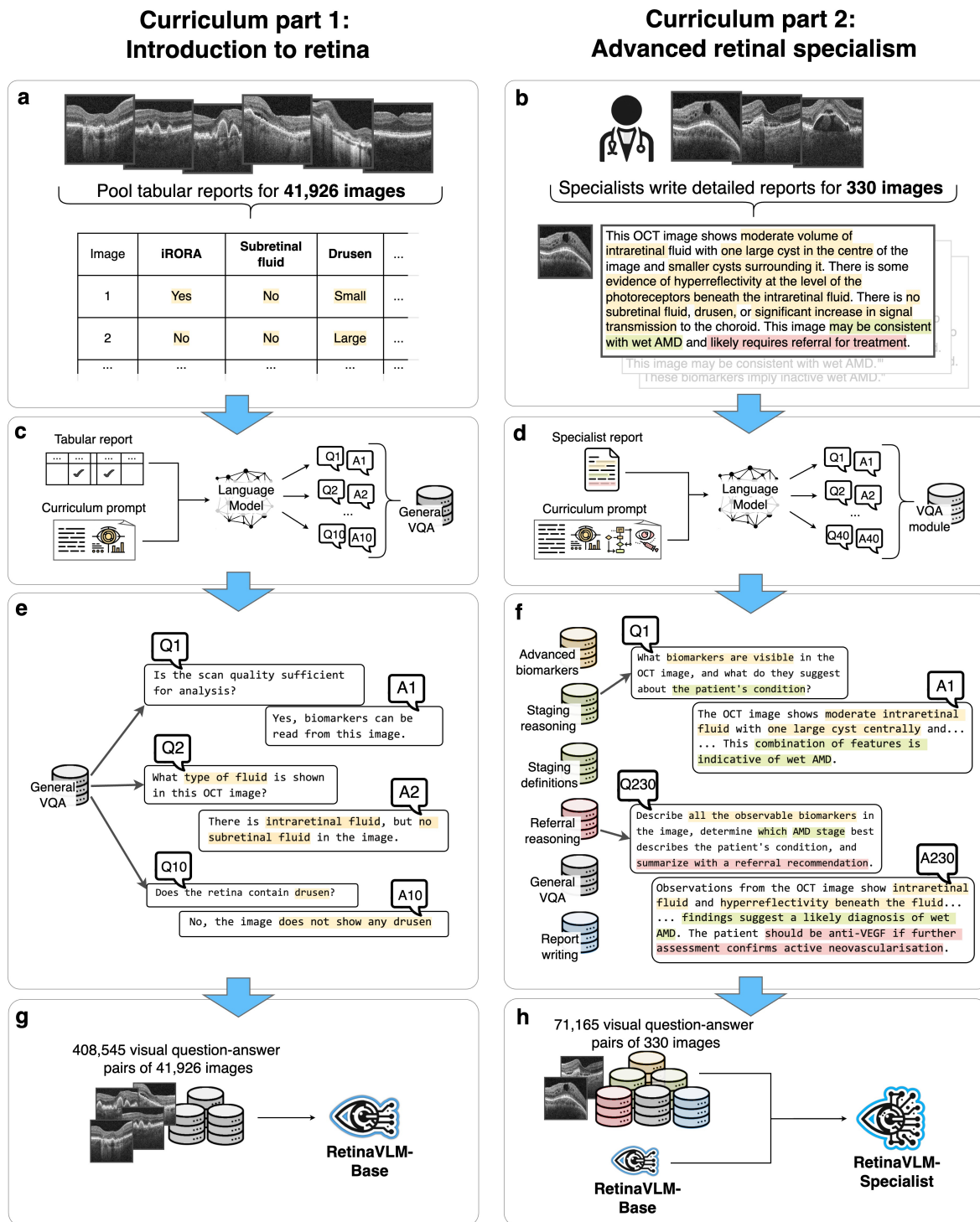


Fig. 2: We curated a two-part curriculum to specialize medical VLMs for clinical use. (a and b) Based on a retrospectively collected OCT imaging dataset, we created a large number of tabular reports as well as a small number of comprehensive textual reports. (c and d) We then used an independent LLM to automatically generate visual question-answers (VQA) based on these reports. (e and f) This yielded two VQA datasets, the first on basic imaging biomarkers of AMD and the second covering more advanced clinical skills. (g and h) Finally, we trained two specialist medical generative VLMs, RetinaVLM-Base and RetinaVLM-Specialist, using either the first or both VQA datasets.

This automated approach allowed us to generate a large dataset of 408,545 question-answer pairs. However, the questions were limited in scope to the set of biomarkers documented by the tabular reports. Training on these yielded the first of two specialist VLMs, *RetinaVLM-Base* (see Figure 2g).

**Curriculum part 2: Advanced retinal specialism** The second part of the curriculum, named *Advanced retinal specialism*, builds on top of the first part to link imaging biomarkers to AMD stage and the recommended course of treatment. As this reasoning cannot be fully conveyed via tabular information, we tasked two ophthalmologists with 3 and 10 years of experience, respectively, to create comprehensive textual reports for a subset of 330 OCT images (see Figure 2b). The ophthalmologists were asked to primarily describe the main pathological biomarkers related to AMD while also noting any other observations regarding the retinal anatomy. This task yielded high-quality reports that go beyond the short notes that are typically written by ophthalmologists in their clinical routine. Instructions given to the ophthalmologists as well as a set of sample reports are provided in Section 5.4.2 and Figure 8, respectively.

Similar to before, an independent LLM was then employed to automatically generate question-answer pairs based on the reports (see Figure 2d). Due to the substantially increased depth and scope of the full-text reports compared to the tabular ones, we used several advanced LLM instructions to create 216 diverse question-answer pairs per image on average (see Figure 2f). These cover additional biomarkers and sub-categorize them based on their size, type, and location. Other question-answer pairs are related to the causal relationship between biomarkers and six AMD disease stages as well as three levels of patient referral urgency. Moreover, the question-answer pairs were more varied in their structure in order to preserve interactive capabilities of the foundation LLM. For example, some queries asked to summarize the existing reports or provide several answers in succession. An example interaction with the LLM to generate question-answer pairs with the LLM is shown in Figure 9. Furthermore, a list of all the LLM instructions is provided in Section A.2 and example question-answers yielded by this approach are shown in the ‘part 2’ section of Figure 10.

This resulted in a dataset of 71,165 advanced question-answer pairs. By further training *RetinaVLM-Base* on the second part of the curriculum, we obtained our most performant VLM for the clinical management of AMD, *RetinaVLM-Specialist* (see Figure 2h).

### 2.3 *RetinaVLM-Specialist* outperforms foundation models and approaches junior ophthalmologists in AMD disease staging and report writing

Estimating the disease stage is crucial to patient management as it allows clinicians to monitor and treat patients using standardized protocols. We assessed the ability of four different generative VLMs to determine the AMD disease stage from retinal OCT images. Specifically, we compared two medical foundation VLMs, *Med-Flamingo* [10] and *LLaVA-Med* [9], to our two specialist VLMs, *RetinaVLM-Base* and *RetinaVLM-Specialist*. Using a testing dataset of previously unseen 276 OCT images, VLMs were tasked to write reports that describe the OCT image before classifying the patient into one of six disease stages (see Figure 3a). The model predictions were compared to ground truth labels obtained from ophthalmologists. Each image was initially graded by two out of six junior ophthalmologists, whose experience in the field ranges from 2 to 15 years. Inter-rater disagreements were resolved by a panel of two senior ophthalmologists with 25 and 32 years of experience, respectively. For additional methodological details, including the instruction given to the VLMs to generate these reports, see Section 5.8.1.

We found that our intermediate *RetinaVLM-Base* model already performs significantly better than both foundation VLMs, which lack the ophthalmological specialism to stage disease (see Figure 3b). The most performant foundation VLM, *Med-Flamingo*, achieved a F1 score of 0.11. This was markedly outperformed by our advanced *RetinaVLM-Specialist* model, scoring at 0.63. This approached, but did not match, the accuracy of the junior ophthalmologists who achieved an F1 score of 0.78. We analyze this discrepancy in detail in Section 3. Both foundation VLMs and *RetinaVLM-Base* returned a substantial number of invalid reports that did not conclude with one of the six disease stages (see Figure 3c). Conversely, all generated reports by *RetinaVLM-Specialist* were valid. Similar to human experts, *RetinaVLM-Specialist* struggled the most when diagnosing wet inactive AMD. We attribute this to the high number of shared imaging biomarkers that indicate either intermediate and late-wet forms of AMD, which sometimes leads to misdiagnosis by both ophthalmologists and *RetinaVLM-Specialist* (see Figure 3d). This was despite the identification of emerging features related to inactive late wet AMD (a small amount of hyperreflective material, or scar tissue) by *RetinaVLM*. Four more examples of success and failure cases of *RetinaVLM-Specialist* are shown in Figure 11a. Moreover, full numerical results as well as the confusion matrix for *Med-Flamingo* are shown in Figure 12 and 13, respectively.

Eighty-four of the generated reports were scored by the two senior ophthalmologists for their correctness, completeness, and conciseness. They were shown 28 reports written by *LLaVA-Med*, 28 by *RetinaVLM-Specialist*, and 28 by the two annotating junior ophthalmologists in random order without knowledge of the author. For each report, the senior

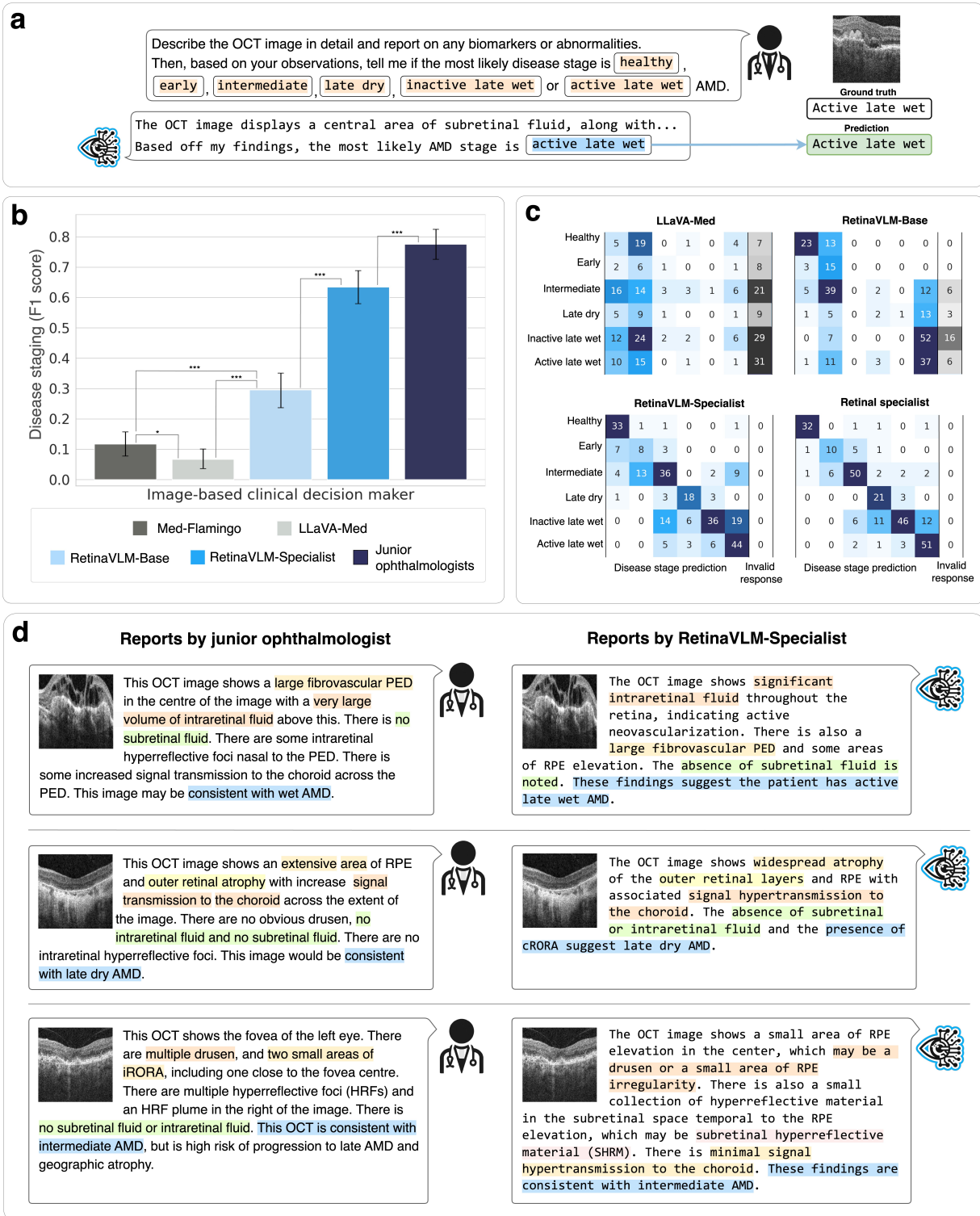


Fig. 3: (a) Comparison of the ability of four VLMs to write reports on retinal OCT images and derive the AMD stage. (b) Overall staging accuracy for each model was calculated using micro F1 scores with 95% CI, with tests of statistical significance calculated using McNemar’s test. (c) Confusion matrices between the senior ophthalmologists’ assessments (rows) against the image-based clinical decision maker’s prediction (columns). (d) Qualitative comparison of reports written by human ophthalmologists and RetinaVLM-Specialist with text markings highlighting findings regarding biomarker observations and disease stage.

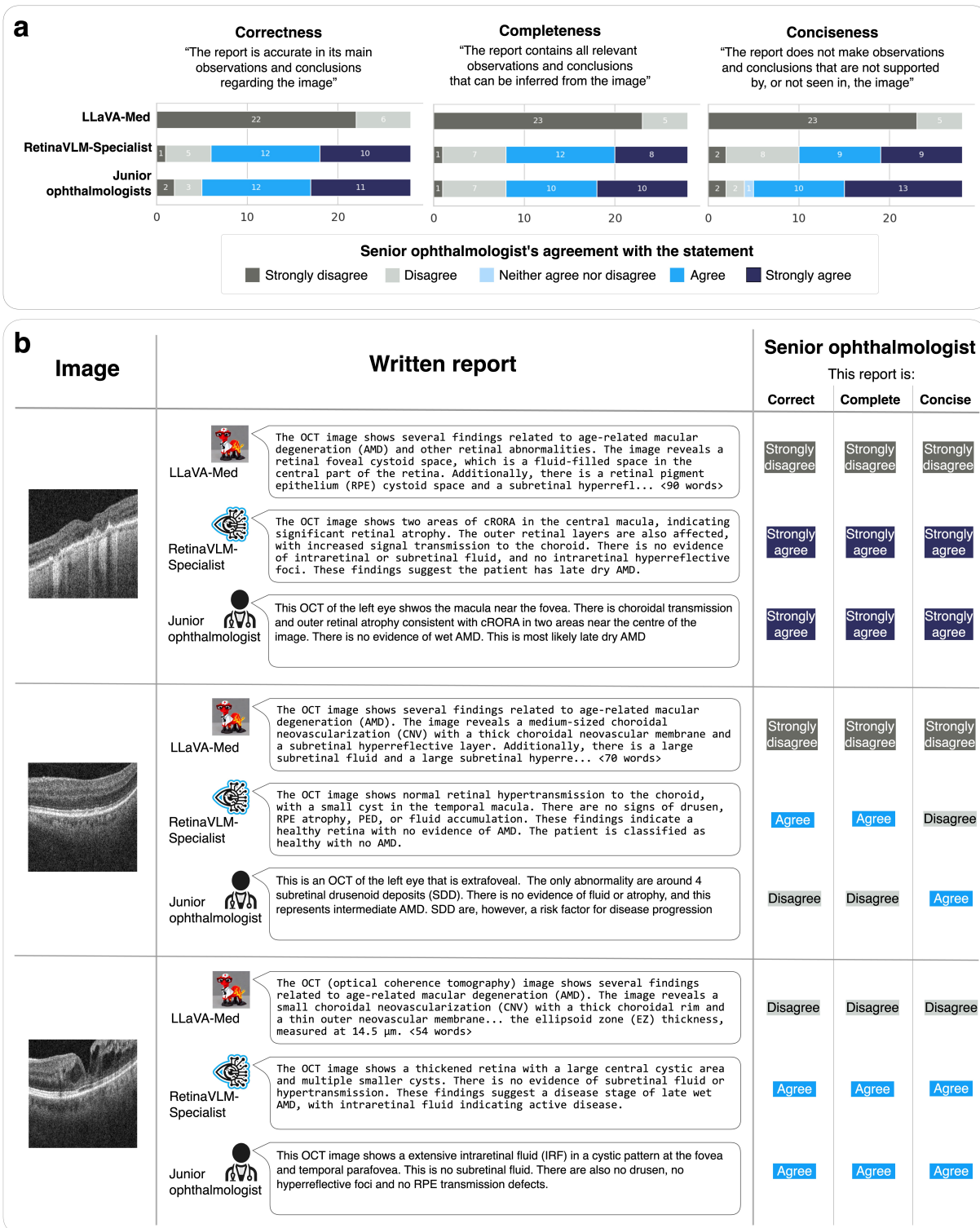


Fig. 4: (a) Correctness, completeness and conciseness of the reports written by LLaVA-Med, RetinaVLM-Specialist and junior ophthalmologists. Reports were scored for on each of the three criteria by senior ophthalmologists using a five-point Likert scale. (b) Representative reports with ratings by one of the senior ophthalmologists.

ophthalmologist first reviewed the corresponding OCT image before rating the generated report in the three criteria on a five point Likert scale [20].

Echoing our previous findings, the senior ophthalmologists observed that LLaVA-Med failed to comprise factually correct image reports (see Figure 4a), even though it uses specialist terminology that may give the reports the initial appearance of being composed by an ophthalmologist (see Figure 4b). LLaVA-Med also failed to keep reports brief, despite being explicitly instructed to do so.

Conversely, the reports generated by RetinaVLM-Specialist were mostly graded as correct and complete and of similar quality as those written by junior ophthalmologists. Specifically, out of the 28 reports, the senior ophthalmologists either agreed or strongly agreed that 22 (78.6%) written by RetinaVLM-Specialist, and 23 (82.1%) written by junior ophthalmologists, were correct in their observations and conclusions. Similarly, they found that for 20 (71.4%) of the images, neither of these report writers missed any features that were relevant to AMD.

Reports by RetinaVLM-Specialist were deemed to be slightly less concise, where 18 out of 28 (64.3%) were rated as complete compared to 23 (82.1%) by the junior ophthalmologists. This discrepancy can be seen in the second sample in 4b, where RetinaVLM-Specialist correctly identified that the image showed a healthy retina, but also detects a small cyst that was not found in the image, resulting in a lower conciseness rating. Junior ophthalmologists wrote a concise report, but incorrectly associated subretinal drusenoid deposits with intermediate AMD. These shortcomings of both the junior ophthalmologists and RetinaVLM-Specialist are discussed in more detail in Section 3.

## 2.4 RetinaVLM-Specialist surpasses opticians and approaches junior ophthalmologists in AMD patient screening and referral

As the prevalence of AMD is expected to further increase in the upcoming decades [16], ocular screening programs are being introduced around the world. In the United Kingdom, some projects involve opticians and pharmacies that acquire and interpret OCT images. They may refer a patient to a specialist clinic, summarizing their findings and the estimated level of the patient’s risk in a letter. In the United Kingdom, treatment guidelines for AMD mandate that patients with signs of neovascularization are referred for immediate treatment within two weeks. However, non-specialists exhibit a tendency to over-diagnose these cases. An internal audit at Southampton Eye Unit found that 74.2% of the referrals made to the clinic do not have any form of treatable AMD. The processing and assessment of these false positives affects the clinic’s ability to care for the remaining patients with treatable forms of AMD.

We evaluated the ability of VLMs to assess the level of referral urgency from OCT image (see 5a). For each case, the VLMs were provided explicit referral guidelines, and asked to recommend which of three levels of referral urgency was most appropriate for the patient: *no referral* for healthy patients, *to be seen within 18 weeks (routine referral)* for patients that are at risk of progressing to active late wet AMD but do not require treatment yet, and *referral within two weeks* for patients with any signs of neovascularization that should be urgently referred for antiangiogenic treatment. Two junior ophthalmologists independently reviewed images of 95 patients that have previously been referred to the hospital for treatment of wet AMD. For each patient, they independently decided the most appropriate of the three levels of referral urgency, and disagreements were arbitrated by the two senior ophthalmologists. In line with previous audits, they found the false discovery rate for urgent referrals was 69.5%. We then calculated F1 scores for the highest risk patients in need of urgent referral between the VLM’s predictions and the ground truth. The full referral protocol and report generation instructions given to the VLMs are provided in Section 5.8.3.

We found that both medical foundation VLMs and Retina-Base perform worse than opticians regarding their ability to refer patients in need of urgent treatment (see Figure 5b). While Med-Flamingo failed to refer any of the 29 high-risk patients cases, LLaVA-Med and RetinaVLM-Base were ineffective for differentiating high-risk patients from low- to moderate-risk patients (see Figure 5c). RetinaVLM-Specialist was able to detect 23 out of the 29 high-risk cases that require immediate treatment. At the same time, RetinaVLM’s false discovery rate, defined as the ratio of the number of false positives over the number of predicted positives, of 42.5% is substantially lower than that of opticians at 69.5%. Owing to their ability to better differentiate moderate from high-risk cases, the human ophthalmologists had the lowest false discovery rate of 9.1%, although they simultaneously missed three more cases in urgent need for treatment.

In practice, referral letters should communicate the reason for referral by citing suspected abnormalities in the OCT image that can inform the ophthalmologist’s initial diagnostic plan. As in the conciseness study in Figure 4, RetinaVLM-Specialist sometimes documents the presence of small biomarkers that cannot be found in the image. More often, RetinaVLM-Specialist wrote an accurate imaging report but did not accurately follow the complex set of referral guidelines provided in the instruction. This led RetinaVLM-Specialist to incorrectly recommend that 17 of the moderate-risk patients potentially require treatment. However, this occurred less for the 25 low-risk patients, where RetinaVLM-Specialist correctly identified patients with little or no abnormalities, which are often referred to the treatment clinic for a second opinion by non-specialists (samples 1 and 3 in Figure 5d). Crucially, we find



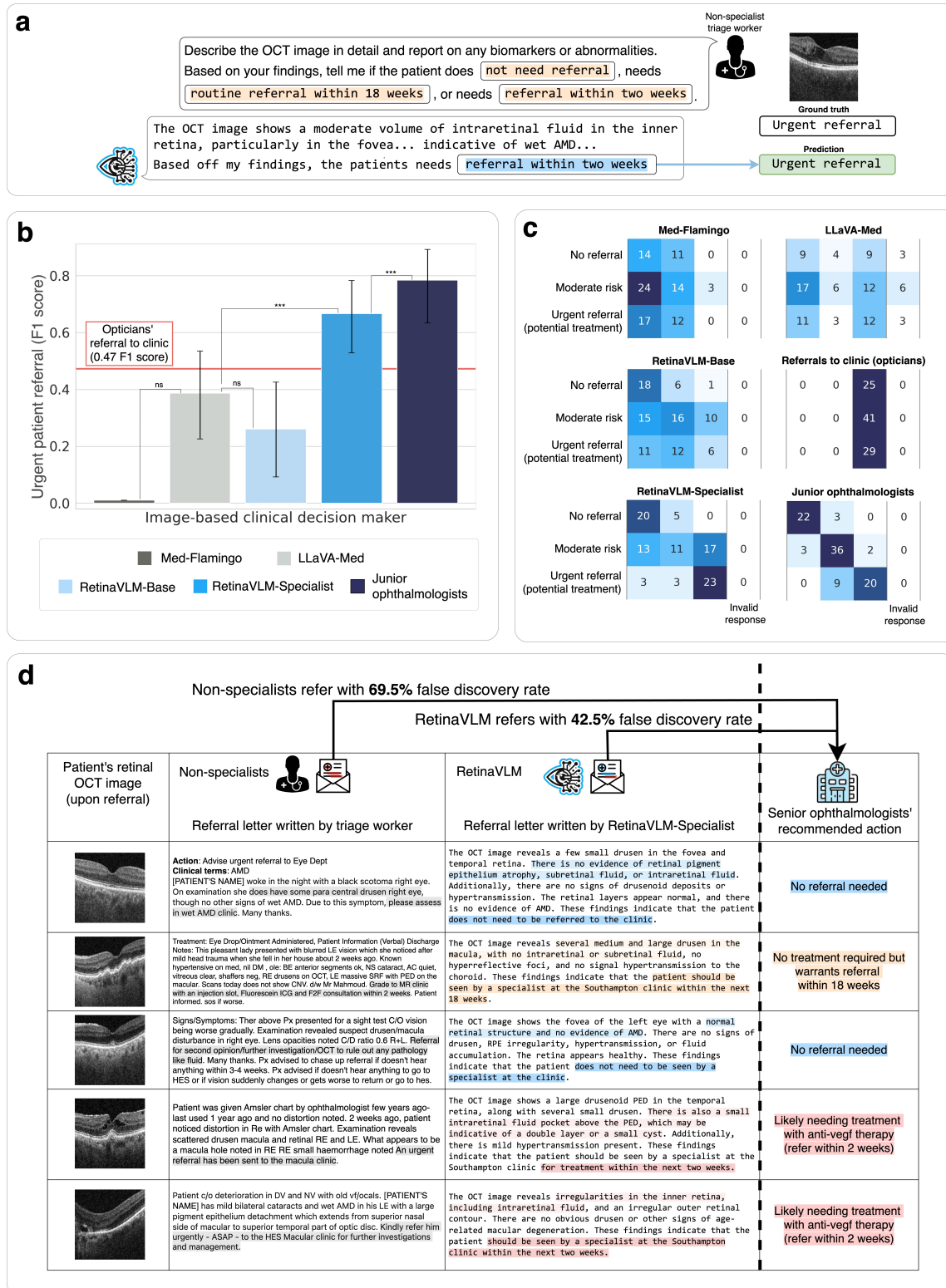


Fig. 5: (a) Evaluation of the ability of four VLMs to assess the need for patient referral for treatment of wet AMD. (b) Overall referral accuracy was calculated using F1 score for urgent referral with a 95% CI. Tests of statistical significance were carried out using McNemar's test. The performance of individual ophthalmologists is shown by two white points. (c) Confusion matrices between the senior ophthalmologists assessment (rows) against the image-based clinical decision maker's referral assessment (columns). (d) Image reports written by the non-specialist optician who originally referred the patient, compared with reports of the same patient written by RetinaVLM-Specialist.

that RetinaVLM-Specialist is effective in the detection of intraretinal cysts and fluid that differentiate high-risk from moderate-risk patients (samples 4 and 5). Four more examples of success and failure cases of RetinaVLM-Specialist are shown in Figure 11b.

## 2.5 RetinaVLM accurately detects imaging biomarkers to make recommendations

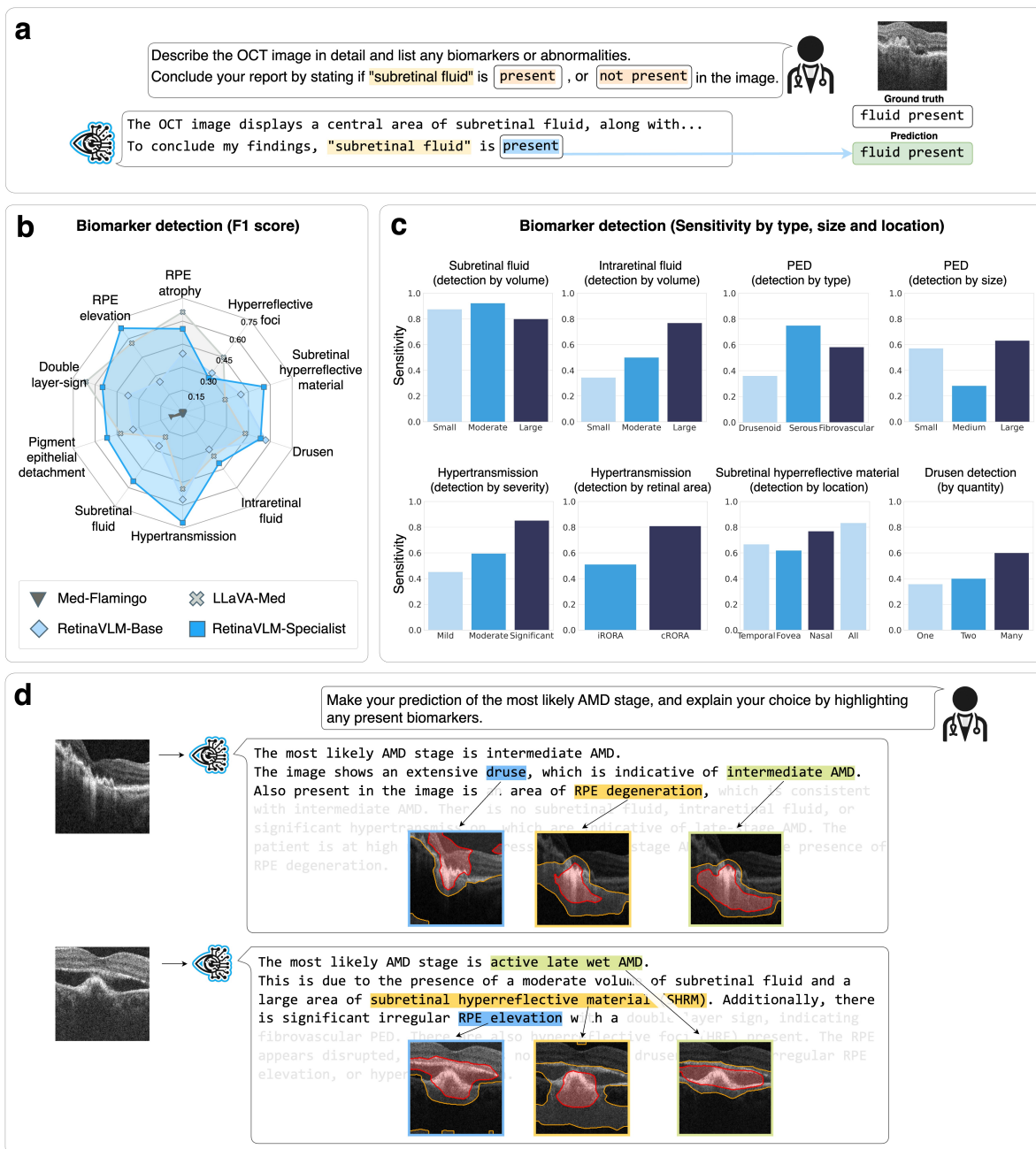


Fig. 6: (a) We test four VLMs on their ability to describe the presence of 10 important imaging biomarkers of AMD. (b) Overall detection accuracy was computed using F1 scores. (c) Detection sensitivity for each level of biomarker severity for the most important biomarkers. (d) Regions highlighted by RetinaVLM-Specialist that correspond with different biomarkers and disease stage assessments in its written report. Regions with greater than 25% and 50% importance are highlighted by yellow and red contours, respectively. Four additional examples are shown in Figure 14.

It is important that clinical decision makers can provide evidence for their recommendations. Disease staging reports and written referral recommendations commonly contain descriptions of the most salient biomarkers that were detected in the scan. We tested the ability of four VLMs to correctly identify the presence or absence of 10 different biomarkers related to AMD. To this end, all VLMs were tasked with writing reports for 396 OCT images that conclude by stating the presence or absence of the biomarker in question (see Figure 6a). The VLMs predictions were compared against the ground truth labels obtained from junior ophthalmologists. The instruction used to generate these biomarker focused reports is provided in Section 5.8.4.

We find that RetinaVLM-Specialist outperforms both LLaVA-Med and Med-Flamingo in the detection of seven out of the ten of main biomarkers related to AMD (see Figure 6b). Biomarkers that were more severe, larger, and more numerous were detected with higher accuracy by RetinaVLM-Specialist than less advanced presentations (see Figure 6c). Most of the smaller biomarkers, such as small amounts of intraretinal fluid, drusen and hyperreflective foci, which can be as small as  $30 \mu m$  in size [21], were detected with lower sensitivity. Overall, clinically important hallmarks of late AMD were detected with a very high sensitivity. Large volumes of subretinal and intraretinal fluid were detected in 80% and 78% of cases, respectively, and severe levels of hypertransmission in 84% of cases.

Finally, to visualize the functioning of RetinaVLM-Specialist, we calculated saliency maps based on Grad-CAM [22]. These saliency maps highlight the image regions deemed most important by the model when writing specific passages of the report (see Figure 6d). We refer to Figure 14 for four additional image reports with corresponding saliency maps. We qualitatively found that RetinaVLM-Specialist is influenced by different imaging biomarkers when writing different passages of the report, and in making its final recommendation. We observed the saliency maps were especially effective for highlighting hyperreflective material, RPE irregularities and hypertransmission.

### 3 Discussion

#### Main findings of the study

In this study, we have presented RetinaVLM, the first specialist generative visual language model in medicine. Given a retinal OCT image, RetinaVLM provides accurate, detailed textual responses related to disease staging, referral or biomarker identification of AMD. While large foundation deep learning models have been employed for retinal image analysis before [23,18], our generative VLM is the first model that can flexibly process varied textual queries related to complex ophthalmological decisions and return detailed written responses. Through the use of language as primary communication medium, artificial intelligence systems are able to dynamically perform new tasks and meet the evolving requirements of image-based clinical decision makers.

In extensive experiments, RetinaVLM significantly outperformed state-of-the-art generative VLMs designed for medical use. We found that these are unable to interpret OCT images, derive the AMD disease stage and follow standard referral guidelines for AMD. Specifically, we have shown that in disease staging, RetinaVLM surpasses LLaVA-Med, the most performant open-source medical VLM, and is approaching the accuracy of junior ophthalmologists. When testing the ability of VLMs to screen for high-risk patients, LLaVA-Med substantially underperforms compared to junior ophthalmologists and even non-specialist opticians. In comparison, RetinaVLM-Specialist’s reports reduced the number of incorrect urgent referrals by almost four times compared to opticians and had higher recall for urgent referrals than junior ophthalmologists. Finally, RetinaVLM is able to reinforce its decisions by citing observable biomarkers within the written report, and highlighting their corresponding regions within the image.

We postulate that the poor performance of existing medical foundation models stems from their lack of detailed knowledge related retinal OCT and AMD. Current VLMs are trained on broad, unstructured datasets that are extracted from medical textbooks, scientific publications or social media posts of healthcare professional [9]. In the United Kingdom and the United States, clinical trainees aspiring to become specialists must undergo up to ten years of post-graduate training to obtain the grade of a board-certified consultant. We argue that training data of current foundation medical VLMs lacks this specialist knowledge and experience, hindering their effective application to real-world clinical tasks.

A core innovation of our work was the creation of a dedicated training curriculum that specializes VLMs in image-based clinical decision making. Analogously to current medical education, this curriculum deconstructs clinical problems into sets of mandatory capabilities required for their resolution and selectively trains VLMs in these skills. To this end, we obtained a large number of tabular reports by processing of retrospectively collected clinical data using advanced algorithms. Additionally, we tasked ophthalmologists to produce a limited number of highly specific textual reports. In total, our curriculum comprises 41,926 OCT images with 479,710 corresponding visual questions and answers. While still modest in size compared to substantially larger foundation datasets, we believe such curated needs-driven approaches are required to deploy language models specialist healthcare. In a similar vein, leading technology companies

in artificial intelligence have also started to look beyond the internet’s image and text data to source specialized training data to train LLMs and VLMs in disciplines such as computer programming, journalism, mathematics [24,25].

### **Limitations and future research directions**

Naturally, the quality of our curriculum depends on the underlying reports, in particular that of the 330 collected detailed textual reports. The majority of the reports used to create RetinaVLM-Specialist were written by a junior ophthalmologist with three years experience. The remaining reports were written by an ophthalmologist with ten years of experience, and their reports were more comprehensive. To match or surpass the performance of the average junior ophthalmologist, we seek to finetune this model further on a small number of reports written by intermediate and senior ophthalmologists.

Additionally, the data may reflect local clinical definitions and workflows. While RetinaVLM-Specialist was trained on reports written by the two UK-based ophthalmologists, it was tested on labels derived from four separate ophthalmologists from different countries and hospitals. In our testing we identified differences in the staging definitions used by the UK-based and Austria-based ophthalmologists, especially with regard to identifying fibrovascular features that differentiate intermediate from inactive late wet AMD. This discrepancy resulted in a number of the misclassifications by RetinaVLM.

Similarly, we observed a discrepancy in image interpretation between junior and senior ophthalmologists. Junior ophthalmologists did not recommend patients for referral if it was likely that the retinal fluid observed was caused by traction rather than neovascularization, as it is not treatable with antiangiogenic drugs. Conversely, the senior ophthalmologist preferred that these patients be still referred for immediate assessment to rule out neovascularization. RetinaVLM was explicitly instructed to refer patients with any sign of fluid of any cause (see Section 5.8.3), and correctly referred more patients as a result.

We found that the LLM generating the question-answer pairs from the reports was sensitive to the specifics of the generation instruction. Extensive trial and error were required to arrive at several instructions, listed in Section A.2, that resulted in diverse sets of high quality question-answer pairs. We discern that all aspects of dataset creation - deciding on the required capabilities, collecting specialized annotations and converting these to question-answer pairs - should be formalized to systematically compare different approaches and ultimately scale dataset curation in the future.

Beyond the formalization and extension of the creation of the curriculum, there are other potential technical improvements to RetinaVLM. Currently, RetinaVLM processes a single two-dimensional OCT image from one type of OCT scanner. In ophthalmological practice, decisions are made based on three-dimensional images from multiple time points, although many recent studies on the use of foundation models in ophthalmology also analyze two-dimensional images [18]. We mitigated the impact of this discrepancy on our study by tasking ophthalmologists to select the most relevant two-dimensional slice of the imaged volume before proceeding with the referral decision. In the future, a more sophisticated vision encoder, which is able to handle three-dimensional data from diverse OCT imaging devices, could be integrated with RetinaVLM. Similarly, one may opt to incorporate multimodal information, such as health questionnaires, clinical tests or the patient’s medical history, into the decision making process [26]. The fundamental model architecture and training would remain similar, but the level of reasoning required for differential diagnosis across multiple scans would potentially increase.

RetinaVLM also inherits some of the fundamental limitations of language models. LLMs are prone to confidently present false or fabricated information, termed hallucinations, which has been identified as problematic in medical contexts [13,14]. RetinaVLM occasionally hallucinates observations of retinal fluid and consequently diagnoses more advanced AMD stages than necessary. RetinaVLM’s output was also sensitive to the wording of questions and instructions. While this had little impact on our qualitative analysis, extensive trial and error was necessary to ensure that RetinaVLM responded with one of the provided options in the quantitative analyses.

In this study, we exclusively trained RetinaVLM for the management of AMD from OCT images, ignoring other retinal pathologies, such as diabetic retinopathy or glaucoma, or imaging modalities, such as color fundus photography [27,28]. While this enabled us to explore the potential to encode advanced clinical levels of specialism into VLMs at depth, it would limit the applicability of the current version of our models for ocular screening. We hypothesize that VLMs could be specialized on a wider range of ophthalmological tasks by incorporating additional VQA datasets and training VLMs on them. This requires costly and time-consuming curation of specialized training datasets by medical experts. However, we believe that the involvement of medical experts is necessary as routine clinical skills and patient management protocols are rarely documented in existing datasets used to train AI models.

## **Conclusion**

Foundation vision-language models (VLMs) have the potential to revolutionize healthcare by automatically interpreting medical images and communicating their findings in detailed written reports. Trained on large datasets containing millions of medical images and textual annotations, foundation language models have stirred considerable interest for their expert-level performance on medical licensing exams and case studies. However, in this work we have shown that foundation medical VLMs substantially underperform human experts on routine clinical tasks.

We hypothesize that the training data of foundation medical VLMs currently lacks specialist clinical knowledge and experience. To address this, we developed a curriculum-based approach that integrates the expertise of domain specialists into the training of medical VLMs. The resulting model, RetinaVLM, can produce detailed imaging reports that make accurate recommendations for the clinical management of AMD. It approaches and often matches the performance of junior ophthalmologists in disease staging, and outperforms non-specialist opticians in patient referral.

These results indicate that merely increasing the scale of training datasets is insufficient for the development of VLMs with real-world clinical utility. Instead, medical VLMs require high-quality data directly related to the challenges faced by clinicians in their daily practice. We believe our proposed curriculum-based approach provides a blueprint for specializing VLMs that generate true value in healthcare.

## References

1. Moy, A. J. *et al.* Measurement of clinical documentation burden among physicians and nurses using electronic health records: a scoping review. *Journal of the American Medical Informatics Association* **28**, 998–1008 (2021).
2. Acosta, J. N., Falcone, G. J., Rajpurkar, P. & Topol, E. J. Multimodal biomedical AI. *Nature Medicine* **28**, 1773–1784 (2022).
3. Moor, M. *et al.* Foundation models for generalist medical artificial intelligence. *Nature* **616**, 259–265 (2023).
4. Rajpurkar, P. & Lungren, M. P. The current and future state of ai interpretation of medical images. *New England Journal of Medicine* **388**, 1981–1990 (2023).
5. Zhang, Y., Jiang, H., Miura, Y., Manning, C. D. & Langlotz, C. P. Contrastive learning of medical visual representations from paired images and text. In *Machine Learning for Healthcare Conference*, 2–25 (PMLR, 2022).
6. Huang, Z., Bianchi, F., Yuksekogonul, M., Montine, T. J. & Zou, J. A visual–language foundation model for pathology image analysis using medical twitter. *Nature medicine* **29**, 2307–2316 (2023).
7. Lu, M. Y. *et al.* A visual-language foundation model for computational pathology. *Nature Medicine* **30**, 863–874 (2024).
8. Christensen, M., Vukadinovic, M., Yuan, N. & Ouyang, D. Vision–language foundation model for echocardiogram interpretation. *Nature Medicine* 1–8 (2024).
9. Li, C. *et al.* Llava-med: Training a large language-and-vision assistant for biomedicine in one day. *Advances in Neural Information Processing Systems* **36** (2024).
10. Moor, M. *et al.* Med-flamingo: a multimodal medical few-shot learner. In *Machine Learning for Health*, 353–367 (PMLR, 2023).
11. Tu, T. *et al.* Towards generalist biomedical AI. *NEJM AI* **1**, AIoa2300138 (2024).
12. Kung, T. H. *et al.* Performance of ChatGPT on USMLE: potential for AI-assisted medical education using large language models. *PLoS digital health* **2**, e0000198 (2023).
13. Singhal, K. *et al.* Large language models encode clinical knowledge. *Nature* **620**, 172–180 (2023).
14. Hager, P. *et al.* Evaluation and mitigation of the limitations of large language models in clinical decision-making. *Nature Medicine* (2024). URL <https://www.nature.com/articles/s41591-024-03097-1>.
15. Mitchell, P., Liew, G., Gopinath, B. & Wong, T. Y. Age-related macular degeneration. *The Lancet* **392**, 1147–1159 (2018).
16. Wong, W. L. *et al.* Global prevalence of age-related macular degeneration and disease burden projection for 2020 and 2040: a systematic review and meta-analysis. *The Lancet Global Health* **2**, e106–e116 (2014).
17. Holland, R. *et al.* Metadata-enhanced contrastive learning from retinal optical coherence tomography images. *arXiv preprint arXiv:2208.02529* (2022).
18. Zhou, Y. *et al.* A foundation model for generalizable disease detection from retinal images. *Nature* **622**, 156–163 (2023).
19. Meta AI. Introducing Meta Llama 3: The most capable openly available LLM to date (2024). URL <https://ai.meta.com/blog/meta-llama-3/>. Accessed: 2024-06-25.
20. Van Veen, D. *et al.* Adapted large language models can outperform medical experts in clinical text summarization. *Nature Medicine* 1–9 (2024).
21. Fragiotta, S. *et al.* Significance of hyperreflective foci as an optical coherence tomography biomarker in retinal diseases: characterization and clinical implications. *Journal of ophthalmology* **2021**, 6096017 (2021).
22. Selvaraju, R. R. *et al.* Grad-cam: Visual explanations from deep networks via gradient-based localization. In *Proceedings of the IEEE international conference on computer vision*, 618–626 (2017).
23. De Fauw, J. *et al.* Clinically applicable deep learning for diagnosis and referral in retinal disease. *Nature medicine* **24**, 1342–1350 (2018).
24. Sambasivan, N. *et al.* “Everyone wants to do the model work, not the data work”: Data cascades in high-stakes AI. *SIGCHI, ACM* (2021). URL <https://research.google/pubs/everyone-wants-to-do-the-model-work-not-the-data-work-data-cascades-in-high-stakes-ai/>.
25. Heikkilä, M. OpenAI’s hunger for data is coming back to bite it. *MIT Technology Review* (2023). URL <https://www.technologyreview.com/2023/04/19/1071789/openais-hunger-for-data-is-coming-back-to-bite-it/>.
26. Baltrušaitis, T., Ahuja, C. & Morency, L.-P. Multimodal machine learning: A survey and taxonomy. *IEEE transactions on pattern analysis and machine intelligence* **41**, 423–443 (2018).
27. Flaxman, S. R. *et al.* Global causes of blindness and distance vision impairment 1990–2020: a systematic review and meta-analysis. *The Lancet Global Health* **5**, e1221–e1234 (2017).
28. Abramoff, M. D., Garvin, M. K. & Sonka, M. Retinal imaging and image analysis. *IEEE reviews in biomedical engineering* **3**, 169–208 (2010).
29. Grill, J.-B. *et al.* Bootstrap your own latent—a new approach to self-supervised learning. *Advances in neural information processing systems* **33**, 21271–21284 (2020).



30. AI@Meta. Llama 3 model card (2024). URL [https://github.com/meta-llama/llama3/blob/main/MODEL\\_CARD.md](https://github.com/meta-llama/llama3/blob/main/MODEL_CARD.md).
31. Zhu, D., Chen, J., Shen, X., Li, X. & Elhoseiny, M. MiniGPT-4: Enhancing vision-language understanding with advanced large language models. *arXiv preprint arXiv:2304.10592* (2023).
32. Chen, Z. *et al.* Chexagent: Towards a foundation model for chest x-ray interpretation. *arXiv preprint arXiv:2401.12208* (2024).
33. Alayrac, J.-B. *et al.* Flamingo: a visual language model for few-shot learning. *Advances in neural information processing systems* **35**, 23716–23736 (2022).
34. Lin, W. *et al.* PMC-CLIP: Contrastive language-image pre-training using biomedical documents. In *International Conference on Medical Image Computing and Computer-Assisted Intervention*, 525–536 (Springer, 2023).
35. Liu, H., Li, C., Wu, Q. & Lee, Y. J. Visual instruction tuning. *Advances in neural information processing systems* **36** (2024).
36. Zhang, S. *et al.* Large-scale domain-specific pretraining for biomedical vision-language processing. *arXiv preprint arXiv:2303.00915* (2023).
37. Holland, R. *et al.* Deep-learning-based clustering of OCT images for biomarker discovery in age-related macular degeneration (PINNACLE study report 4). *Ophthalmology Science* 100543 (2024).
38. Kirkpatrick, J. *et al.* Overcoming catastrophic forgetting in neural networks. *Proceedings of the national academy of sciences* **114**, 3521–3526 (2017).
39. McNemar, Q. Note on the sampling error of the difference between correlated proportions or percentages. *Psychometrika* **12**, 153–157 (1947).
40. Paszke, A. *et al.* Automatic differentiation in pytorch (2017).
41. Sutton, J. *et al.* Developing and validating a multivariable prediction model which predicts progression of intermediate to late age-related macular degeneration—the PINNACLE trial protocol. *Eye* **37**, 1275–1283 (2023).

## 4 Extended figures

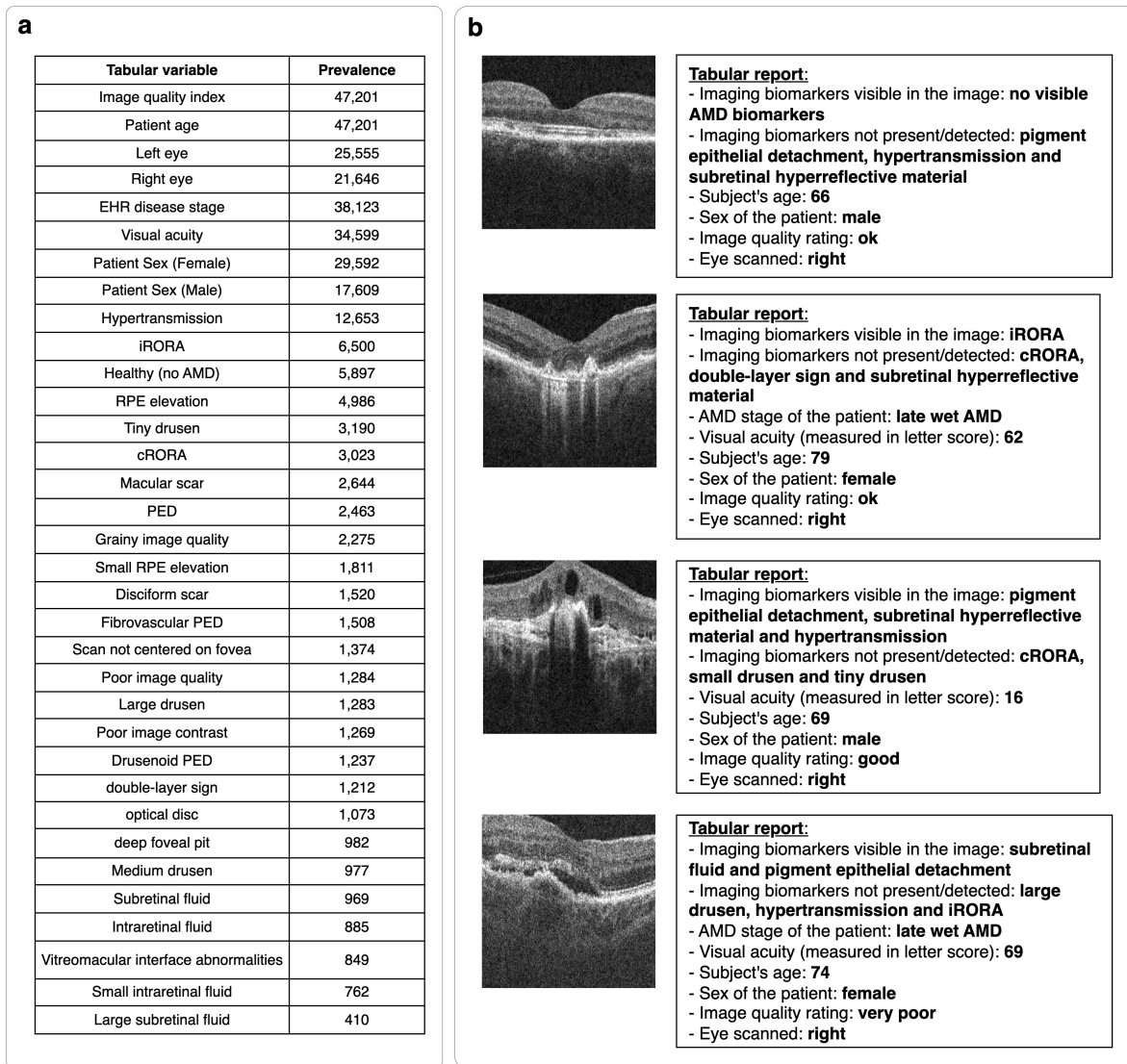


Fig. 7: (a) The prevalence of each automatically collected tabular variable among the images in the dataset. (b) Four randomly selected images and their corresponding tabular reports.

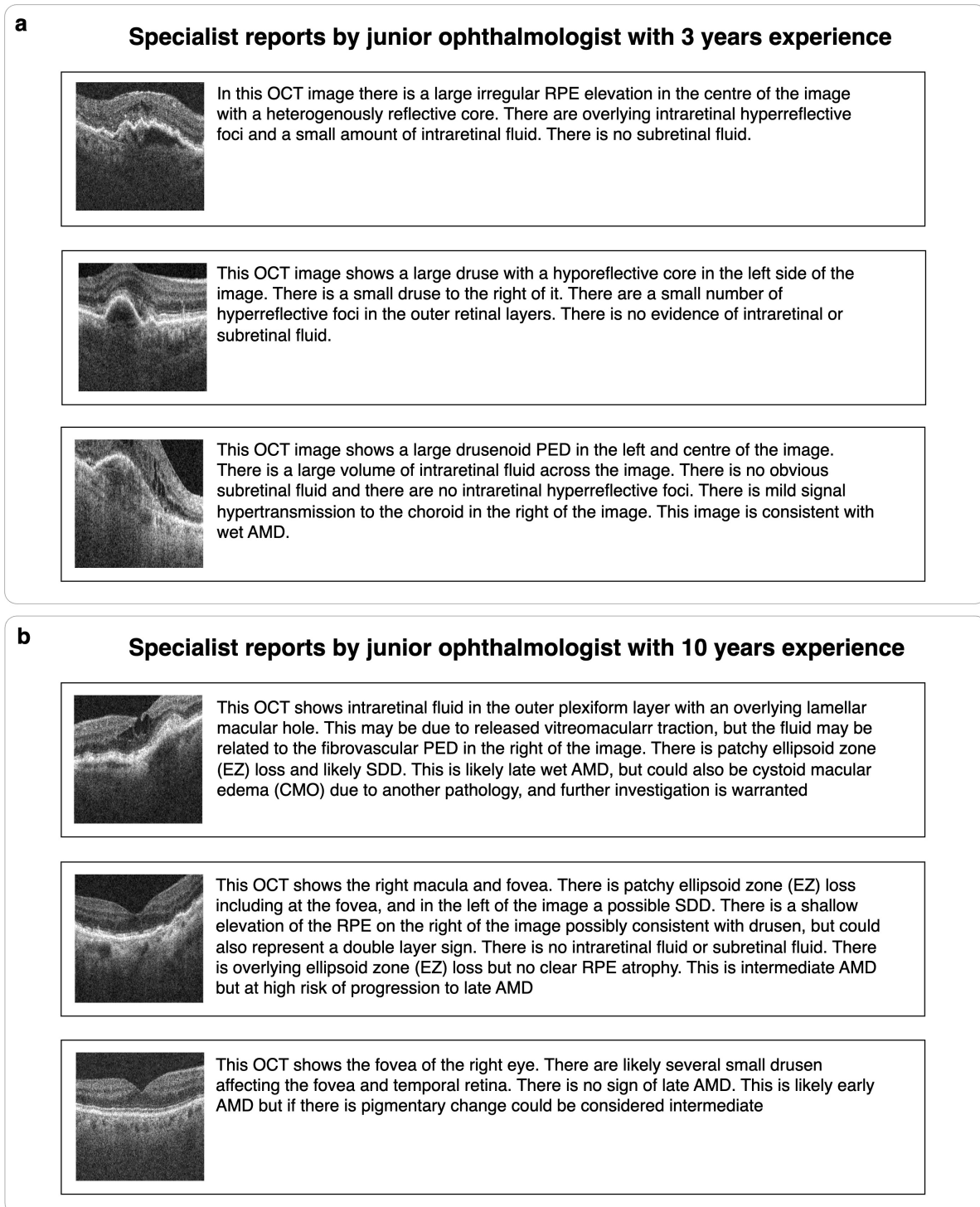


Fig. 8: **(a)** Three example reports randomly selected from the 244 written by the first junior ophthalmologist with 3 years experience in ophthalmology. **(b)** Three example reports randomly selected from the 86 written by the more experienced junior ophthalmologist with 10 years experience.

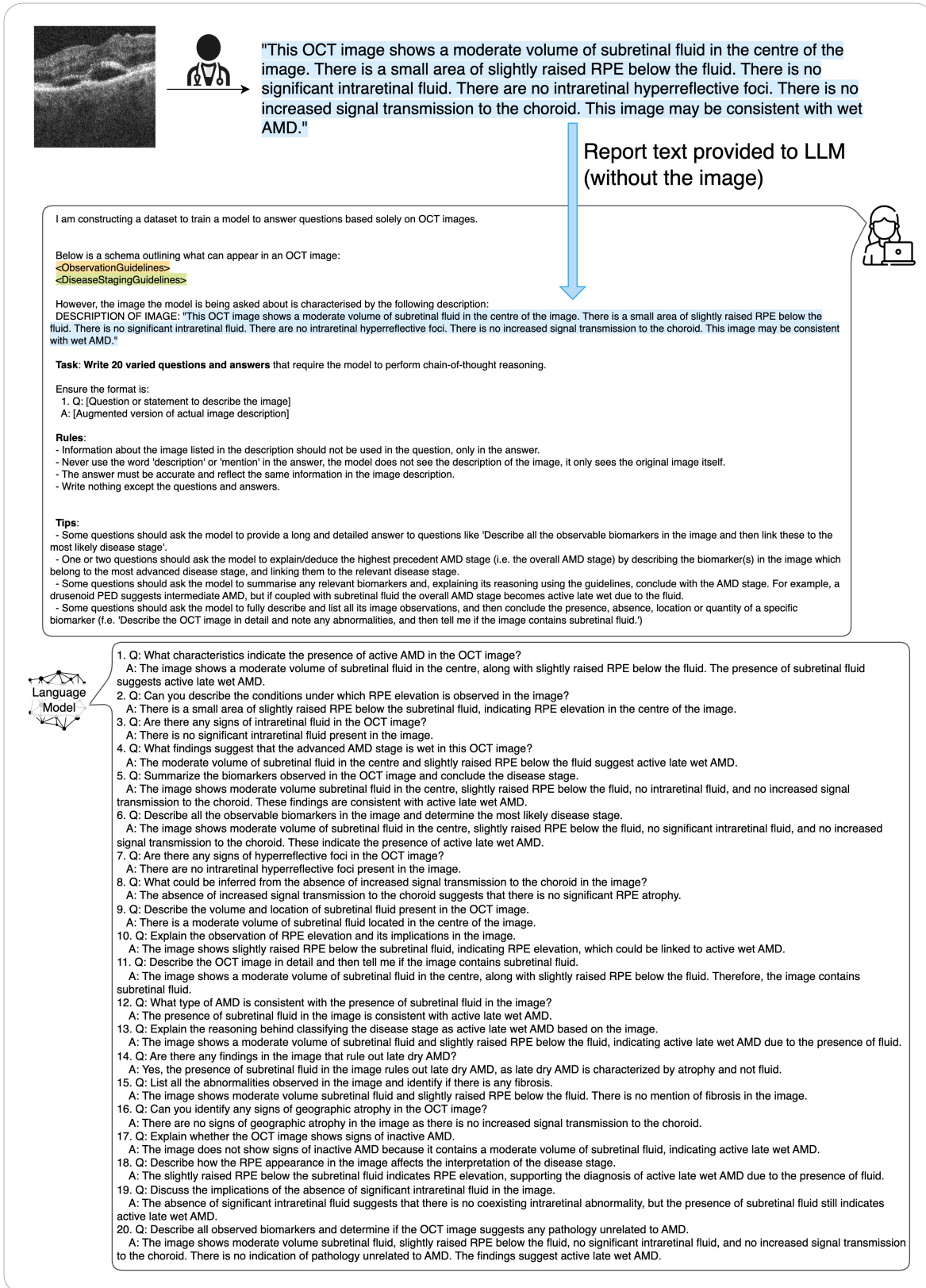




Fig. 9: Example interaction with the LLM used to generate the question-answer pairs. Given the report text, the LLM is instructed to generate a set number of question-answer pairs in a specific format, according to pre-determined rules, and the guidelines derived by ophthalmologists. References to guidelines are replaced with the corresponding guideline text, documented in Figure 16.

**a**



**Tabular report**

- Imaging biomarkers visible in the image: pigment epithelial detachment
- Imaging biomarkers not present/detected: hypertransmission, subretinal hyperreflective material and IRORA
- AMD stage of the patient: late wet AMD
- Subject's age: 87
- Sex of the patient: female
- Image quality rating: very poor
- Eye scanned: left




**Specialist report**

This OCT shows a tall, complex, heterogeneously reflective PED at the fovea, with a likely hyporeflexive ring in the PED in the centre of the image, but no double layer sign. The PED is potentially fibrovascular. There is pachychoroid, and hyperreflective foci (HRF) but no subretinal fluid or intraretinal fluid. This is likely intermediate AMD, and likely shows polypoidal choroidal vasculopathy, and may benefit from further investigation and treatment. If the PED is fibrovascular, this is inactive late wet AMD.


Curriculum	Module	#	Question-answer pair examples	
Part 1 Introduction to retina (based off tabular report)	General QA	1	Q: What is the imaging biomarker visible in the image? A: The imaging biomarker visible in the image is pigment epithelial detachment.	
		2	Q: Can you identify any subretinal hyperreflective material in the image? A: No, there is no subretinal hyperreflective material present in the image.	
	Advanced biomarkers	1	Q: What type of pigment epithelial detachment (PED) is present, if any? A: The PED is potentially fibrovascular.	
		2	Q: Does the image exhibit any RPE elevation? A: Yes, the image implies RPE elevation due to the presence of PED.	
	Staging definitions	1	Q: Does the image show any pathology unrelated to AMD? A: The image does not show any pathology unrelated to AMD.	
		2	Q: What can be inferred about the AMD stage from the image? A: The image likely shows intermediate AMD, or if the PED is fibrovascular, inactive late wet AMD.	
	Staging reasoning	1	Q: Describe the OCT image in detail and identify any indications of hypertransmission. A: The OCT image shows a tall, complex PED, hyperreflective foci, and pachychoroid but no signs of hypertransmission, which indicates no significant RPE atrophy in this specific image.	
		2	Q: Describe the most advanced AMD stage detected in the image and the reasoning behind this diagnosis. A: The most advanced AMD stage detected is inactive late wet AMD. This is due to the presence of a fibrovascular PED and no subretinal or intraretinal fluid.	
	Part 2 Advanced retinal specialism (based off specialist report)	Referral reasoning	1	Q: Based on the OCT image, does the patient need urgent treatment or general attention by a retinal specialist? A: The patient has a tall, complex PED with HRF and no retinal fluid, suggesting intermediate AMD or inactive late wet AMD. The patient should be referred for general attention by a retinal specialist rather than urgent treatment.
			2	Q: Evaluate whether the patient requires urgent intervention based on the biomarkers in the OCT image. A: The patient does not require urgent intervention as there is no subretinal or intraretinal fluid. The presence of a tall, complex PED and HRF suggests intermediate AMD or inactive late wet AMD. Referral to a retinal specialist for further evaluation is appropriate.
General QA		1	Q: What condition does the image likely indicate? A: The image likely suggests intermediate AMD and polypoidal choroidal vasculopathy, with possible fibrovascular PED indicating inactive late wet AMD.	
		2	Q: What does the hyporeflexive ring in the PED suggest? A: The likely hyporeflexive ring within the PED, located centrally in the image, is part of the complex and heterogeneously reflective nature of the PED observed at the fovea.	
Report writing		1	Q: Describe the foveal region of the image. A: At the fovea, there is a tall, complex, heterogeneously reflective PED with a likely hyporeflexive ring in the centre of the PED. There are hyperreflective foci (HRF), but no subretinal or intraretinal fluid. The PED is potentially fibrovascular, and there is no double layer sign. This finding suggests likely intermediate AMD and polypoidal choroidal vasculopathy.	
		2	Q: Write a verbose report detailing the biomarkers, disease stage, and referral recommendation. A: The OCT image demonstrates several significant biomarkers, including a tall, complex, heterogeneously reflective PED at the fovea with a hyporeflexive ring and the presence of hyperreflective foci (HRF). These findings indicate the presence of a fibrovascular PED, suggesting inactive late wet AMD. There is no evidence of subretinal fluid or intraretinal fluid, which supports the conclusion that the neovascularization is inactive. Given these findings, referral to a retinal specialist for further evaluation and potential monitoring is recommended.	

**b**



**Tabular report**

- Imaging biomarkers visible in the image: cRORA, deep foveal pit and hypertransmission
- Imaging biomarkers not present/detected: RPE elevation, subretinal hyperreflective material and disorganized PED
- AMD stage of the patient: late wet AMD
- Subject's age: 87
- Sex of the patient: female
- Image quality rating: good
- Eye scanned: left



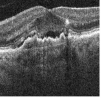
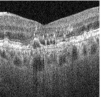
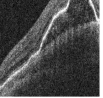
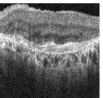
**Specialist report**

It is unclear which eye is imaged, or whether the fovea is included, but it is likely centred on the macula. There is a large area of cRORA in the centre of the image, with an island of migrating pigment or relatively preserved RPE and retina. Adjacent to the island is a small round hyporeflexive area consistent with sub-retina fluid, but this is more likely related to atrophy than disease activity. On the left of the image there is elevation of the retina. This may represent subretinal hyperreflective material, or a fibrovascular PED. This is most likely consistent with active wet AMD but the centre involving atrophy leaves a very poor visual prognosis

Curriculum	Module	#	Question-answer pair examples
Part 1 Introduction to retina (based off tabular report)	General QA	1	Q: Is there any indication of cRORA in the image? A: Yes, cRORA is visible in the image.
		2	Q: What is the stage of AMD in the patient? A: The patient has late wet AMD.
Part 2 Advanced retinal specialism (based off specialist report)	Advanced biomarkers	1	Q: Is any RPE elevation present in the image? A: The image shows RPE elevation on the left side, possibly due to subretinal hyperreflective material or a fibrovascular PED.
		2	Q: Is there any subretinal fluid visible in the image? A: Yes, a small round hyporeflexive area consistent with subretinal fluid is visible adjacent to the island of relatively preserved RPE and retina.
	Staging definitions	1	Q: Determine the AMD stage and the significant biomarkers visible in the image. A: A: The AMD stage is late wet (active) due to subretinal fluid. Additionally, cRORA and fibrovascular PED support this stage.
		2	Q: Summarize the relevant biomarkers in the OCT image and conclude the AMD stage. A: Observations include a central area of cRORA, small round subretinal fluid suggesting atrophy, and retinal elevation on the left indicating SHRM or fibrovascular PED. This combination supports a diagnosis of active late wet AMD.
	Staging reasoning	1	Q: Explain the reasoning to determine the highest AMD stage in the OCT image based on biomarkers. A: The central cRORA indicates late dry AMD, but the presence of subretinal fluid and possible SHRM or fibrovascular PED on the left signifies active late wet AMD, the highest stage.
		2	Q: What biomarkers are present in the image and what disease stage do they suggest? A: Present biomarkers include subretinal fluid, cRORA, and fibrovascular PED. They suggest late wet (active) AMD.
	Referral reasoning	1	Q: Identify the most concerning biomarker in the OCT image and explain its implications for referral based on AMD guidelines. A: The most concerning biomarker in the OCT image is the retinal elevation on the left, likely representing subretinal hyperreflective material or a fibrovascular PED, indicating active wet AMD. Additionally, a large area of cRORA in the center suggests late dry AMD. Given these findings, the patient is in the active late wet AMD stage. The patient should be urgently referred for anti-VEGF treatment.
		2	Q: What are the signs of active and inactive AMD in the OCT image, and what is the recommended referral action? A: The OCT image features a large area of cRORA in the center, indicating late dry AMD. Additionally, there is sub-retina fluid likely related to atrophy. The retinal elevation on the left, likely representing subretinal hyperreflective material or a fibrovascular PED, suggests active wet AMD. The most concerning finding is the indication of active late wet AMD. The patient should be urgently referred for anti-VEGF treatment.
	General QA	1	Q: Is there any indication of atrophy in this OCT image? A: Yes, there is a large area of cRORA in the center, and the sub-retina fluid adjacent to the island is more likely related to atrophy than disease activity.
		2	Q: What is the likely cause of the small round hyporeflexive area? A: The small round hyporeflexive area is likely sub-retina fluid, more related to atrophy than disease activity.
Report writing		1	Q: Can you give me a summary of the image? A: The image shows a large area of cRORA in the center with an island of migrating pigment or relatively preserved RPE and retina. There is a small round hyporeflexive area adjacent to the island, likely sub-retina fluid more related to atrophy than disease activity. On the left, elevated retina may indicate subretinal hyperreflective material, or a fibrovascular PED, suggesting active, wet AMD. The atrophy involving the center indicates a very poor visual prognosis. It is unclear which eye is imaged or if the fovea is included, but it's likely centered on the macula.
		2	Q: Describe the retinal elevation seen in the image. A: The retina on the left side of the image shows elevation, which may represent subretinal hyperreflective material or a fibrovascular PED, indicating active, wet AMD.

Fig. 10: (a) Example question-answer pairs generated for curriculum part 1 (based on the tabular report), and for the six modules that constitute part 2 (based on the specialist report). (b) Example question-answer pairs for a second example image, derived from different tabular and specialist reports.



<p><b>a</b></p> <p>Describe the OCT image in detail and list any biomarkers or abnormalities, including the most likely AMD stage of the patient. Then, based on those observations, state if the patient's most advanced AMD stage is 'healthy', 'early', 'intermediate', 'late dry', 'late wet (inactive)' or 'late wet (active)'?</p>		<p><b>Ophthalmologist ground truth</b></p> <p>Junior opht. prediction    Senior opht. ground truth</p>	
	<p>The OCT image shows a central area of subretinal fluid and a double-layer sign. There are some intraretinal hyperreflective foci above the fluid. There is no intraretinal fluid and no hypertransmission to the choroid. These features suggest the patient has active late wet AMD. Based off the image and those findings, the patient's most likely AMD stage is <b>late wet (active)</b>.</p>	<p><b>Active late wet</b></p>	<p><b>Active late wet</b></p>
	<p>The OCT image shows a large area of RPE thinning and subretinal fluid at the fovea, with multiple intraretinal hyperreflective foci. These findings are consistent with late wet AMD. Based off the image and those findings, the patient's most likely AMD stage is <b>late wet (active)</b>.</p>	<p><b>Active late wet</b></p>	<p><b>Active late wet</b></p>
	<p>The OCT image shows a large drusenoid PED with a moderate amount of RPE thickening and hyperreflective foci in the outer retina. These findings are consistent with intermediate AMD. Based off the image and those findings, the patient's most likely AMD stage is <b>intermediate</b>.</p>	<p><b>Intermediate</b></p>	<p><b>Inactive late wet</b></p>
	<p>The OCT image shows a large area of subretinal hyperreflective material, which is indicative of scarring. Additionally, there is RPE atrophy with corresponding hypertransmission to the choroid. The presence of an intraretinal fluid indication of active neovascularisation is also observed. These biomarkers suggest the patient has active late wet AMD, likely treated. Based off the image and those findings, the patient's most likely AMD stage is <b>late wet (active)</b>.</p>	<p><b>Inactive late wet</b></p>	<p><b>Inactive late wet</b></p>

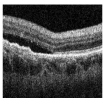
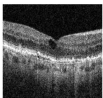
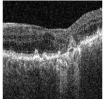
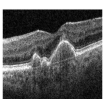
<p><b>b</b></p> <p>Write an extensive report describing the OCT image and listing any present biomarkers or other observations. Do not provide a disease stage, or referral recommendation yet. Being seen by a specialist at the Southampton clinic: A. The Southampton clinic requires that patients with any sign of intraretinal fluid, any sign of subretinal fluid, or any sign of cyst(s), MUST be seen by a specialist at the...</p>		<p><b>Ophthalmologist ground truth</b></p> <p>Junior opht. prediction    Senior opht. ground truth</p>	
	<p>The OCT image shows a few small areas of subretinal fluid in the central macula. There are also some intraretinal hyperreflective foci present. The retinal pigment epithelium (RPE) and the outer nuclear layer appear normal. The retinal layers are otherwise unremarkable, with no signs of atrophy or thinning. My report indicates that the patient should be seen by a specialist at the Southampton clinic within the next two weeks.</p>	<p><b>Urgent referral (2 weeks)</b></p>	<p><b>Urgent referral (2 weeks)</b></p>
	<p>The OCT image shows the right macula with the fovea located centrally. The macula exhibits a large area of intraretinal fluid in the inner retinal layers, accompanied by intraretinal hyperreflective foci. The RPE is thickened, and there is mild retinal atrophy. The fovea shows a shallow irregularity in the outer retinal layers. My report indicates that the patient should be seen by a specialist at the Southampton clinic within the next two weeks.</p>	<p><b>Routine referral (18 weeks)</b></p>	<p><b>Urgent referral (2 weeks)</b></p>
	<p>The OCT image shows a shallow irregular RPE elevation in the central macula, consistent with intermediate AMD. There is also a small central area of subretinal hyperreflective material (SRH) and intraretinal hyperreflective foci (IRH). The outer retinal layers appear thinned, and the choroid is visible. My report indicates that the patient should be seen by a specialist at the Southampton clinic within the next two weeks.</p>	<p><b>Routine referral (18 weeks)</b></p>	<p><b>Routine referral (18 weeks)</b></p>
	<p>The OCT image shows the fovea and both maculae. There are several areas of increased signal intensity in the outer retinal layers, which are likely indicative of intraretinal hyperreflective foci. Additionally, there are several areas of mild hyperreflectivity in the outer retinal layers. My report indicates that the patient should be seen by a specialist at the Southampton clinic within the next two weeks.</p>	<p><b>Routine referral (18 weeks)</b></p>	<p><b>Routine referral (18 weeks)</b></p>

Fig. 11: (a) Four example reports by RetinaVLM-Specialist that result in two correct and two incorrect disease stage conclusions. Images showing inactive late wet AMD sometimes had fewer abnormalities and were misclassified as intermediate AMD (third sample). Another mode of failure was the hallucination of retinal fluid, which unnecessarily upgraded the disease classification to active late wet AMD (fourth sample). (b) Four example reports that result in two correct and two incorrect patient referral recommendations. In each failure case RetinaVLM-Specialist correctly identifies the lack of fluid, but fails to follow the referral protocol and makes the wrong referral recommendation, which was the most common mode of failure for this task.



**a**

	Disease staging F1			Urgent patient referral F1		
	F1 score (95% CI)	Statistic	P-value	F1 score (95% CI)	Statistic	P-value
<b>Med-Flamingo</b>	0.11(0.08, 0.16)	--	--	0.0(0.0, 0.0)	--	--
<b>LLaVA-Med</b>	0.07(0.04, 0.10)	4.1	$4.3 \cdot 10^{-2}$	0.39(0.23, 0.53)	0.0	$7.4 \cdot 10^0$
<b>RetinaVLM-Base</b>	0.30(0.24, 0.35)	49.0	$2.6 \cdot 10^{-12}$	0.26(0.10, 0.43)	3.2	$7.4 \cdot 10^{-2}$
<b>RetinaVLM-Specialist</b>	0.63(0.58, 0.69)	73.5	$1.0 \cdot 10^{-17}$	0.67(0.52, 0.79)	3.84	$5.0 \cdot 10^{-2}$
<b>Junior ophthalmologists</b>	0.77(0.72, 0.82)	114.9	$8.1 \cdot 10^{-27}$	0.78(0.64, 0.89)	39.9	$2.6 \cdot 10^{-10}$

**b**

	Subretinal fluid	Intraretinal fluid	Hyper-transmission	PED	SHRM	Drusen	Hyper-reflective foci	Double-layer sign	RPE Elevation	RPE Atrophy
<b>Med-Flamingo</b>	0.0	0.0	0.0	8.0	0.0	0.0	0.0	0.0	0.0	0.0
<b>LLaVA-Med</b>	0.19	0.34	0.49	0.43	0.29	0.43	0.45	0.65	0.66	0.56
<b>RetinaVLM-Base</b>	0.26	0.29	0.56	0.34	0.40	0.57	0.32	0.39	0.37	0.25
<b>RetinaVLM-Specialist</b>	0.55	0.40	0.71	0.52	0.56	0.53	0.29	0.55	0.55	0.68

Fig. 12: (a) Full results tables for the disease staging and patient referral tasks. (b) Full results table for the detection of ten different biomarkers indicative of AMD.

		Med-Flamingo						
		Healthy	Early	Intermediate	Late dry	Inactive late wet	Active late wet	
Healthy	28	0	0	0	0	0	0	8
Early	12	0	0	0	0	0	0	6
Intermediate	45	0	0	0	0	0	0	19
Late dry	14	0	0	0	0	0	0	11
Inactive late wet	60	0	0	0	0	0	0	15
Active late wet	45	0	0	0	0	0	0	13
		Disease stage prediction						Invalid response

Fig. 13: Confusion matrix for Med-Flamingo, included here for space reasons. Med-Flamingo always predicted that the patient was healthy irrespective of the true disease state of the image or returned an invalid report.

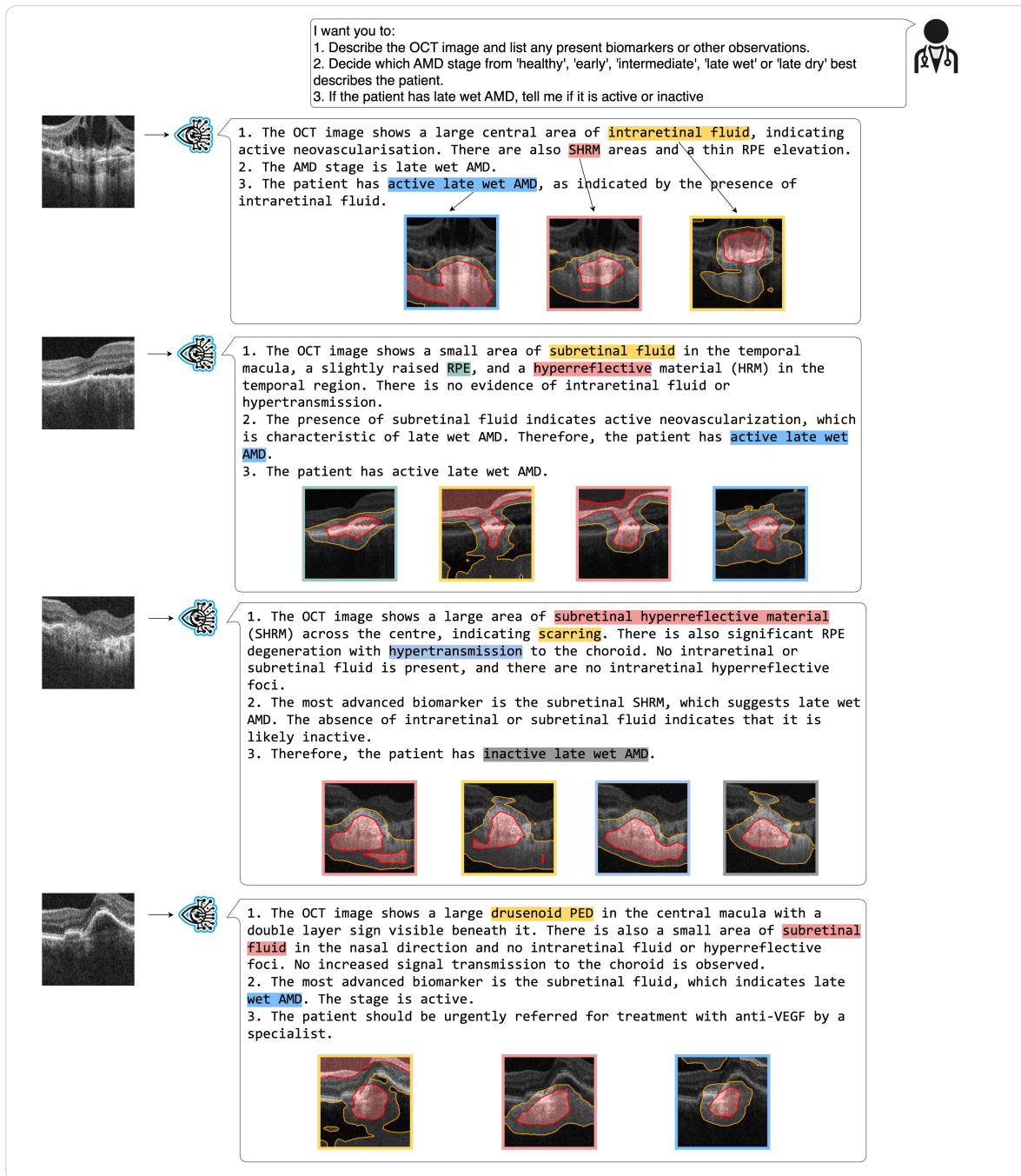


Fig. 14: Additional examples of saliency maps computed with RetinaVLM-Specialist. Each saliency map is generated for specific phrases of the report, where color indicates correspondence. Saliency maps related to fluid often contain the fluid boundary. Saliency maps sometimes include unrelated regions, such as for subretinal fluid in the second sample, and the PED in the fourth sample. Moreover, in the last sample the model misidentifies the presence of subretinal fluid and the saliency map is centered on hypertransmission. Overall, the saliency maps assist in highlighting more severe biomarkers, and in interpreting the working of the model.

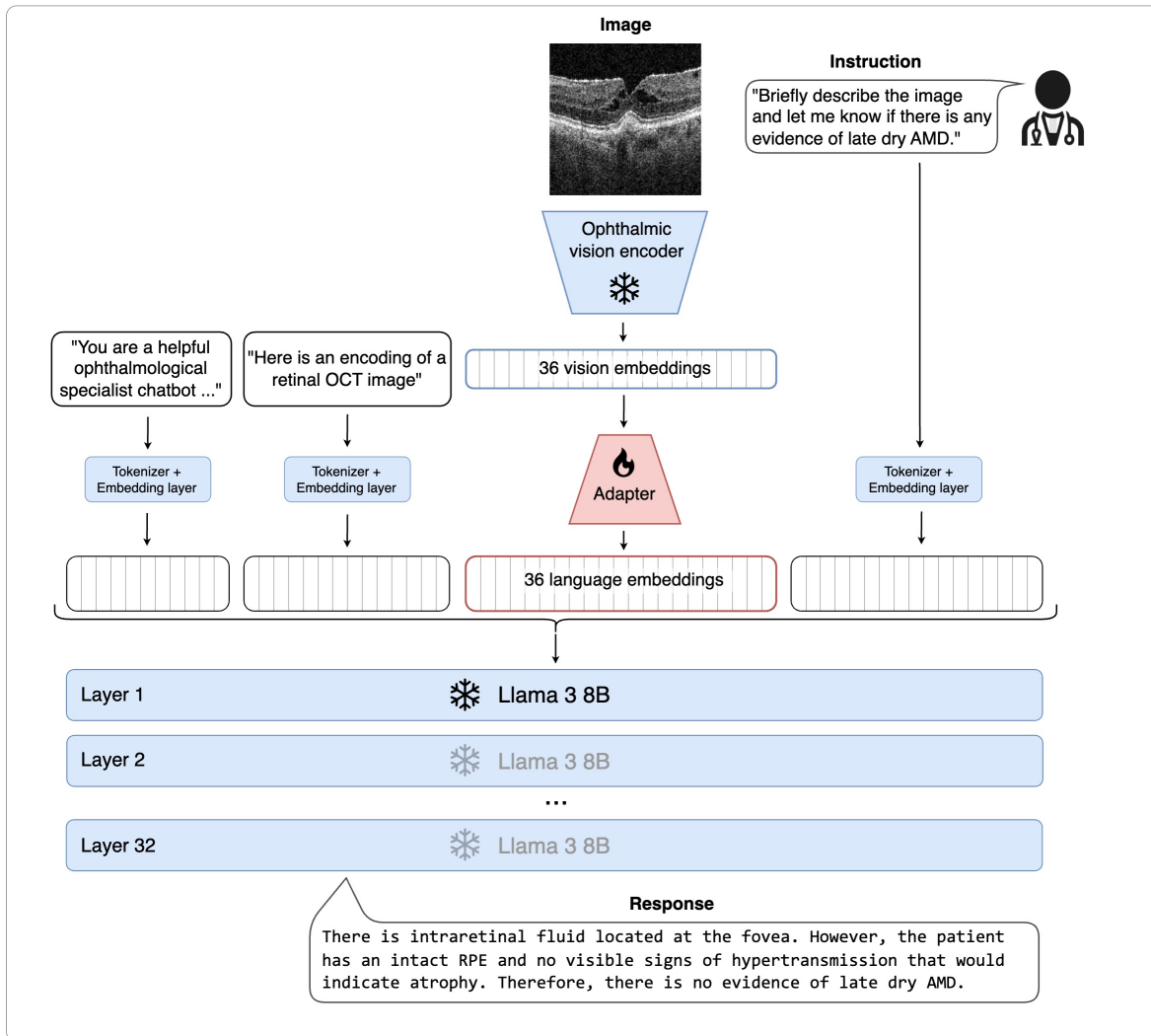


Fig. 15: RetinaVLM consists of an ophthalmic vision encoder, a LLM and an image-to-language adapter. The vision encoder and LLM are not updated during training. Textual instructions are projected to the embedding space of the LLM using the pre-existing tokenizer and embedding layer, while the vision embeddings are projected via the learnable adapter. During training, the adapter is optimized such the the LLM gives the corresponding response to the given instruction.

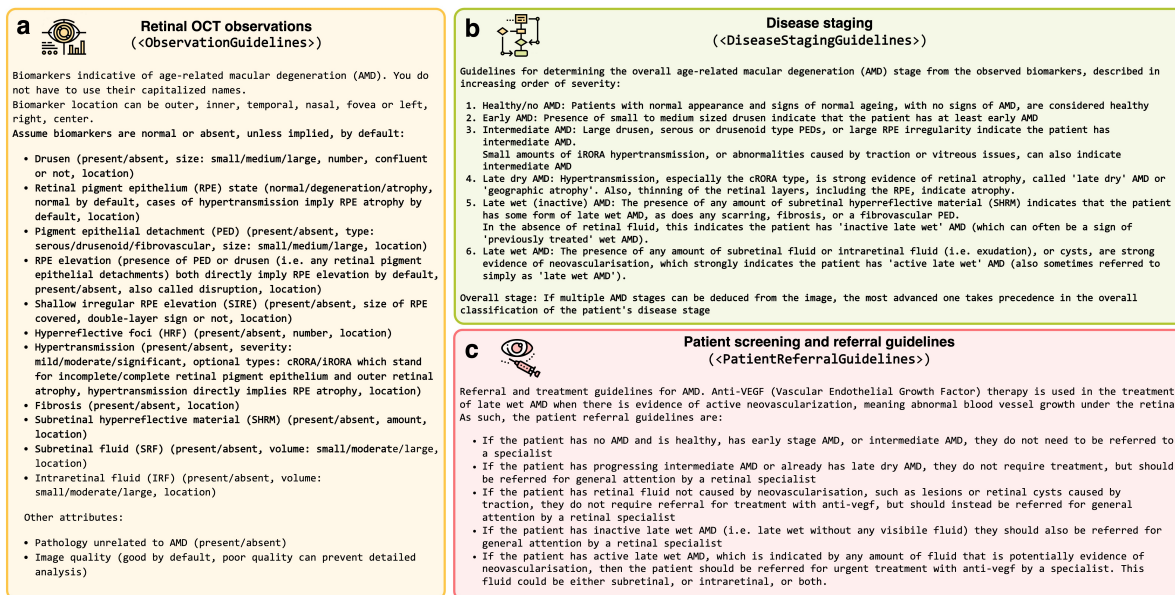


Fig. 16: Three guidelines defined by junior and senior ophthalmologists for the assessment and referral of AMD from retinal OCT. These guidelines are used to guide the LLM generating question-answer pairs that train VLMs in the mandatory capabilities of image-based clinical decision makers for AMD. (a) Biomarkers observable in retinal OCT that are relevant to AMD. (b) Linking observable biomarkers to deduce progressively severe disease stages. (c) Protocol for patient referral for treatment with antiangiogenic drugs and routine referral, based on the observations and disease stage.

## 5 Methods

### 5.1 Retinal image dataset curation

We use two retinal OCT dataset in this study. The first, described in Section 5.1.1, contains a cohort of patients with AMD collected retrospectively at the Southampton Eye Unit. The second dataset, described in Section 5.1.2, contains scans of the initial visits of patients referred, primarily by opticians, to the Southampton Eye Unit.

All data was collected in the scope of the PINNACLE study (ClinicalTrials.gov NCT04269304), which received approval from the East Midlands–Leicester Central Research Ethics Committee in the United Kingdom (ref. 19/EM/0163) and the institutional review boards of all participating institutions. It complies with the principles of Good Clinical Practice and the Declaration of Helsinki. All images were captured using Topcon 3D OCT scanners (Topcon Corporation, Tokyo, Japan). Both datasets contain images of size  $416 \times 512$  with a pixel size of  $3.5 \times 11.7 \mu\text{m}^2$ .

#### 5.1.1 Retrospective cohort for training RetinaVLM and testing disease staging, report writing and biomarker analysis

The retrospective dataset contains 45,379 OCT images from 6,152 eyes belonging to 3,468 patients, collected over eight years, between 2012 and 2020, at the Southampton Eye Unit and aggregated by the PINNACLE consortium. For each OCT scan we use the mediolateral 2D slice centered at the fovea.

We designated 41,926 of the 45,379 OCT images from 5,547 eyes of 3,057 patients for training purposes. Additionally, we reserved 2,311 images from 326 eyes of 187 patients for validation, and 396 images from 279 eyes of 224 patients for testing. We ensured that images from each patient do not appear in more than one of the training, validation or test sets.

The training set was used to create both curriculum parts 1 and 2, detailed in Sections 5.4.1 and 5.4.2. The test set was used to evaluate the resulting model in Sections 2.3 and 2.5. For each patient in the test set, two junior ophthalmologists independently decided the disease stage, and disagreements were arbitrated by the two senior ophthalmologists. Inactive late wet AMD was defined by the presence of any subretinal hyperreflective material or fibrosis. Active late wet AMD was defined by presence of any fluid within the image and took precedence over the inactive classification.

#### 5.1.2 External cohort of patients referred to Southampton AMD treatment clinic

We also collected an external dataset of 95 patients that were referred primarily by opticians to the Southampton Eye Unit between 02/2023 and 12/2023. None had yet received treatment for AMD, and mostly had no AMD, intermediate AMD or small features related to active wet AMD. This represents a distribution shift from the retrospective cohort, where many patients had already received treatment for AMD and were in the inactive late wet stage of AMD. As such, it enabled us to estimate the robustness of both variants of RetinaVLM to shifts in patient population. This dataset was not used for model training and was reserved for testing VLMs on patient referral, detailed in Section 2.4.

For each patient we sourced scans of both their left and right eye that were acquired on their first visit to the clinic. We also collected the originally issued letter of referral, as depicted in Figure 5d. Then, two junior ophthalmologists analyzed the 3D OCT volumes of each eye to assess the patient’s risk and recommend a level of referral urgency. They then selected the image slice that most supported their assessment of the patient’s risk. In healthy patients where both volumes contained no pathological signs in any of the image slices, they were instructed to select the mediolateral fovea-centered 2D slice from one of the two volumes.

### 5.2 Vision-language model architecture

RetinaVLM consists of two main components: an ophthalmological vision encoder and a generative LLM (see Figure 15). For the ophthalmological vision encoder, we adopt a Resnet50 convolutional neural network with over 23 million parameters which was previously pre-trained with self-supervised contrastive learning on the 41,926 OCT images from the train set of the retrospective cohort. Specifically, it was trained with Bootstrap Your Own Latent (BYOL) [29] using the same implementation details as the standard contrastive approaches used in [17], which consistently performed on par with RETFound [18] specifically on data from the Southampton Eye Unit. This vision encoder projects each  $192 \times 192$  input image to a set of spatially arranged  $6 \times 6$  visual embeddings, which are extracted from the last layer before global average pooling. Each embedding has a dimension of  $h_{img} = 2048$ . They also have a receptive field of size 336, so each embedding contains global knowledge of the image that is contextualized at its local position. For the LLM, we employ the 8 billion parameter instruction-tuned Llama3 model by Meta [19,30] as the generative LLM, which was the most performant openly available model at the time of our study. Llama3 uses an embedding dimension of  $h_{lang} = 4096$ .



The ophthalmological vision encoder provides visual information regarding the OCT image to the LLM via an adapter. The adapter is a linear layer of size  $h_{img} \times h_{lang}$  that processes visual information for use by the LLM. This follows the design used in MiniGPT4 [31], and results in an adapter with over 8 million parameters.

### 5.3 Foundation medical vision-language models

We used the two most widely adopted foundation vision-language models for medical applications at the time of this study [10,9]. They were both trained on large biomedical datasets sourced from the Internet, and have been applied in chest x-ray [32]. The first, Med-Flamingo [10], which was built on Flamingo [33] and finetuned on image and text data from medical textbooks and the PubMed Central Open Access (PMC-OA) dataset [34]. The second, LLaVA-Med [9], developed by Microsoft, is a VLM built on LLaVA [35] and finetuned to follow textual instructions regarding a broad range of biomedical images contained in PubMed Central 15M (PMC-15M) [36]. As they were trained as generalist models on various imaging modalities, they were both purportedly capable of interpreting retinal OCT images. Both correctly identified that the provided image was a retinal OCT scan when instructed to report the modality of the given image.

For Med-Flamingo, we then provide instructions using the following template provided in their code, replacing {question} with the instruction text:

```
You are a helpful medical assistant. You are being provided with images, a question about the image and an answer. Follow the examples and answer the last question. <image>Question: {question} Answer:
```

Similarly, for LLaVA-Med we use their following system prompt:

```
You are a helpful medical assistant. You are being provided with images, a question about the image and an answer. Follow the examples and answer the last question. <image>Question: {question} Answer:
```

## 5.4 Report curation and question-answer pair generation

### 5.4.1 Curriculum part 1: Introduction to retina

To create the tabular reports for the first part of the curriculum we used a cluster-based approach to efficiently label the 41,926 training images with biomarker annotations [37]. Contrastive learning is used to extract self-supervised features from the dataset. The dataset is then partitioned into 40 clusters of images that share common features. Labels are then assigned to these clusters by senior ophthalmologists. To this end, 20 images from each cluster were reviewed by senior ophthalmologists. If the majority of the images exhibited common features, such as 'large drusen' or 'subretinal fluid', these labels were assigned to the entire cluster. These labels were used in combination with the patient's age, sex and their functional visual acuity score (measured on a LogMAR chart and converted to Letter score) to create the tabular reports. Additionally, the reports list three biomarkers that are stated as not being present. These are drawn from a distribution of all biomarkers, weighted by their prevalence in the dataset, that were not among the cluster labels for that image. Counts of the prevalence of each tabular variable among the images are shown in Figure 7a, and a sample of four tabular reports they result in are shown in Figure 7b.

To generate question-answer pairs from the large volume of tabular reports we used WizardLLM-70B, which was the most capable freely-available LLM at the time of the creation of the first part of the curriculum. This resulted in a total of 408,505 question-answer pairs. Examples of the question-answers pairs generated by this approach are shown in the 'curriculum part 1' section of Figure 10a and Figure 10b.

### 5.4.2 Curriculum part 2: Advanced retinal specialism

The second part of the curriculum used manually curated reports written by retinal specialists. Two junior ophthalmologists were tasked with describing the main pathological biomarkers and diagnoses related to AMD, while also noting any other observation regarding the retinal anatomy. This yielded high-quality textual reports that go beyond the short notes that ophthalmologists typically write in clinical routine. The first junior ophthalmologist, with three years of experience specializing in ophthalmology, wrote the majority of 244 reports (see Figure 8a). While these were highly accurate, they were less comprehensive in their analysis than the remaining 86 reports written by the junior ophthalmologist with 10 years of experience (see Figure 8b). In total, this process yielded the 330 specialist reports.

In total, we used 10 different instructions for generating up to 230 questions per image. The exact instructions used are documented in Section A.2. We take two preliminary steps before providing the instruction to the LLM. We firstly replace the `<ReportText>` identifier with the raw text of the image report. Additionally, many of the QA generation instructions make references to the guidelines that describe the mandatory capabilities of image-based clinical decision makers with regard to disease staging and patient referral for patients with AMD. The second step involves replacing any reference to the `<ObservationGuidelines>`, `<DiseaseStagingGuidelines>` or `<PatientReferralGuidelines>` by the text of the corresponding guidelines (documented in Figure 16). These guidelines were verified by senior ophthalmologists, and were instrumental for the generation of questions with improved diversity and coverage, and also for creating questions about biomarkers that were absent in the image (and typically not mentioned in the report).

The smaller number of reports in the advanced curriculum permitted the use of the more performant proprietary models for generating question-answer pairs. We used the ‘gpt-4o’ API endpoint from OpenAI. An example interaction with ‘gpt-4o’ for generating these question-answer pairs is shown in Figure 9. A sample of question-answers yielded by this approach are shown in the ‘part 2’ section of both Figure 10a and Figure 10b.

## 5.5 Vision-language model training and generation

### 5.5.1 Combined vision language training

When training on both curriculum part 1 and part 2, both the vision encoder and LLM used in RetinaVLM are kept *frozen*, that is, they are not updated during the entire training process. This mitigates issues of *catastrophic forgetting* [38], a phenomenon in which foundation models lose their general capabilities during the finetuning process. This is key to ensuring RetinaVLM can respond to versatile questions and instructions that it was not exposed to during training. While the vision encoder and LLM are frozen, RetinaVLM gains all its specialized capabilities solely through the training of the adapter.

Before training on the retrospective cohort we downsample each image by a factor of 2 from  $416 \times 512$  to  $208 \times 256$  pixels. We then augment each image using the protocol outlined in [17], which results in a randomly cropped OCT image of size  $192 \times 192$ . During training, we set the Llama 3’s system prompt to:

```
You are a helpful ophthalmological specialist chatbot capable of interpreting
retinal OCT images.
```

We begin the instruction that RetinaVLM will be trained on with the following line:

```
Here is an encoding of a retinal OCT image <Img><ImageHere></Img>\n
```

Then, for each image in the batch, we randomly select a corresponding question-answer pair from the current curriculum dataset. We then add the text of the question to the instruction. We then populate Llama3’s conversation template with the full instruction and corresponding answer to form the full textual input. We project this textual input to the embedding space of the LLM using the pre-existing tokenizer and embedding layer of the LLM (see Figure 15).

Simultaneously, we use the ophthalmic vision encoder  $E$  to extract the  $6 \times 6$  vision embeddings from each image. After flattening these, we apply the adapter to each embedding separately to project them to the embedding space of the language model. To create the final set of embeddings that are provided to the LLM, we replace the embeddings corresponding to the `<ImageHere>` phrase in the input with the 36 adapted vision embeddings.

Finally, the resulting sequence of adapted visual embeddings and language embeddings are passed together through the frozen LLM. This yields a list of predicted token logits with the same length as the input sequence. We then compute the causal language modeling loss between these predicted answer logits and the ground truth answer tokens. We then optimize the adapter to minimize this loss.

Beginning by randomly initializing the adapter, we train in this fashion for 100,000 steps on questions and answers regarding the 41,926 images in curriculum part 1 (introduction to retina) to obtain *RetinaVLM-Base*. The trained adapter is then further finetuned on the 71,165 questions and answers regarding the 330 images in curriculum part 2 (advanced retinal specialism) for 100,000 steps, resulting in the final *RetinaVLM-Specialist* model. For both curriculum parts, we use a batch size of 12 and the AdamW optimizer with  $\beta_1 = 0.9$  and  $\beta_2 = 0.999$ .

## 5.6 Testing for catastrophic forgetting

As a quick test to indicate whether RetinaVLM-Base and RetinaVLM-Specialist incurred catastrophic forgetting during training, we provided them a retinal OCT image and tested them on the following instruction which does not feature in curriculum parts 1 or 2:

```
Here is an encoding of a retinal OCT image <Img><ImageHere></Img>  
What is the capital of England?
```

Previous iterations of RetinaVLM that used a more complex adapter design were susceptible to responding with answers regarding the retinal OCT image, rather than answering the provided question. The simplified architectural approach used in this study results in models that pass this test.

### 5.7 Using VLMs for inference and generating text

After VLMs have been trained on image and text datasets, they can be used to generate responses to new questions and images. To use the baseline foundation VLMs for testing we take the central crop in each  $416 \times 512$  OCT image, resulting in an image of size  $384 \times 384$ . We then downsample the image to  $224 \times 224$  and repeat it along the color dimension, resulting in the  $3 \times 224 \times 224$  images that are required by both foundation models. To provide the image to the RetinaVLM variants during testing, we take a central crop of the  $208 \times 256$  downsampled images, resulting in an image of size  $192 \times 192$  required of both RetinaVLM variants.

We then employ the same method with all VLMs for generating responses to instructions. Provided the image and textual instruction, we build the output sequence of tokens by repeatedly appending the token to the output assigned the highest probability by the VLM. This is equivalent to using a temperature parameter set to 0, and is the standard approach for generating the most accurate and least creative output from LLM-based models. This process is repeated until a stop token is generated, signaling the end of the VLM’s response. The model’s tokenizer is then used to convert the numeric output tokens to the final free text output.

### 5.8 Experimental setup

Our entire evaluation was conducted in *zero-shot*, that is, after training on curriculum part 1 and part 2 RetinaVLM requires no further finetuning in order to perform tasks related to disease staging, patient referral and biomarker analysis. Instead, for each test we designed a specific instruction that was provided to all VLMs to generate the application-specific reports that were used in our analyses. These instructions were derived through experimentation with all VLMs on the validation set, so while they are not designed for any one VLM in particular, they do contain information related to the task at hand.

#### 5.8.1 Tests of disease staging

The following instruction was given to all VLMs to and obtain the reports of the 276 test images that were analyzed in Section 2.3. The instruction requests VLMs to begin by describing the image, and then deduce the most advanced disease stage:

```
Describe the OCT image in detail and list any biomarkers or abnormalities,  
including the most likely AMD stage of the patient.
```

```
Then, based on those observations, state if the patient's most advanced AMD  
stage is 'healthy', 'early', 'intermediate', 'late dry', 'late wet (inactive)'  
or 'late wet (active)'?
```

After the VLM generated its report (using a maximum of 500 tokens), we appended the following text to its response.

```
Based off the image and those findings, the patient's most advanced AMD stage is
```

before continuing generation for another 300 tokens. From these tokens, we extracted the final disease staging prediction by searching for the first instance of any of the listed disease stages. This post-processing step is only necessary for quantitative tests of accuracy, as it enables the reliable extraction of the disease stage from the free text report. In cases where the VLM discusses multiple disease stages, such as in ‘more advanced than early AMD, and is intermediate AMD as there is no evidence of late wet AMD’, the disease stage was manually extracted. In cases where no disease stage was provided or could be extracted manually, this counted as an ‘Invalid response’.

#### 5.8.2 Evaluations of correctness, completeness and conciseness by senior ophthalmologists

For the direct evaluation by the senior ophthalmologists, we randomly selected 28 of the test images from the retrospective dataset, and tasked the two junior ophthalmologists with annotating the images. We provided the following instruction to RetinaVLM-Specialist and LLaVA-Med to generate their image reports:

Write an extensive report describing the OCT image, noting any biomarkers or abnormalities related to AMD, and their qualities. Also comment on which biomarkers are absent.

Finally, based on the image and these findings, your report should estimate the AMD disease stage of the patient.

You should not include any patient referral recommendations in your report, but you can comment if they need treatment with anti-vegf.

We found that LLaVA-Med tended to write excessively long reports. To improve the performance of LLaVA-Med, we adjusted the instruction to request a 'brief report' instead of an 'extensive report'. Even after this change, LLaVA-Med still produced very long and inaccurate reports.

We then assigned 14 of the images and the corresponding 42 reports by LLaVA-Med, RetinaVLM-Specialist and the junior ophthalmologists, to each of the two senior ophthalmologists, who evaluated them independently according to the correctness, completeness and conciseness. These criteria, also documented in Figure 4, were:

- Correctness - The report is accurate in its main observations and conclusions regarding the image
- Completeness - The report contains all relevant observations and conclusions that can be inferred from the image
- Conciseness - The report does not make observations and conclusions that are not supported by, or not seen in, the image

### 5.8.3 Tests of patient referral

The following instruction was given to all VLMs to generate reports that focus on patient referral recommendations, which are analyzed in Section 2.3. This instruction was run for the 95 referral images, introduced in Section 5.1.2. In order to accurately convey the specific requirements of the wet AMD treatment clinic, we provided the comprehensive referral protocol used by the senior ophthalmologists in the instruction:

Write an extensive report describing the OCT image and listing any present biomarkers or other observations. Do not provide a disease stage, or referral recommendation yet.

Being seen by a specialist at the Southampton clinic:

- A. The Southampton clinic requires that patients with any sign of intraretinal fluid, any sign of subretinal fluid, or any sign of cyst(s), MUST be seen by a specialist at the Southampton clinic within the next two weeks.
- B. The Southampton clinic requires that patients who do not have any sign of intraretinal fluid, any sign of subretinal fluid, or any sign of cyst(s), but do have some biomarkers of early or intermediate AMD, should be seen by a specialist at the Southampton clinic for routine referral.
- C. The Southampton clinic requires that patients who do not have any sign of intraretinal fluid, any sign of subretinal fluid, or any sign of cyst(s), but do have medium to large drusen, drusenoid PED, hypertransmission or atrophy, should be seen by a specialist at the Southampton clinic for routine referral.
- D. The Southampton clinic does not need to see patients who have no biomarkers and healthy retinas at all.

Southampton specialist visit: Next, tell me if your initial report of the OCT image indicates that the patient should be seen by a specialist at the Southampton clinic "within the next two weeks", to be seen "within 18 weeks (routine referral)", or "not be seen" at all?

As before, after the VLM generated its report (using a maximum of 500 tokens), we added the following text to its output:

My report indicates that the patient

before continuing generation for another 300 tokens. We then searched these tokens for the first instance of one of the three levels of referral urgency, ‘within the next two weeks’, ‘within 18 weeks (routine referral)’ or ‘not be seen’, in the VLM’s output report.

#### 5.8.4 Tests of biomarker analysis

The following instruction was given to all VLMs to generate reports that conclude the presence or absence of the 10 different biomarkers, evaluated on the 396 test images in Section 2.5:

Describe the OCT image in detail and list all biomarkers or abnormalities. Detail if there are any signs indicating that {biomarker} might be present, even if there is only a small amount.

Finally, conclude your findings by telling me if {biomarker} {article} "not present", or if potentially any amount of {biomarker} {article} "present" in the OCT image.

For each of the 10 biomarkers, the phrase {biomarker} was replaced by the actual biomarker name (such as ‘subretinal fluid’), and the {article} replaced by is for singular biomarkers or are for plural biomarkers (such as drusen). After the VLM generated its report (using a maximum of 500 tokens), we added the following text to its output.

To conclude these findings, in the OCT image {biomarker} {article}

before continuing generation for another 300 tokens. We then searched for the first instance of not present or present to extract the model’s prediction of the absence or presence of the biomarker, respectively.

#### 5.8.5 Computing language-based image saliency maps

We provide methodological details for the computation of the language-based saliency maps discussed in Section 2.5, and shown in Figure 6d and Figure 14. With saliency maps we aim to identify which regions of the image were most relevant to certain passages, such as large subretinal fluid, of RetinaVLM-Specialist’s responses. The most direct way to generate these visualizations to use attention maps, but we found Llama3’s pretrained attention maps did not result in any meaningful saliency maps. To address this, we used Grad-CAM [22], a technique for highlighting the most relevant image regions to the prediction of an image classifier. By defining the predicted class as the sum over the tokens in the output passage, which formulates the LLM as an image classifier, we were able to generate the saliency maps shown in Figure 6. A code implementation can be found at the repository referenced in Section 7.

### 5.9 Measurements of performance and statistical analysis

To calculate the performance of each VLM in multiple-choice question answering, we used the micro F1 score. This aggregates the total number of false positives (FP), false negatives (FN), true negatives (TN) and true positives (TP) over all classes before computing the F1 score using equation 1

$$F_1 = \frac{2 \cdot TP}{2 \cdot TP + FP + FN} \quad (1)$$

In cases where the VLM returned an ‘Invalid response’ this was counted as a false negative for the ground truth class. After calculating the F1 score, we determined the 95% confidence interval through bootstrapping  $N = 1000$  times with replacement.

Tests of significance (aggregated in Figure 12) were calculated using a two-sided McNemar’s test [39]. This test assesses the difference in the number of correctly versus incorrectly predicted samples, focusing on cases where the models agree or disagree on the labels. A significant p-value from the McNemar test allows us to reject the null hypothesis that both models have identical classification performance. We then used the following notation to indicate levels of statistical significance: \*\*\* for  $p \leq 0.001$ , \*\* for  $p \leq 0.01$ , and \* for  $p \leq 0.05$  and ‘ns’ (not significant) for  $p > 0.05$ .

### 5.10 Computing hardware and software

We use Python 3.12.2 to conduct all model question-answer generation, VLM training, and VLM evaluation. To generate the question-answer pairs for curriculum part 1 we used 3 40GB NVIDIA A40 GPUs. For both training RetinaVLM and for evaluating all VLMs we use a single 80GB NVIDIA A100 GPU and PyTorch [40] version 2.1.2. Training RetinaVLM on takes 1 day on curriculum part 1, and another day on curriculum part 2. Llama3 was downloaded via Huggingface with model ID 'meta-llama/Meta-Llama-3-8B-Instruct'. The baseline VLM Med-Flamingo's code and model weights were installed following the instructions at <https://github.com/fastscience-ai/MedFlamingo>, and LLaVA-Med's from <https://github.com/microsoft/LLaVA-Med>. Confusion matrices and results calculations were computed with scikit-learn version 1.4.1 and numpy version 1.26.4. Figures and tables were created in draw.io v24.4.0 using plots generated by matplotlib version 3.8.4 and seaborn version 0.13.1. Grad-CAM was computed using grad-cam version 1.5.0. McNemar's tests of significance were calculated using statsmodels version 0.14.1.

## 6 Data availability

Both imaging datasets are currently being curated and maintained by the Vienna Reading Center on behalf of the PINNACLE consortium. The data will be made available to once the PINNACLE study concludes in 2026 [41].

## 7 Code availability

The code used to create the question-answer pairs, train, and evaluate the models will be uploaded to <https://github.com/RobbieHolland/SpecialistVLMs>. The code may be used to develop the models can be repurposed for other medical specialties. The model weights for RetinaVLM-Base and RetinaVLM-Specialist are both available at <https://huggingface.co/RobbieHolland/RetinaVLM>. These are only intended for research purposes related to retinal OCT images.

## A Supplementary material

### A.1 Question-answer generation prompts (introduction to retina)

The limited scope of the first part of the tabular reports led us to use only one prompt (see Section A.1.1) to create the 408,545 question-answers in curriculum part 1, ‘introduction to retina’.

#### A.1.1 General question-answering module

I am constructing a dataset to train a model to answer questions based solely on OCT images.

The model will access ONLY the image to deduce attributes. For context, the image in question has attributes as follows:

<ReportText>

Based on these attributes, generate a numbered list of diverse questions and answers.

Ensure the format is:

1. Q: [Question about an image attribute]

A: [Specific answer deduced from the image]

Rules:

- Questions should be crafted in a way that they don’t explicitly state the attribute values, but the answers should be based on them. All attributes can be determined from the image.
- Incorporate both yes/no and open-ended styled questions, but always provide a definitive answer in the answer section.
- Occasionally touch on patient outcome/treatment.

### A.2 Question-answer generation prompts (advanced retinal specialism)

Creating a large quantity and variety of question-answer pairs was important for preventing overfit when finetuning on the 330 images that constitute curriculum part 2. The prompts each focus on a different aspect of question answering and report writing, but are expected to have some overlap in the question-answer pairs they create. The six modules used to generate up to 230 question-answers per image report, as shown in Figure 2, are covered by the following 10 prompts:

1. Advanced biomarkers (Up to 30 total question-answers)
  - Up to 30 question-answer pairs specific to biomarkers (see Section A.2.1)
2. Disease staging definitions (Up to 50 total question-answers)
  - Up to 20 question-answers that use the observation and staging guidelines (see Section A.2.2)
  - Up to 30 question-answers that train the model to replicate any reasoning linking observations to the disease stage that is present in the report (see Section A.2.3)
3. Staging reasoning (Up to 60 total question-answers)
  - Up to 20 question-answers that use the observation and staging guidelines to train the model to explain the diagnosed disease stage in terms of the visible biomarkers (see Section A.2.4)
  - Up to 40 question-answers that focus on training the model in differentiating active from inactive late wet AMD (see Section A.2.5)
4. Referral reasoning (Up to 25 total question-answers)
  - Up to 25 question-answer pairs that focus on training the model to reason about different levels of urgency in patient referral (see Section A.2.6)
5. General visual question-answering (Up to 30 total question-answers)
  - Up to 15 question-answers created directly from the report, but specific to one attribute (see Section A.2.7)
  - Up to 15 question-answers created directly from the report, but including longer and more open-ended questions A.2.8)
6. Report writing (Up to 35 total question-answers)



- Up to 15 question-answers that focus on replicating the specialist's report (see Section A.2.9)
- Up to 20 question-answers that all three observational, disease staging and patient referral guidelines to train the model to create more sophisticated reports A.2.10)

### A.2.1 Advanced biomarkers module

I am constructing a dataset to train a model to answer questions based solely on OCT images.

Below are guidelines outlining what can appear in an OCT image:

<ObservationGuidelines>

However, the image the model is being asked about is characterised by the following description:

DESCRIPTION OF IMAGE: "<ReportText>"

Task: Write 30 varied questions and answers that ask the model about the image.

Ensure the format is:

1. Q: [Question or statement to describe the image]

A: [Augmented version of actual image description]

Rules:

- Ask separately about the presence, amount, location and type of some of the biomarkers in the guidelines
- Ask about the presence or absence of the biomarkers in the guidelines
- Rather than saying the image/description does not specify/mention a biomarker, instead say 'the image does not show/display/exhibit evidence of' the biomarker UNLESS its presence is already implied by another present biomarker. The model does not see the above description of the image, it's only given the original image when answering questions.
- Try not to give away too much information included in the image description in the question text. The model must learn to use the image to determine the answer, and not make educated guesses based on the question alone.
- The answer must be accurate and reflect the same information in the image description.
- Write nothing except the questions and answers.

Tips:

- Example questions: "Does this image show any subretinal fluid?" "Do you see any intraretinal fluid?" "Is there any hypertransmission?" "Does the image show a PED?"
- Answer style variation: Finally, do not start too many questions with "No, ..." or "Yes, ...". Vary the answer style (the biomarker is 'not present', 'is shown', 'exhibits no', 'does contain' etc...)
- Positive and negative balance: Try to include an even balance of questions with positive responses (i.e. ask the model about each of the biomarkers that were reported in the description) and negative responses (i.e. that biomarker is not present)

To do this, if you create a question about a biomarker that isn't in the description, try to create a second, similar question about a biomarker that is observable in the image.

In order to make the question set not give too much away about the image, you can make paired questions which have positive and negative responses.

For example, for an image with a PED but no subretinal fluid, if you ask f.e.

"Q: Is there a PED? If so, where? A: There is a PED present, it's in the center..."

you should also create a question with a negated answer f.e.

"Q: Is there any subretinal fluid? And in what quantity? A: There is no sign of subretinal fluid in the image...".

This will help you keep an even balance of positive and negative responses, so that the model cannot guess the answer to the question without considering the image.

### A.2.2 Disease staging definitions modules

I am constructing a dataset to train a model to answer questions based solely on OCT images.

Below are guidelines outlining what can appear in an OCT image:

<ObservationGuidelines>

<DiseaseStagingGuidelines>

However, the image the model is being asked about is characterised by the following description:

DESCRIPTION OF IMAGE: "<ReportText>"

Task: Write 20 varied questions and answers that ask the model about the image.

Ensure the format is:

1. Q: [Question or statement to describe the image]

A: [Augmented version of actual image description]

Rules:

- Information about the image should not be in the question.
- The answer must be accurate and reflect the same information in the image description.
- Write nothing except the questions and answers.

Tips:

- Questions should be specific and ask about certain attributes, or sets of attributes. For example "Q: Is there any subretinal fluid in this image?" or "Q: Is the AMD stage intermediate, or is it more advanced?".
- Ask separately about the presence, amount, location and type of some of the biomarkers. Try to create an even balance of 'yes and 'no' answers.
- Rather than saying the image does not directly/explicitly specify/mention the presence of an attribute, instead say 'the image does not exhibit/show/display/evidence' the attribute, UNLESS its presence is already directly implied by the presence of another attribute. The model does not see the above description of the image, it's only given the original image when answering questions.
- Sometimes the desired output format should be specific in the question (f.e. Answer with 'yes' or 'no', or answer by stating if the image 'does' or 'does not' contain the biomarker in question.)

### A.2.3 Disease staging from the report module

I am constructing a dataset to train a model to answer questions based solely on OCT images.

Common disease stages for age-related macular degeneration are: healthy (no-AMD), non-AMD pathology, early AMD, intermediate AMD, late dry AMD, late wet (inactive) AMD, late wet (active) AMD

These stages may be referred to with slightly different names in the image description.

If the description doesn't specify whether the late wet AMD is inactive or active, then you shouldn't either (just see how the description refers to it, but don't feel the need to copy it verbatim)

However, the image the model is being asked about is characterised by the following description:

DESCRIPTION OF IMAGE: "<ReportText>"

Task: Write 30 varied questions and answers that require the model to estimate the patient's disease stage from the image.

Ensure the format is enumerated:

1. Q: [Question or statement to describe the image]

A: [Augmented version of actual image description]

Rules:

- If the estimated disease stage is not provided in the report, do not write ANY questions and answers. Simply write "No disease stage in report".
- Try not to give away too much information included in the image description in the question text. The model must learn to use the image to determine the answer, and not make educated guesses based on the question alone.
- The answer must be accurate and reflect the same information in the image description.
- The questions and answers must vary in their style, formulation and vocabulary.
- Write nothing except the questions and answers.

Tips:

- Most questions should ask the model to first estimate the disease stage  
For example, "Decide the most advanced AMD stage supported by the image, and explain your reasoning by noting any biomarkers most relevant to that stage."
- If the explanation or reasoning for the disease stage is given in the report, make sure to include that in the model's answers
- Questions 1 to 20 should first ask the model to decide/estimate/determine/identify/... the (most advanced) disease stage, and then explain their answer.
- Questions 21 to 30 questions should ask for the biomarkers and then the disease stage, such as "Describe any relevant/notable/significant biomarkers, and link them to the most likely disease stage" (which will be the one in the report)

#### A.2.4 Disease staging reasoning (with guidelines)

I am constructing a dataset to train a model to answer questions based solely on OCT images.

Below is a schema outlining what can appear in an OCT image:

<ObservationGuidelines>

<DiseaseStagingGuidelines>

However, the image the model is being asked about is characterised by the following description:

## Specialist vision-language models for clinical ophthalmology

DESCRIPTION OF IMAGE: "<ReportText>"

Task: Write 20 varied questions and answers that require the model to perform chain-of-thought reasoning.

Ensure the format is:

1. Q: [Question or statement to describe the image]  
A: [Augmented version of actual image description]

Rules:

- Information about the image listed in the description should not be used in the question, only in the answer.
- Never use the word 'description' or 'mention' in the answer, the model does not see the description of the image, it only sees the original image itself.
- The answer must be accurate and reflect the same information in the image description.
- Write nothing except the questions and answers.

Tips:

- Some questions should ask the model to provide a long and detailed answer to questions like 'Describe all the observable biomarkers in the image and then link these to the most likely disease stage'.
- One or two questions should ask the model to explain/deduce the highest precedent AMD stage (i.e. the overall AMD stage) by describing the biomarker(s) in the image which belong to the most advanced disease stage, and linking them to the relevant disease stage.
- Some questions should ask the model to summarise any relevant biomarkers and, explaining its reasoning using the guidelines, conclude with the AMD stage. For example, a drusenoid PED suggests intermediate AMD, but if coupled with subretinal fluid the overall AMD stage becomes active late wet due to the fluid.
- Some questions should ask the model to fully describe and list all its image observations, and then conclude the presence, absence, location or quantity of a specific biomarker (f.e. 'Describe the OCT image in detail and note any abnormalities, and then tell me if the image contains subretinal fluid.')

### A.2.5 Disease staging reasoning second module

I am constructing a dataset to train a model to answer questions based solely on OCT images.

Below are guidelines outlining what can appear in an OCT image:

<DiseaseStagingGuidelines>

However, the image the model is being asked about is characterised by the following description:

DESCRIPTION OF IMAGE: "<ReportText>"

Task: Write 40 varied questions and answers that require the model to estimate the patient's disease stage from the image.

Ensure the format is enumerated:

1. Q: [Question or statement to describe the image]

## Specialist vision-language models for clinical ophthalmology

A: [Augmented version of actual image description]

Rules that always apply:

- If the estimated disease stage is not provided in the report, do not write ANY questions and answers. Simply write "No disease stage in report".
- If reasoning for the disease stage is provided in the report, you MUST include this logic/nuance in the model's answers.
- You MUST not give away information about the image description in the question text. The model must learn to use the image to determine the answer, and not make educated guesses based on the question alone.
- The answer must be accurate and reflect the same information in the image description.
- The questions and answers must vary in their style, formulation and vocabulary.
- Write nothing except the questions and answers.

Rules that are specific to differentiating cases of active, vs inactive, late wet AMD:

- In cases with an active late wet diagnosis, you MUST make it clear that the PRESENCE OF FLUID is what differentiates active from inactive late wet AMD. Make this clear when explaining the reasoning behind active late wet diagnoses.

So do not imply that f.e. "The disease stage is late wet AMD (active), as indicated by the subretinal/intraretinal fluid, subretinal hyperreflective material, ..."

Instead, you MUST explain that f.e. "The overall disease stage is late wet AMD, which is active due to the detection/presence of subretinal/intraretinal fluid. Inactive late wet features include fibrovascular PED, ..."

Or "Late wet AMD best describes the AMD stage. The detection/presence of subretinal/intraretinal fluid means this is active late wet AMD. Other late wet features include fibrovascular PED, ..."

- Similarly, in cases with an inactive late wet diagnosis, you MUST make it clear in the model's reasoning that the lack of fluid, in combination with the other biomarkers, is what resulted in the inactive late wet diagnosis.

For example, "The stage is late wet AMD according to the evidence/presence of subretinal hyperreflective material, but it is inactive as there is no detectable fluid of any kind in the image"

- The exact formulation of this answer must vary according to the question. Do not copy the examples too many times. Add a lot of diversity in the model's responses.

Tips:

- Most questions should ask the model to first estimate the disease stage
- Some questions should first ask the model for its disease stage prediction, and then ask it to explain its reasoning by noting visible biomarkers that relate to that stage

For example, "Decide the most advanced AMD stage supported by the image, and explain your reasoning by noting any biomarkers most relevant to that stage."

- The explanation for the disease stage may already be given in the report, but you can also use the guidelines provided to work out which biomarkers resulted in that disease stage.

- Questions 31 to 40 questions should ask for the biomarkers and then the disease stage, such as "Describe any relevant/notable/significant biomarkers, and link them to the most likely disease stage" (which will be the one in the report)

### A.2.6 Patient referral reasoning module

I am constructing a dataset to train a model to answer questions based solely on OCT images.

Below are guidelines outlining what can appear in an OCT image:

<DiseaseStagingGuidelines>

<PatientReferralGuidelines>

However, the image the model is being asked about is characterised by the following description:

DESCRIPTION OF IMAGE: "<ReportText>"

Task: Write 25 varied questions and answers that require the model to perform explain its reasoning before making conclusions and recommendations.

Ensure the format is:

1. Q: [Question or statement to describe the image]
- A: [Augmented version of actual image description]

Rules:

- Information about the image should not be in the question.
- Never use the word 'description' or 'mention' in the answer, the model does not see the description of the image, it only sees the original image itself.
- The answer must be accurate and reflect the same information in the image description.
- Write nothing except the questions and answers.
- The model sees each questions separately so they will not be seen together.

Tips:

- Some questions should ask the model to list any relevant biomarkers and, based on these, recommend if the patient should be referred or not.
- Many questions should make a series of requests, by asking the model to write a long and detailed answer reporting all the observable biomarkers, linking those to the most likely disease stage and then summarising the report with a patient referral recommendation.

For example, 'Describe the all biomarkers in the image, and based off of your observations which AMD best describe the patient. Summarise your report with a referral recommendation that follows the treatment guidelines.'

- Some questions should ask the model to recommend if the patient does: not need referral, if they need general attention by a specialist, or if they likely need treatment with anti-vegf based off the models observations
- Some questions should ask the model to explain/deduce/estimate the patient's risk (i.e. the recommended referral action) by first describing the most advanced or concerning biomarker(s) (i.e. the observable biomarker(s) which belong to the most severe disease stage)

### A.2.7 Specific report-based questions module

I am constructing a dataset to train a model to answer questions based solely on OCT images.

The image in question is characterised by the following description:

DESCRIPTION OF IMAGE: "<ReportText>"

Task: Write 15 varied questions and answers that ask the model about the image. They should

Ensure the format is:

1. Q: [Question or statement to describe the image]  
A: [Augmented version of actual image description]

Rules:

- Try not to give away too much information included in the image description in the question text. The model must learn to use the image to determine the answer, and not make educated guesses based on the question alone.
- The answer must be accurate and reflect the same information in the image description.
- Write nothing except the questions and answers.

Tips:

- Questions should be specific and ask about certain attributes, or sets of attributes. For example "Q: Is there any subretinal fluid in this image?".

## A.2.8 General report-based questions module

I am constructing a dataset to train a model to answer questions based solely on OCT images.

The image in question is characterised by the following description:

DESCRIPTION OF IMAGE: "<ReportText>"

Task: Write 15 varied questions and answers that ask the model about the image.

Ensure the format is:

1. Q: [Question or statement to describe the image]  
A: [Augmented version of actual image description]

Rules:

- The answer should be a modified and augmented version of the actual description.
- Try not to give away too much information included in the image description in the question text. The model must learn to use the image to determine the answer, and not make educated guesses based on the question alone.
- The answer must be accurate and contain the same information as the actual description. However, the order of the sentences as they are written must change and randomly vary.
- Write nothing except the questions and answers.

Tips:

- Some question should be general and ask to describe the image.
- Other questions should be more specific such as "Q: Is there any subretinal fluid in this image?" that have shorter answers.
- Example questions/statements might be "Describe the OCT image in detail." or "Can you give me a summary of the image?".



### A.2.9 Basic report writing module

I am constructing a dataset to train a model to answer questions based solely on OCT images.

The image in question is characterised by the following description.

DESCRIPTION OF IMAGE: "<ReportText>"

Task: Write 15 questions and answers that ask the model to describe the image in full. The first ten questions should ask to describe the entire image (with jumbled/permuted/randomised answers), while the final five should be more specific or use segments of the description.

Ensure the format is:

1. Q: [Question or statement to describe the image]
- A: [Augmented version of actual image description]

Rules:

- The answer should be a modified and augmented version of the actual description.
- The answer should contain the same information as the actual description but the order of the sentences as they are written must change and randomly vary
- The question must not contain any information about the image.
- Write nothing except the questions and answers.

Tips:

- Example questions/statements might be "Describe the OCT image in detail." or "Can you give me a summary of the image?" or "Write a report on this image to be given to an optometrist."

### A.2.10 Advanced report writing module

I am constructing a dataset to train a model to answer questions based solely on OCT images.

Below are guidelines outlining what can appear in an OCT image:

<ObservationGuidelines>

<DiseaseStagingGuidelines>

<PatientReferralGuidelines>

However, the image the model is being asked about is characterised by the following description:

DESCRIPTION OF IMAGE: "<ReportText>"

Task: Write 20 requests for reports that ask the model reason all the way from the observable biomarkers, linking these to the most advanced disease stage, and finally to a referral recommendation for the patient.

Ensure the format is:

1. Q: [Request to the model]
- A: [Answer or report deduced using actual image description]

## Specialist vision-language models for clinical ophthalmology

### Rules:

- Never use the word 'description' or 'mention' in the answer, the model does not see the description of the image, it only sees the original image itself.
- Try not to give away too much information included in the image description in the question text. The model must learn to use the image to determine the answer, and not make educated guesses based on the question alone.
- Write nothing except the questions and answers.
- The model sees each questions separately so they will not be seen together.

### Tips:

- Example questions/statements might be "Describe the OCT image in detail." or "Can you give me a summary of the image?" or "Write a report on this image to be given to a retinal specialist."
- Ask the model to explain why the AMD stage is not more advanced than it is (i.e. the absence of certain late stage biomarkers)
- Ask the model to explain why the AMD stage is more advanced than an earlier stage (i.e. the presence of certain late stage biomarkers)
- A few times, request verbose reports like "Write a report that starts by highlighting the most significant and salient biomarkers, and link these to the most probable disease stage. Conclude with a referral recommendation."