

# End-To-End Clinical Trial Matching with Large Language Models

Dyke Ferber (1, 2), Lars Hilgers (2), Isabella C. Wiest (2, 3), Marie-Elisabeth Leßmann (2, 4), Jan Clusmann (2, 5), Peter Neidlinger (2), Jiefu Zhu (2), Georg Wölflein (6), Jacqueline Lammert (7), Maximilian Tschochohei (8), Heiko Böhme (9, 10, 11, 12), Dirk Jäger (1), Mihaela Aldea (13), Daniel Truhn (14), Christiane Höper (15), Jakob Nikolas Kather (1, 2, 4, +)

1. Department of Medical Oncology, National Center for Tumor Diseases (NCT), Heidelberg University Hospital, Heidelberg, Germany
2. Else Kroener Fresenius Center for Digital Health, Technical University Dresden, Dresden, Germany
3. Department of Medicine II, Medical Faculty Mannheim, Heidelberg University, Mannheim, Germany
4. Department of Medicine I, University Hospital Dresden, Dresden, Germany
5. Department of Medicine III, University Hospital RWTH Aachen, Aachen, Germany
6. School of Computer Science, University of St Andrews, St Andrews, United Kingdom
7. Department of Gynecology and Center for Hereditary Breast and Ovarian Cancer, University Hospital rechts der Isar, Technical University of Munich (TUM), Munich, Germany
8. Google Cloud, Munich, Germany
9. National Center for Tumor Diseases (NCT/UCC), Dresden, Germany
10. German Cancer Research Center (DKFZ), Heidelberg, Germany
11. Medical Faculty and University Hospital Carl Gustav Carus, TUD Dresden University of Technology, Dresden, Germany
12. Helmholtz-Zentrum Dresden-Rossendorf (HZDR), Dresden, Germany

13. Department of Medical Oncology, Gustave Roussy, Villejuif, France; Paris Saclay University, Kremlin Bicêtre, France
14. Department of Diagnostic and Interventional Radiology, University Hospital Aachen, Germany
15. AstraZeneca GmbH, Germany

+ Corresponding author: jakob-nikolas.kather@alumni.dkfz.de

Jakob Nikolas Kather, MD, MSc

Professor of Clinical Artificial Intelligence

Else Kröner Fresenius Center for Digital Health

Technische Universität Dresden

DE – 01062 Dresden

Phone: +49 351 458-7558

Fax: +49 351 458 7236

Mail: jakob\_nikolas.kather@tu-dresden.de

ORCID ID: 0000-0002-3730-5348

## Abstract

### Background

Identifying suitable clinical trials for cancer patients is crucial to advance treatment modalities and patient care. However, due to the inconsistent format of medical free text documents and the often highly complex logic in the trials eligibility criteria, this process is not only extremely challenging for medical doctors, but also time-consuming and prone to errors. This results in insufficient inclusion of oncology patients in clinical trials, especially in a timely manner. The recent advent of Large Language Models (LLMs) has demonstrated considerable potential for interpreting electronic health records (EHRs), suggesting that they hold great promise to facilitate accurate trial matching at scale.

### Patients and Methods

We generated 51 realistic oncology-focused patient EHRs. For each, a database of all 105,600 oncology-related clinical trials worldwide from [clinicaltrials.gov](https://clinicaltrials.gov) was accessed by GPT-4o to identify a pool of suitable trial candidates with minimal human supervision. Patient eligibility was then screened by the LLM on criterion-level across a selection of trials from the candidate trial pool and

compared against a baseline defined by human experts. We then used criterion-level AI feedback to iterate over discrepant AI and human results, refining the human ground truth where necessary.

## Results

Our approach successfully identified relevant, human preselected candidate trials in 93.3% of test cases from all trials available worldwide and achieved a preliminary accuracy of 88.0% (1,398/1,589) when matching patient-level information on a per-criterion-basis using the initial human evaluation as baseline. Utilizing LLM feedback to interactively re-evaluate human scores revealed that 39.3% of criteria that were initially considered incorrect according to the human baseline were either ambiguous or inaccurately annotated by humans, leading to a total model accuracy of 92.7% after refining the human ground truth eligibility definitions.

## Conclusion

We present an end-to-end pipeline for clinical trial matching using LLMs, demonstrating high precision in screening for appropriate clinical trials at scale and matching selected candidate trials with high precision to individual patients, even outperforming the performance of qualified medical doctors. Additionally, our pipeline can operate both fully autonomously or with human supervision and is not intrinsically restricted to cancer, offering a scalable solution to enhance patient-trial matching for the real world.

## Keywords

Clinical Trial Matching • Oncology Trials • Eligibility Criteria • Artificial Intelligence • Large Language Model • GPT-4o

## Introduction

In oncology, clinical trials serve two purposes: they offer potential therapeutic benefits to cancer patients across all disease stages, ranging from early intervention to experimental treatments for those with limited or exhausted standard care options<sup>1,2</sup>. They are also crucial to advance scientific research, as new treatments can only be approved through rigorous clinical testing. However, the practical realization of clinical trial enrollments still remains far from satisfactory, from both patient and clinician perspectives. For clinicians, identifying suitable trials is often time-consuming<sup>3</sup> and complex due to patient-related factors such as performance status or comorbidities, logistical challenges like regional trial availability, systemic issues including lack of access to genomic testing, and the difficulty clinicians might face in locating available trials, all of which contribute to low enrollment rates of only 2-3% of potential trial candidates<sup>4</sup>.

Overall, there are three primary reasons for this:

First, the sheer volume of data generated during oncologic treatments, including hospital stay records, as well as genomic and imaging data, often accumulate, drastically increasing the burden on physicians<sup>5-7</sup>. These data are typically fragmented and unstructured<sup>8</sup>, comprising free text, tabular records, and more<sup>8</sup>. Secondly, the complexity and volume of clinical trials tailored to oncology further complicate the process. There are approximately 500,000 studies registered on ClinicalTrials.gov, out of which 105,732 are dedicated to patients with cancer as of May 2024. Like patient records, trial information often includes unstructured information, such as plain text eligibility criteria and requires complex logical combinations of disease conditions, histologic subtypes, molecular markers and comorbidities<sup>9</sup>. Thirdly, from a patient's perspective, due to the evolution of the disease and the need to avoid patient attrition from deteriorating clinical conditions, it is crucial that the time to inclusion and initiation of treatment in clinical trials is minimized to the shortest possible duration.

From a practical perspective, addressing these challenges requires clinicians to follow a two-step process: first, they must screen for potential trial candidates based on key patient criteria such as tumor type, stage, mutations and availability within the patient's area of residence; then, they need to perform detailed one-on-one matches of all the patient's information with each candidate trial's eligibility criteria.

So far, computational support tools designed to simplify this process have focused on only one of these steps at a time. For the first step, systems have primarily used embedding techniques, where patient and trial text data are converted into a numerical representation space and matched based on approximate mathematical similarity<sup>10,11</sup>. For the second step, most tools focus on converting unstructured text from patient records and trial information into a tabular-like format. For instance, Criteria2Query uses machine learning and rule-based methods to parse inclusion and exclusion criteria into a structured format accessible via database queries<sup>12</sup>.

Only recently, with advances in generative AI, particularly Large Language Models (LLMs) like GPT-4<sup>13</sup>, extracting and structuring information from medical documents has been drastically simplified<sup>14</sup>. The potential of LLMs has also been explored for matching patients to clinical trials based on comparing eligibility criteria to patient records<sup>15</sup>. For instance, den Hamer et al.<sup>16</sup> demonstrated that LLMs can accurately provide eligibility labels such as 'yes', 'no', or 'unknown' when given both trial information and patient data as input at the same time. In oncology, Wong et al.<sup>17</sup> extended this idea to account for complex logical conditions using a hierarchical matching procedure, showing that GPT-4 can excel at this task even without additional training. Fine-tuning LLMs on annotated trial data has markedly improved their performance even further. This approach has facilitated the development of a local, privacy-preserving model that closely rivals the capabilities of proprietary, large cloud-based LLMs<sup>18</sup>. Recently, the same research team created OncoLLM<sup>19</sup>, a new model that significantly reduces the performance gap with the current leading model, GPT-4.

Nevertheless, the aforementioned projects have several limitations:

First, they tend to focus on either step one or step two of the process, rather than integrating both. Additionally, for step one, discrete criteria such as recruitment status or intervention type take on only discrete values (e.g. sex, location or recruitment status), which would more effectively be managed through direct selection or filtering rather than embedding-based approaches that rely on inexact similarity matches. Second, all current LLM-based methods heavily rely on narrowly engineered prompts,

which can be lengthy and cumbersome (Wong et al.<sup>17</sup> report prompts of up to four pages). Third, due to the free-text nature in which eligibility criteria and patient information are processed by the model<sup>20</sup>, there is no guarantee that the responses will adhere strictly to the required criteria structure.

We herein present a fully end-to-end pipeline for clinical trial matching which we designed to overcome the aforementioned limitations. Our approach is based on two principles: using LLMs as central reasoning agents<sup>21</sup> capable of taking actions and programmatically enforcing trial eligibility criteria as structured programming objects rather than plain free text, thereby ensuring the model consistently outputs validly annotated information<sup>22</sup>.

Our contributions are the following:

1. To the best of our knowledge, we present the first *truly* end-to-end pipeline for clinical trial matching, starting with searching relevant trial candidates for a given patient from all cancer trials available world wide and ending with fully-annotated trial eligibility criteria for a relevant set of trials.
2. We provide an extensive and profound benchmarking, encompassing 51 oncology cases and matching over 1,580 single trial criteria that have been annotated by five human experts. We provide evidence that our pipeline excels in both, reliably filtering relevant trials from tens of thousands and providing highly accurate one-on-one eligibility matches with criterion-level feedback and explanations for users.
3. We demonstrate that LLMs can outperform medical doctors in clinical trial matching. Our findings reveal that nearly 40% of the initially contradictory answers between GPT-4o and physicians were accepted as valid responses upon refining the human baseline with criterion-level AI feedback, resulting in an overall criterion-level accuracy of 92.7% for our pipeline.
4. By enforcing trial eligibility criteria as structured programming objects rather than relying on them as free-text inputs, we guarantee that the LLM always outputs precisely and validly annotated information.

## Methods

### Clinical Trial Composition

Data was sourced from ClinicalTrials.gov on May 13, 2024, by filtering for the Condition/disease “*cancer*”, yielding a total of 105,600 registered clinical trials, provided in a JavaScript-Object Notation (JSON) file. Subsequently, we programmatically filter each clinical trial by selecting relevant metadata, including fields like recruitment status, available centers (locations) or allowed disease conditions. Next, to allow the generation of vector embeddings from free text, we combine several metadata fields such as the brief and official titles, detailed trial descriptions and brief summaries into a structured plain text field.

### Database Generation

When finding appropriate clinical trials for patients, physicians most often need to initially filter by specific, structured criteria like the locations of participating centers,

recruitment status or allowed disease conditions, while then also examining free text descriptions to precisely match patient conditions to exclusion and inclusion criteria. From a computational perspective, we are thus confronted with the fact that certain attributes, such as discrete metadata fields that have a set of discrete allowed options, require exact matches, whereas others need to be matched based on free text: This requires handling the issue of synonyms - such as recognizing that “lung metastases” and “pulmonary metastases” are equivalent - where exact pattern matches are unsuitable.

To address these issues, we developed a hybrid database that effectively combines exact field matching with vector proximity search to find clinical trials that most closely correspond to patient descriptions in representation space. For the former, we employed a local instance of a No-SQL database<sup>23</sup> (MongoDB), which offers several advantages in this context, including high scalability, a flexible schema design for sending nested requests, and robust performance when handling large datasets. Next, we generate vector embeddings - numerical representations - of the free, preprocessed text for each clinical trial using the “*BAAI/bge-large-en-v1.5*” embedding model locally, producing vector embeddings with a dimensionality of 768 from text with a maximum of up to 512 tokens each. As clinical trial information is most often considerably longer, we performed text splits, including a 50-character overlap to ensure comprehensive coverage and avoid information loss, such as by splitting text in the middle of a sentence. We store all text embeddings in a local collection of a vector database (ChromaDB<sup>24</sup>) for efficient similarity search, using cosine distance as the default search metric throughout our experiments.

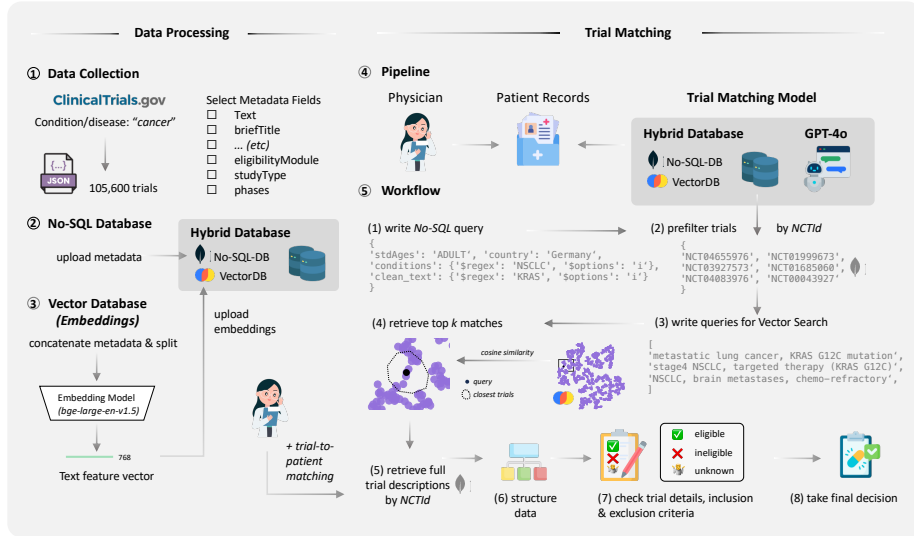
### **Clinical Case Generation**

Our experiments are based on published synthetic cases by Benary et al.<sup>25</sup>, which include ten fictional patient vignettes representing seven different tumor types, primarily lung adenocarcinoma (four cases), each annotated with various mutations (59 in total). To create a more realistic setting, we extended these cases to full medical EHR reports, using in-house original patient reports as templates, and including clinical descriptions of patient diagnoses, comorbidities, molecular information, short imaging descriptions from staging CT or MRI scans and patient history at different levels of detail. To ensure reliable matching of patients to existing clinical trials, we initially selected candidate trials through manual search or by utilizing those approved by a molecular tumor board from Lammert et al<sup>26</sup>. This led us to generating a total of 15 patient cases, which we refer to as base cases in the following. We then aligned the clinical case descriptions to either meet or contain conflicts with the respective trial eligibility criteria. This procedure was performed by first manually crafting patient reports based on medical expertise, then utilizing ChatGPT (GPT-4) for iterative refinement of style, grammar and language flow, leading to a total of 51 case vignettes. The final versions of these were evaluated for clinical realism, completeness and linguistic authenticity, and were approved by one physician with expertise in oncology before performing the experiments.

### **Trial Matching Pipeline Specifications**

The pipeline consists of two main components: the hybrid No-SQL-&-Vector database and an LLM that acts at its core to sequentially orchestrate database search, trial retrieval and finally trial matching with patient information. We utilized the “*GPT-4o*” model through the OpenAI integration in Python. Model hyperparameters were kept at

their default settings. As the LLM operates programmatically to access the database, its outputs cannot be plain text, but need to be valid programmatic data types and occasionally also adhere to certain constraints, such as belonging to a fixed, discrete set of options (like current recruitment status of a trial). Otherwise, invalid requests would lead to failures in accessing the database. We therefore constrain model output types by setting type hints in pydantic<sup>27</sup>.



**Figure 1: High-level overview of the proposed trial matching framework.** This figure provides an overview of the entire trial matching pipeline, divided into the data processing steps (left) and the workflow at inference time (trial matching, right). We begin with downloading clinical trial data from ClinicalTrials.gov in structured JSON format (1). We define metadata fields used for No-SQL database uploads and consecutive lookup operations (in our case, we use MongoDB) (2). Additionally we select metadata fields such as detailed trial titles, detailed descriptions and trial summaries that we concatenate into plain text. Next, the embedding model converts tokenized text into numerical representations (vectors), which we store for similarity search in a vector database (ChromaDB), forming the final hybrid DB structure (3). To accommodate the context window of the embedding model (BAAI/bge-large-en-v1.5 in our case has a limit of 512 tokens), we split the concatenated text with a 50-character overlap before forwarding it into the model. The final model comprises the hybrid database and an LLM (GPT-4o) that generates database requests (4). Next, we illustrate the entire pipeline end-to-end (5), starting from a given (cancer) patient record that encompasses clinical diagnoses, comorbidities, molecular alterations, and patient history, from which the LLM extracts relevant information to prefilter only valid trials via a No-SQL request (Step 1). Next, it rewrites the patient information into  $n$  short, precise queries for search over the vector database, where we measure the cosine distance between the query and all embedded clinical trial texts (Step 3) on the embedding level. From this procedure, only the top  $k$  closest trial samples are returned, with the additional constraint that they must be within the prefiltered set of trial IDs (Step 4). From these, the original trial descriptions, including their metadata are re-instantiated (Step 5). GPT-4o then inspects the suitability of a patient for a given trial by element-wise evaluation of the available patient information against the descriptions and criteria from the respective trial (Step 7). The trial can then be reviewed with criteria-level decisions and model explanations by the physician (Step 8).

The entire pipeline, which we illustrate in **Figure 1**, consists of a sequential chain

of LLM requests, where each LLM call is executed as a structured Chain-of-Thought (CoT) module: Upon invocation with a plain text description of a cancer patient and a user instruction (with varying levels of detail), the LLM extracts relevant metadata to prefilter the database in a No-SQL fashion. For all discrete attributes, we provide all available options as enforced type hints in a zero-shot manner; for open-ended free text search terms like disease conditions or keywords (for instance to filter free text for specific mutations) we provide manually crafted, few-shot examples. Next, each LLM output is converted into a valid No-SQL database query to extract all matching trials by their National Clinical Trial identifier (NCTId). Subsequently, to enhance the diversity of the retrieval step and remove uninformative information from the patient descriptions, GPT-4o is instructed to generate a maximum of five different queries from the main patient information, where the retrieval is constrained to filter only from the preselected pool of trials by NCTId. This step is performed iteratively over all queries. We end up with a collection of  $n$  top-matching trials from the vector search, from which we use NCTIds to retrieve full trial information. As outlined later, we additionally experimented with using reranking (Cohere rerank-english-v3.0<sup>28</sup>), which we omit from our final pipeline due to lack of additional benefits. Instead, for each trial, the LLM processes the fields containing brief trial summaries and detailed descriptions and discards trials that are deemed irrelevant to the patient. It then structures eligibility criteria programmatically with up to two levels of nested conditions and performs an element-by-element match of the structured inclusion and exclusion criteria to the patient information, returning only boolean values (True if patient is eligible according to a criterion, False otherwise) or unknown if the information provided to the LLM was insufficient to make a decision. To guide the model’s response in handling edge cases, we define few-shot examples: For instance, if a potential comorbidity is not mentioned in the patient’s EHR, the model is instructed to assume its absence unless the eligibility criteria require explicit exclusion. However, if any documented symptoms or indications in the EHR make the comorbidity plausible, the model should indicate that the information is insufficient (unknown). Additionally, for each single criterion, we receive an explanation by the model based on Chain-of-Thought reasoning.

One constraint we make during testing the model is that we permit it to include trials in an active but not currently recruiting status as an explicit design choice to ensure consistency with the trials described previously<sup>26</sup>.

## Human evaluations

Evaluations of all 51 trial candidates were conducted by five professionals experienced in medical oncology. To ensure one-to-one matches, the same criteria splits defined by GPT-4o for each trial were used for human annotations, with evaluations categorized as eligible, not eligible, or unknown. These ratings were performed using a browser-based interface that provided access to the full patient EHR, the trial NCTId, the trial’s official title, brief summary, and GPT-4o structured inclusion and exclusion criteria (Supplementary Figure 1). Each human evaluator worked independently, with results later aggregated using a majority vote as the aggregation criterion. During the second stage, where discrepant AI-human results were compared, we collected consensus responses through discussions of the model’s criterion-level explanations among three of the original evaluators, leading to either acceptance or rejection of the model’s response.



## Results

### Target Trial Identification Performance

We hypothesized that the process of filtering relevant trials on [clinicaltrials.gov](https://clinicaltrials.gov) could be optimized using GPT-4o to write No-SQL database queries, thereby reducing the manual burden on physicians. We evaluate this idea on a subset of 15 base cases from our EHR collection, using either clinical trials from Lammert et al<sup>26</sup> or potential target trials manually identified from [clinicaltrials.gov](https://clinicaltrials.gov). All prompts are provided in Supplementary Table 1.

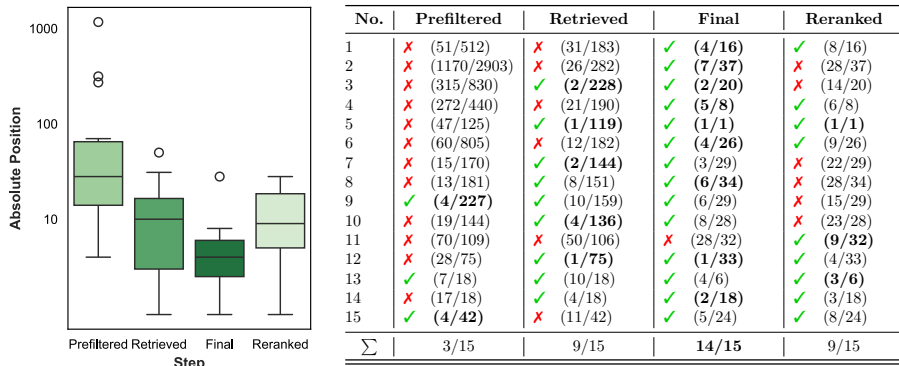
Our results indicate that using GPT-4o is sufficient to write a No-SQL query that filters all (15/15) potentially relevant trials - those that were preselected via manual search by humans for each patient base case - thus narrowing the initial pool of over 100,000 trials to a few hundred candidates (**Figure 2, left**). However, due to the variability in the number of trials for different conditions - such as rare mutations or tumor types yielding only a handful of trials, while others result in hundreds - it is not always feasible to process all filtered trials directly through an LLM. We therefore employed vector similarity search to enrich trials with highest potential relevance by calculating the cosine distance between trial information and patient EHRs in a representation space. We selected the top k=50 trials with the lowest cosine distance. These trials were then processed by GPT-4o, which was instructed to discard any irrelevant trials that falsely appeared relevant due to semantic overlap (**Figure 2, right**). As an example, consider a patient with “non-small cell lung cancer” and a clinical trial that is eligible only for “small cell lung cancer.” Despite the high semantic similarity (low cosine distance) between these terms, the patient would be ineligible for the trial. This discrepancy is accounted for by instructing GPT-4o to discard such trials, ensuring only relevant trials are selected.

Our results demonstrate that this combined approach is highly effective, reducing the number of candidate trials from hundreds to 20-30. Notably, 14 out of the 15 target trials (93.3%) fall within the top 10 trial options, and 10 out of 15 are ranked within the top 5 trials (**Figure 2, right**). Additionally, we evaluated the potential benefits of incorporating reranking models. Although these models have shown promising results in optimizing text retrieval tasks and relevance sorting for efficiency<sup>29</sup>, we did not observe significant improvements when applied to the full text of the trials using Cohere’s rerank-english-v3.0<sup>28</sup>. Therefore, we omitted reranking and considered the selected trials from the previous step as final.

Our findings demonstrate the potential of combining No-SQL database and vector similarity search with GPT-4o to effectively reduce the number of trials to a few candidate options, ensuring that only the most relevant ones are prioritized for each patient.

### Inclusion and Exclusion Criteria Accuracy

Next, we evaluated the criterion-level accuracy of GPT-4o across all 51 oncology EHRs for one target trial each, resulting in a total of 1,589 evaluable criteria, including both flat and nested ones. We show an example of how GPT-4o internally structures these eligibility criteria in Supplementary Table 2 and 3 and provide an example of GPT-4o’s full trial annotations including the unaltered eligibility criteria and criterion-level AI reasoning in Supplementary Table 4. For each criterion, the model was instructed to



**Figure 2: Absolute and top-k positions of target trials along the search process.**

We illustrate the average (left) and single (right) positions of 15 trial candidates, one for each of the patient base cases during the entire search process. These trial candidates were either selected manually or taken from the work of Lammert et al. At each step, only candidate trials from the previous step are used to further narrow down the collection of trials and identify the ones with best potential matching. A checkmark (✓) indicates that an expected trial is found within the top ten possible candidates, while a cross (✗) signifies that the trial does not fall within the top 10. In brackets, we denote the absolute position of the trial first, followed by the total number of trials that are selected as potential candidates for each step. In instances where GPT-4o employs multi-query retrieval, we aggregate the total number of trials and select the best (lowest) target trial position at each step. Herein *prefiltering* refers to the initial selection of trials from the entire database of 105,600 oncology trials by No-SQL query selection, based on categorical criteria like study type, overall status, and locations and trial specific free text search terms including keywords (primarily mutations) and conditions (mostly disease types). *Retrieved* denotes trials that are selected through vector search via embedding lookup. *Final* denotes selecting the top n of closest trials and prescreening of relevant trials through GPT-4o by comparing patient summaries and trial brief descriptions. Lastly, *reranking* is performed using the Cohere rerank-english-v3.0 model. As an example, in case 4, after prefiltering, the model identified 440 potential candidates, with the relevant target trial positioned at 272. At the final step, the pool was narrowed down to 8 trials, with the target trial ranked 5th. The lowest positions across all steps, indicating the highest similarity to the patient’s case, are highlighted in bold. Our results show that retrieval and model selection are the crucial steps in downsampling candidate trials and prioritizing on the most relevant ones. We highlight this finding by evaluating the trial lookup process by the number of expected target trials that are represented in the top 10 trials found by the LLM (right). Notably, while prefiltering is crucial for narrowing down the number of trials to be evaluated from an initial 105,600, it has only a negligible impact on the relevance ranking of trials. This ranking is predominantly determined by the cosine similarity search during the retrieval phase and GPT-4o prescreening (*final*), as it positions all of the relevant trial candidates among the top ten trials for each of the respective patient queries except one. Unexpectedly, reranking has no additional effect on the sorting of relevant trials, such that we omit it during all further work in this project. This process ends in a final collection of top trial candidates that are further passed to one-on-one eligibility criteria checks.

return one of three responses: True if the patient was eligible based on that criterion alone, False if the patient was not eligible, or “unknown” if the available data was inadequate to make a decision. In cases involving nested criteria, where the criterion “header” was not directly evaluable (e.g., “All patients:” or “(At least) one of the following:”), the model was additionally instructed to provide a global criterion result

that reflects the logical aggregation of the nested criteria. We use the majority answer from annotations, generated by five independent board-licensed physicians on all 1,589 criteria as a human baseline for comparing to the model’s performance, which we highlight in **Figure 3**. Notably, as elaborated later, we do not speak of human annotations as ground truth. Our results demonstrate that GPT-4o achieves an overall - preliminary - accuracy of 88.0% (calculated as the number of criteria where human and LLM decisions agree, divided by the total number of criteria, **Figure 3**), with similar performance when considering inclusion and exclusion criteria separately (87.5% and 88.6% respectively). All patient cases can be found in Supplementary Table 5.

Additionally, we find that GPT-4o achieved a 96.5% accuracy when focusing solely on True or False answers by either the model or human observers (“True/False”). The same observation is made when excluding model N/A answers only, which led to 96.5% of the answers being considered correct upon comparison to the human annotations (“no AI N/A”). We consider excluding model N/A outputs as an even better indicator of the model’s performance as outputs that point out its inability to answer the criterion due to insufficient patient or trial information are less critical in real-world settings than incorrectly assigning ineligibility or eligibility.

In summary, we can show that besides finding relevant trial candidates, GPT-4o can next evaluate patient eligibility on these selected trials with very high criterion-level accuracy.

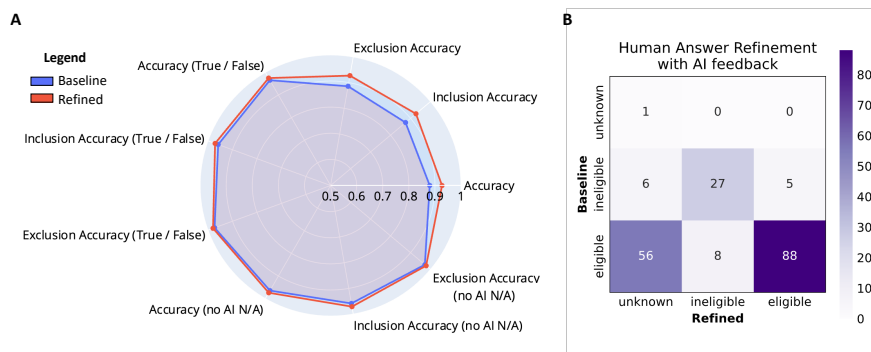
### Refining human baseline with AI feedback

To better understand the reasons behind differences in model versus human annotations at the criterion level, we re-evaluated all 191 cases where answers did not align. This process was performed by three of the original observers, who debated these discrepancies: We found that 39.3% (75 out of 191) of the initially conflicting answers were accepted after considering the model’s reasoning and re-assessing the patient case and specific criteria. Following this refinement of human baseline, our trial matching pipeline showed a 4.7% improvement in performance, achieving an overall accuracy of 92.7%. Furthermore, our model consistently performed above the 97% accuracy threshold when focusing on True and False answers only (“True/False”) or excluding model responses referring to missing information (“no AI N/A”) from the measurement (**Figure 3A**).

We next investigated the types of refinements human annotators made upon reviewing model answers (**Figure 3B**): We found that a substantial number of corrections to human annotations were necessary when annotators initially considered a patient eligible or ineligible for a certain criterion, while relevant information to make a decision was absent in reality (74.7%, 56/75 and 8%, 6/75 respectively). More importantly however, we found scenarios in which human annotators corrected eligible to ineligible decisions (10.7%, 8/75) and ineligible to eligible (6.7%, 6/75), indicating instances where human annotators made substantial mistakes that could be corrected using AI feedback.

In summary, we herein show that GPT-4o can match, and likely even exceed the performance of qualified physicians in evaluating patient trial eligibility.

Metric	Baseline	Refined	# Baseline	# Refined
<b>Accuracy</b>	88.0%	<b>92.7%</b>	(1398/1589)	(1473/1589)
Inclusion Accuracy	87.5%	<b>92.7%</b>	(755/863)	(800/863)
Exclusion Accuracy	88.6%	<b>92.7%</b>	(643/726)	(673/726)
<b>Accuracy (True/False)</b>	96.5%	<b>97.4%</b>	(1305/1353)	(1318/1353)
Inclusion Accuracy (True/False)	95.8%	<b>97.1%</b>	(692/722)	(701/722)
Exclusion Accuracy (True/False)	97.3%	<b>97.9%</b>	(614/631)	(618/631)
<b>Accuracy (no AI N/A)</b>	96.5%	<b>97.4%</b>	(1305/1353)	(1318/1353)
Inclusion Accuracy (no AI N/A)	95.8%	<b>97.1%</b>	(692/722)	(701/722)
Exclusion Accuracy (no AI N/A)	97.1%	<b>97.8%</b>	(613/631)	(617/631)



**Figure 3: Criterion-level patient-to-trial matching performance.** We illustrate the end-to-end criteria-level decision making performance of GPT-4o in our oncology trial matching pipeline (A), evaluating it on 1,589 criteria across 51 cases. We first compared the model performance to a baseline annotated by five independent licensed physicians, resulting in an overall accuracy of 88.0% (Baseline). We then assessed accuracy for criteria where model and human reference answers aligned on True or False only (“True/False”) and on a subset of the data where N/A answers from the model were excluded (“no AI N/A”). Subsequently, we re-evaluated the human baseline with three of the original observers using criteria-level AI feedback on all questions where LLM and human majority votes did not align (n=191), showing an overall 4.7% increment in accuracy on the newly formed refined human “ground truth” (“Refined”). We additionally highlight the shifts in corrections made by human annotators during the refinement stage, as shown in the transition matrix in B. The diagonal represents annotations that remained unchanged (116/191), resulting in a remaining 75 out of 191 cases where physicians accepted the AI response. Notably, the majority of corrections happened when physicians initially deemed a patient eligible for a certain criterion but agreed with the LLM that sufficient information was actually missing (74.7%, 56/75). More importantly, we observed that refinements were also made for changes between eligible and ineligible decisions and vice versa, occurring in 10.7% (8/75) and 6.7% (5/75) of cases, respectively. Additionally, we identified scenarios where human annotators corrected decisions from eligible to ineligible (10.7%, 8/75) and from ineligible to eligible (6.7%, 6/75), highlighting the potential of using AI feedback to correct human mistakes.

## Discussion

In this work, we describe and validate a fully end-to-end approach for leveraging LLMs for clinical trial matching using oncology cases as an example. Overall, we demonstrate how GPT-4o can first effectively screen potential trial candidates from a collection of over one hundred thousand clinical trials registered on clinicaltrials.gov and secondly match selected candidates on a criterion-by-criterion basis to patient records.

This has several real-world advantages: From a clinical perspective, physicians must filter out over 99.9% of irrelevant trials due to differing tumor types, disease stages, or distant locations. Additionally, they must consider what type of trials they are specifically looking for: Should they target a particular molecular alteration? Are they seeking trials for treatment-naive patients, or for those refractory to other therapies? Consequently, physicians are often forced to rely on ad hoc searches rather than structured methods to find suitable clinical trials. Given the inherent capabilities of state-of-the-art LLMs, we show that the process of filtering relevant trials by keyword-based search can be automated using GPT-4o, which can itself write queries for a No-SQL database, guided without or with human supervision, such as “Please find a Phase 1 trial for the patient in Germany” or “Could you please find a clinical trial for the patient’s KRAS mutation (or all of the patient’s mutations)?”

Our approach leverages the robust capabilities of GPT-4o in generating valid computer code, allowing programmatic access to trial databases with only optional human guidance. For instance, GPT-4o can request trials in specific locations or target particular mutations, or combinations of both if given as instruction from medical professionals. This makes our system highly scalable and flexible, extending its applicability beyond pre-selecting trials from a single center, as demonstrated by Gupta et al.<sup>19</sup>

Moreover, we are convinced of the inherent reasoning capabilities of LLMs<sup>21</sup>, particularly looking toward future advancements, allowing them to handle complex logic internally. In contrast, the approach by Wong et al.<sup>17</sup> explicitly enforces LLMs to rewrite eligibility logic into structured Disjunctive Normal Form (DNF), imposing constraints on the model by limiting the combination of categories such as disease state, histology, and biomarkers through logical conditions (and, or, all, any, not etc.). This method also alters the original trial criteria, complicating human evaluation. Our approach ensures that the model’s output can be mapped back to the original criteria on a one-by-one basis, with each criterion accompanied by a detailed chain of reasoning explaining the model’s decision. This allows medical doctors to fact-check each decision of the model, ensuring explainability and trust. By understanding why the model reaches a particular conclusion and identifying potential errors we can better understand capabilities and limitations of current LLMs in managing EHR data.

Additionally, we demonstrate that our system’s performance can match and under certain conditions even surpass that of human experts in criterion decision tasks. Although not directly comparable due to different trials and patient data (Gupta et al. utilize real-world de-identified EHR cases) and potential variations in how trial criteria are processed, our overall pipeline achieves an accuracy of 92.7% and 97.4% when excluding N/A samples. This exceeds the results others have previously achieved with GPT-4, reporting accuracies of 68% and 72%, respectively<sup>19</sup>.

Moreover, our program-rather-than-prompt strategy ensures that responses consistently adhere to the required format, reducing the burden of finding optimal, often specific and narrow prompts. We therefore can guarantee that regardless of the length or complexity of the criteria, we receive validly annotated and unaltered criteria back from the LLM, which is not the case if criteria are handled as plain, free text.

Also, this approach allows the broad transferability of our system to other medical domains, with minimal need for adjustments, such as only the need for addressing domain-specific edge cases.

Nevertheless, our study has several limitations: In real-world scenarios, under current regulatory restrictions, GPT-4o is not a suitable candidate due to its cloud-based nature, which necessitates transferring sensitive patient data to proprietary servers. Thus, we consider GPT-4o as a best-in-class model suitable for proof-of-concept purposes. We anticipate that local model solutions will catch up in performance in the near future, making them more suitable for clinical application. Additionally, real-world patient data will be required to fully validate applicability of our system, incorporating longer and even more diverse patient documents. For instance, laboratory values may be nested in spreadsheets, and imaging data might be separate, with all relevant patient information distributed across various documents. Moreover, we aim to evaluate the model’s ability to accurately rank and prioritize the most relevant trials, enabling doctors to quickly identify the best options for their patients. Although our system currently provides scores based on the number and ratio of fulfilled eligibility criteria, we have not yet established a sophisticated measure for quantitative evaluation. We plan to develop and refine this using real-world data in the near future.

Despite these challenges, our work demonstrates that an LLM can autonomously narrow down relevant trials from thousands to a manageable handful and accurately match these trials criterion by criterion. To our knowledge, our study is the closest in mirroring the real-world scenario of how medical doctors interact with clinical trial databases like *clinicaltrials.gov*. This evidence suggests significant potential for our approach, particularly as we show, for the first time, that AI feedback can enhance the performance of medical specialists in identifying suitable clinical trials for their patients.

## Acknowledgements

We thank OpenAI for supporting our work through a researcher access grant.

## References

1. Bouzalmate-Hajja, A., Massó Guijarro, P., Khan, K. S., Bueno-Cavanillas, A. & Cano-Ibáñez, N. Benefits of Participation in Clinical Trials: An Umbrella Review. *Int. J. Environ. Res. Public Health* **19**, (2022).
2. Unger, J. M., Cook, E., Tai, E. & Bleyer, A. The Role of Clinical Trial Participation in Cancer Research: Barriers, Evidence, and Strategies. *Am Soc Clin Oncol Educ Book* **35**, 185–198 (2016).
3. Penberthy, L. T., Dahman, B. A., Petkov, V. I. & DeShazo, J. P. Effort required in eligibility screening for clinical trials. *J. Oncol. Pract.* **8**, 365–370 (2012).
4. Unger, J. M., Vaidya, R., Hershman, D. L., Minasian, L. M. & Fleury, M. E. Systematic Review and Meta-Analysis of the Magnitude of Structural, Clinical, and Physician and Patient Barriers to Cancer Clinical Trial Participation. *J. Natl. Cancer Inst.* **111**, 245–255 (2019).
5. Oxentenko, A. S., West, C. P., Popkave, C., Weinberger, S. E. & Kolars, J. C. Time spent on clinical documentation: a survey of internal medicine residents and program directors. *Arch. Intern. Med.* **170**, 377–380 (2010).

6. Rule, A., Bedrick, S., Chiang, M. F. & Hribar, M. R. Length and Redundancy of Outpatient Progress Notes Across a Decade at an Academic Medical Center. *JAMA Netw Open* **4**, e2115334 (2021).
7. Moy, A. J. *et al.* Measurement of clinical documentation burden among physicians and nurses using electronic health records: a scoping review. *J. Am. Med. Inform. Assoc.* **28**, 998–1008 (2021).
8. Kong, H.-J. Managing Unstructured Big Data in Healthcare System. *Healthc. Inform. Res.* **25**, 1–2 (2019).
9. Bradley, J., Kelly, K. & Stinchcombe, T. E. The Ever-Increasing Number of Trial Eligibility Criteria: Time to Bend the Curve. *Journal of thoracic oncology: official publication of the International Association for the Study of Lung Cancer* vol. 12 1459–1460 (2017).
10. Zhang, X., Xiao, C., Glass, L. M. & Sun, J. DeepEnroll: Patient-Trial Matching with Deep Embedding and Entailment Prediction. *arXiv [cs.AI]* (2020).
11. Gao, J., Xiao, C., Glass, L. M. & Sun, J. COMPOSE: Cross-Modal Pseudo-Siamese Network for Patient Trial Matching. in *Proceedings of the 26th ACM SIGKDD International Conference on Knowledge Discovery & Data Mining* 803–812 (Association for Computing Machinery, New York, NY, USA, 2020).
12. Yuan, C. *et al.* Criteria2Query: a natural language interface to clinical databases for cohort definition. *J. Am. Med. Inform. Assoc.* **26**, 294–305 (2019).
13. OpenAI *et al.* GPT-4 Technical Report. *arXiv [cs.CL]* (2023).
14. Wiest, I. C. *et al.* From Text to Tables: A Local Privacy Preserving Large Language Model for Structured Information Retrieval from Medical Documents. *medRxiv* 2023.12.07.23299648 (2023) doi:10.1101/2023.12.07.23299648.
15. Jin, Q. *et al.* Matching Patients to Clinical Trials with Large Language Models. *ArXiv* (2024).
16. den Hamer, D. M., Schoor, P., Polak, T. B. & Kapitan, D. Improving Patient Pre-screening for Clinical Trials: Assisting Physicians with Large Language Models. *arXiv [cs.LG]* (2023).
17. Wong, C. *et al.* Scaling Clinical Trial Matching Using Large Language Models: A Case Study in Oncology. in *Proceedings of the 8th Machine Learning for Healthcare Conference* (eds. Deshpande, K. *et al.*) vol. 219 846–862 (PMLR, 11--12 Aug 2023).
18. Nievas, M., Basu, A., Wang, Y. & Singh, H. Distilling large language models for matching patients to clinical trials. *J. Am. Med. Inform. Assoc.* (2024) doi:10.1093/jamia/ocae073.
19. Gupta, S. K. *et al.* PRISM: Patient Records Interpretation for Semantic Clinical Trial Matching using Large Language Models. *arXiv [cs.CL]* (2024).
20. Wornow, M. *et al.* Zero-Shot Clinical Trial Patient Matching with LLMs. *arXiv [cs.CL]* (2024).
21. Truhn, D., Reis-Filho, J. S. & Kather, J. N. Large language models should be used as scientific reasoning engines, not knowledge databases. *Nat. Med.* **29**, 2983–2984

(2023).

22. Singhvi, A. *et al.* DSPy Assertions: Computational Constraints for Self-Refining Language Model Pipelines. *arXiv [cs.CL]* (2023).
23. Cattell, R. Scalable SQL and NoSQL data stores. *SIGMOD Rec.* **39**, 12–27 (2011).
24. Chroma. <https://www.trychroma.com/>.
25. Benary, M. *et al.* Leveraging Large Language Models for Decision Support in Personalized Oncology. *JAMA Netw Open* **6**, e2343689 (2023).
26. Lammert, J. *et al.* Expert-guided large language models for clinical decision support in precision oncology. (2024) doi:10.2139/ssrn.4855985.
27. Welcome to pydantic - pydantic. <https://docs.pydantic.dev/latest/>.
28. Introducing Rerank 3: A new foundation model for efficient enterprise search & retrieval. *Cohere* <https://cohere.com/blog/rerank-3>.
29. Sasazawa, Y., Yokote, K., Imaichi, O. & Sogawa, Y. Text Retrieval with Multi-Stage Re-Ranking Models. *arXiv [cs.IR]* (2023).

## Data availability statement

All clinical trial information used can be accessed and downloaded manually via <https://clinicaltrials.gov/> as detailed in “*Methods - Clinical Trial Composition*”. Note that available trials and information on existing trials will change over time. We release all 51 synthetic EHR notes, that are based on case vignettes published by Benary *et al.*<sup>25</sup> in Supplementary Data Table 5.

## Code availability statement

All methods necessary to reproduce our results are extensively documented. While we plan to enhance our pipeline further, we are committed to offering researchers access to our findings and methodologies in the near future. We release codes from the current implementation for research purposes upon publication in a scientific journal here: <https://github.com/Dyke-F/llm-trials>.

## Ethics statement

This study does not include confidential information. All research procedures were conducted exclusively on publicly accessible, anonymized patient data and in accordance with the Declaration of Helsinki, maintaining all relevant ethical standards. The overall analysis was approved by the Ethics commission of the Medical Faculty of the Technical University Dresden (BO-EK-444102022).

## Statement on use of Artificial Intelligence Tools

In accordance with the COPE (Committee on Publication Ethics) position statement of 13 February 2023 (<https://publicationethics.org/cope-position-statements/ai-author>), the authors hereby disclose the use of the following artificial intelligence models during the writing of this article. GPT-4 (OpenAI) for checking spelling and grammar.



## Author Contributions

DF designed and performed the experiments, evaluated and interpreted the results and wrote the initial draft of the manuscript. DF, LH and PN developed the case vignettes. ICW, JC, ML, LH and DF analyzed the results; ICW, LH and DF performed the eligibility re-evaluation. JZ designed the web interface for eligibility evaluation. CH provided expertise for the discussion of the implications of the findings. All authors contributed to writing the manuscript. MA, DJ, DT and JNK supervised the study.

## Funding

JNK is supported by the German Cancer Aid (DECADE, 70115166), the German Federal Ministry of Education and Research (PEARL, 01KD2104C; CAMINO, 01EO2101; SWAG, 01KD2215A; TRANSFORM LIVER, 031L0312A; TANGERINE, 01KT2302 through ERA-NET Transcan; Come2Data, 16DKZ2044A; DEEP-HCC, 031L0315A), the German Academic Exchange Service (SECAI, 57616814), the German Federal Joint Committee (TransplantKI, 01VSF21048) the European Union's Horizon Europe and innovation programme (ODELIA, 101057091; GENIAL, 101096312), the European Research Council (ERC; NADIR, 101114631), the National Institutes of Health (EPICO, R01 CA263318) and the National Institute for Health and Care Research (NIHR, NIHR203331) Leeds Biomedical Research Centre. The views expressed are those of the author(s) and not necessarily those of the NHS, the NIHR or the Department of Health and Social Care. This work was funded by the European Union. Views and opinions expressed are however those of the author(s) only and do not necessarily reflect those of the European Union. Neither the European Union nor the granting authority can be held responsible for them. JC is supported by the Mildred-Scheel-Postdoktorandenprogramm of the German Cancer Aid (grant #70115730). DT is funded by the German Federal Ministry of Education and Research (TRANSFORM LIVER, 031L0312A), the European Union's Horizon Europe and innovation programme (ODELIA, 101057091), and the German Federal Ministry of Health (SWAG, 01KD2215B). GW is supported by Lothian NHS. JL is supported by the TUM School of Medicine and Health Clinician Scientist Program (project no. H-08). CH contributed to this work in her personal interest outside of her employment at AstraZeneca GmbH. The views expressed are those of the author(s) and not necessarily those of AstraZeneca, the NHS, the NIHR or the Department of Health and Social Care. No other funding is disclosed by any of the authors.

## Competing Interests

JNK declares consulting services for Owkin, France; DoMore Diagnostics, Norway; Panakeia, UK, and Scailyte, Basel, Switzerland; furthermore JNK holds shares in Kather Consulting, Dresden, Germany; and StratifAI GmbH, Dresden, Germany, and has received honoraria for lectures and advisory board participation by AstraZeneca, Bayer, Eisai, MSD, BMS, Roche, Pfizer and Fresenius. DT received honoraria for lectures by Bayer and holds shares in StratifAI GmbH, Germany. ICW received honoraria from AstraZeneca. The authors have no additional financial or non-financial conflicts of interest to disclose.

## Supplementary Data

**Supplementary Table 1.** Model Instructions for Trial Search.

**Supplementary Table 2.** Unstructured eligibility criteria for NCT02227251: *Selinexor (KPT-330) in Patients With Relapsed/Refractory Diffuse Large B-Cell Lymphoma (DLBCL)*.

**Supplementary Table 3.** LLM-structured eligibility criteria for NCT02227251: *Selinexor (KPT-330) in Patients With Relapsed/Refractory Diffuse Large B-Cell Lymphoma (DLBCL)*.

**Supplementary Table 4.** Fully evaluated clinical trial eligibility criteria for Patient 1.1.1.

**Supplementary Figure 1.** Web-based user interface for assessing trial eligibility criteria on a per patient basis.

**Supplementary Table 5.** Clinical Case EHRs.

## Supplementary Table 1

No.	Prompts and Expected Trial
1	<b>Prompt:</b> Please find a Phase 1 clinical trial targeting the patients KRAS G13D mutation in the USA. <b>Target Trial:</b> NCT05254184
2	<b>Prompt:</b> Find a clinical trial for urachal adenocarcinoma in the United States. Ignore all mutations. <b>Target Trial:</b> NCT05756569
3	<b>Prompt:</b> Find a clinical trial for urachal adenocarcinoma in the United States. Ignore all mutations. <b>Target Trial:</b> NCT03866382
4	<b>Prompt:</b> Please find a clinical trial for the thymic cancer in Germany, that would fit the patient. Also check for trials targeting the BRCA mutation. <b>Target Trial:</b> NCT01078662
5	<b>Prompt:</b> Please find a clinical trial in Dresden for the patient targeting PIK3CA and MAPK1 mutations. <b>Target Trial:</b> NCT04551521
6	<b>Prompt:</b> Could you please find a clinical trial for the patient here in Germany focusing on MET as a target? <b>Target Trial:</b> NCT05488314
7	<b>Prompt:</b> Please find a clinical trial targeting the patients tumor and its KRAS mutation in Germany. <b>Target Trial:</b> NCT05358249
8	<b>Prompt:</b> Please find a clinical trial targeting the patients tumor and its KRAS mutation in Germany. <b>Target Trial:</b> NCT04685135
9	<b>Prompt:</b> Please find a clinical trial targeting the patients tumor and its KRAS mutation in Italy. <b>Target Trial:</b> NCT05789082
10	<b>Prompt:</b> Please find a clinical trial targeting the patients tumor and its KRAS mutation in Germany. <b>Target Trial:</b> NCT04699188
11	<b>Prompt:</b> The patient will move to France soon. Can you find a trial for the patient there? <b>Target Trial:</b> NCT06054555
12	<b>Prompt:</b> Could you please find a clinical trial for the patients molecular tumor alterations in Germany? <b>Target Trial:</b> NCT04526106
13	<b>Prompt:</b> Please find a trial by checking all of the patients molecular alterations in Germany. <b>Target Trial:</b> NCT04551521
14	<b>Prompt:</b> Please find a trial by checking all of the patients molecular alterations in Germany. <b>Target Trial:</b> NCT02628067
15	<b>Prompt:</b> Please find a clinical trial (Phase 1) for the patient's lung cancer in Germany. <b>Target Trial:</b> NCT04077463

**Supplementary Table 1: Model instructions for Trial Search.** We show the instructions (prompts) as provided to the model throughout the initial search process and the expected trial (which is not shown to the model). Corresponding results can be found in Figure 2.

#### Unstructured Eligibility Criteria for NCT02227251

##### Inclusion Criteria (Parts 1 and 2):

- \* Written informed consent in accordance with federal, local, and institutional guidelines. The participant must provide informed consent prior to the first screening procedure.
- \* Age greater than or equal to ( $\geq$ ) 18 years.
- \* ECOG performance status of less than or equal to ( $\leq$ ) 2.
- \* Participants should have estimated life expectancy of greater than ( $>$ ) 3 months at study entry.
- \* Previously treated, pathologically confirmed de novo DLBCL, or DLBCL transformed from previously diagnosed indolent lymphoma (e.g., follicular lymphoma).
- \* Participants must have received at least 2 but no more than 5 previous systemic regimens for the treatment of their de novo or transformed DLBCL including (i) at least 1 course of anthracycline-based chemotherapy (unless absolutely contraindicated due to cardiac dysfunction, in which case other active agents such as etoposide, bendamustine, or gemcitabine must have been given) and (ii) at least 1 course of anti-CD20 immunotherapy (e.g., rituximab), unless contraindicated due to severe toxicity. Participants who were considered ineligible for standard multi-agent immunochemotherapy must have received at least 2 and no more than 5 prior treatment regimens including at least 1 course of anti-CD20 antibodies and must be approved by the Medical Monitor. Prior stem cell transplantation is allowed; induction, consolidation, stem cell collection, preparative regimen and transplantation  $\pm$  maintenance are considered a single line of therapy.
- \* Female participants of child-bearing potential must have a negative serum pregnancy test at screening and agree to use reliable methods of contraception for 3 months after their last dose of medication. Male participants must use a reliable method of contraception if sexually active with a female of child-bearing potential. For both male and female participants, effective methods of contraception must be used throughout the study and for 3 months following the last dose.

##### Part 1 additional inclusion criteria:

- \* For participants whose most recent systemic anti-DLBCL therapy induced a PR or CR, at least 60 days must have elapsed since the end of that therapy. For all other participants, at least 14 weeks (98 days) must have elapsed since the end of their most recent systemic anti-DLBCL therapy. Palliative localized radiation within the therapy-free interval is allowed. Non-chemotherapy maintenance will not be considered anti DLBCL therapy, and therefore is allowed during the therapy-free interval.
- \* Documented clinical or radiographic evidence of progressive DLBCL prior to dosing.
- \* Participants must have measurable disease per the revised criteria for response assessment of lymphoma. Lymph nodes should be considered abnormal if the long axis is  $>1.5$  centimeter (cm), regardless of the short axis. If a lymph node has a long axis of 1.1 to 1.5 cm, it should only be considered abnormal if its short axis is  $>1.0$ . Lymph nodes  $\leq 1.0$  by  $\leq 1.0$  will not be considered abnormal for relapse or PD.

##### Part 2 additional inclusion criteria:

- At least 3 weeks (21 days) must have elapsed since the end of participant's most recent systemic anti-DLBCL therapy (prior to Cycle 1 Day 1). Palliative localized radiation within the therapy-free interval is allowed. Non-chemotherapy maintenance will not be considered anti-DLBCL therapy, and therefore is allowed during the therapy-free interval.
- Adequate hematopoietic function: (i) Hemoglobin  $\geq 10.0$  grams per deciliters (g/dL) within 14 days of starting therapy (participant may receive red blood cell [RBC] transfusion within 14 days).
- (ii) Absolute neutrophil count  $\geq 1000$  cells/millimeter ( $\text{mm}^3$ ) (use of granulocyte growth factors prior to and during the study is acceptable).
- (iii) Platelet count  $\geq 100,000/\text{mm}^3$  within 14 days of starting therapy (use of platelet growth factors prior to and during the study is acceptable).
- \* Participants must have measurable disease per the revised criteria for response assessment of lymphoma. Lymph nodes should be considered abnormal if the long axis is  $>1.5$  cm, regardless of the short axis. Extranodal lesion should be considered abnormal if the long axis is  $>1.0$  cm.

### Unstructured Eligibility Criteria for NCT02227251

#### Exclusion Criteria (Parts 1 and 2):

- \* Participants who are pregnant or lactating.
- \* Primary mediastinal (thymic) large B-cell lymphoma (PMBL)
- \* Participants must not be eligible for high-dose chemotherapy with autologous stem cell transplantation rescue (Investigator must provide detailed documentation for ineligibility).
- \* Participants who have not recovered to Grade  $\leq 1$  clinically significant adverse events, or to their baseline, from their most recent systemic anti-DLBCL therapy.
- \* Major surgery within 2 weeks of first dose of study treatment.
- \* Participants with active hepatitis B virus (HBV), hepatitis C virus (HCV), or human immunodeficiency virus (HIV) infections.
- \* Psychiatric illness or substance use that would prevent the participant from giving informed consent or being compliant with the study procedures.
- \* Any of the following laboratory abnormalities:

(i) A circulating lymphocyte count of  $>50,000/L$ . (ii) Hepatic dysfunction: bilirubin  $>2.0$  times the upper limit of normal (ULN) (except participants with Gilbert's syndrome: total bilirubin of  $>3$  \*ULN) and alanine aminotransferase (ALT) and aspartate aminotransferase (AST)  $>2.5$  times ULN. In participants with known liver involvement of their DLBCL, AST and ALT  $>5$  \*ULN.

(iii) Severe renal dysfunction: estimated creatinine clearance of  $<30$  mL/min, measured in 24-hour urine or calculated using the formula of Cockcroft and Gault  $\frac{[(140 - \text{Age}) * \text{Mass (kg)}]}{(72 * \text{creatinine mg/dL})}$ ; multiply by 0.85 if female.

- \* Any life-threatening illness, medical condition, or organ system dysfunction which, in the Investigator's opinion, could compromise the participant's safety.
- \* Participants with active graft-versus-host disease after allogeneic stem cell transplantation. At least 4 months must have elapsed since completion of allogeneic stem cell transplantation.
- \* Uncontrolled (i.e., clinically unstable) infection requiring parenteral antibiotics, antivirals, or antifungals on Cycle 1 Day 1; however, prophylactic use of these agents is acceptable even if parenteral.
- \* Participants unable to swallow tablets, participants with malabsorption syndrome, or any other gastrointestinal disease or gastrointestinal dysfunction that could interfere with absorption of study treatment.

#### Part 1 additional exclusion criteria:

- \* For participants whose most recent systemic anti-DLBCL therapy induced a PR or CR: Radiation, chemotherapy, immunotherapy, radio-immunotherapy, or any other anticancer therapy other than glucocorticoids  $<60$  days or  $<14$  weeks prior to Cycle 1 Day 1.
- \* Known central nervous system lymphoma or meningeal involvement.
- \* DLBCL with mucosa-associated lymphoid tissue (MALT) lymphoma, composite lymphoma (Hodgkin's lymphoma+NHL), or DLBCL transformed from diseases other than indolent NHL.
- \* Unstable cardiovascular function:
  - (i) Symptomatic ischemia, or (ii) Uncontrolled clinically significant conduction abnormalities (i.e., ventricular tachycardia on anti-arrhythmia are excluded; 1st degree atrioventricular block or asymptomatic left anterior fascicular block /right bundle branch block will not be excluded), or (iii) Congestive heart failure of New York Heart Association Class  $\geq 3$ , or (iv) Myocardial infarction within 3 months.
- \* Participants with a BSA  $<1.4$  m<sup>2</sup> as calculated per Dubois 1916 or Mosteller 1987.
- \* Any of the following laboratory abnormalities:

(i) Absolute neutrophil count (ANC)  $<1000$  cells/mm<sup>3</sup> or platelet count  $<75,000$ /mm<sup>3</sup> during screening and on Cycle 1 Day 1. Use of granulocyte-stimulating factors and platelet growth factors prior to and during the study is acceptable.

(ii) Hematopoietic dysfunction: hemoglobin  $< 10.0$  g/dL within 14 days of and including Cycle 1 Day 1 and/or patients receiving red blood cell (RBC) transfusion within 14 days of and including Cycle 1 Day 1.

- \* Participants who have been committed to an institution by official or judicial order.
- \* Participants with dependency on the Sponsor, Investigator or study site.

Unstructured Eligibility Criteria for NCT02227251

Part 2 additional exclusion criteria:

- \* Participants with active HBV, HVC, or HIV infections. Participants with active HBV are allowed if antiviral therapy for hepatitis B has been given for  $\geq 8$  weeks and viral load is  $< 100$  International units per milliliters (IU/mL) prior to first dose of study treatment. Participants with known history of HCV or found to be HCV antibody positive on screening, are allowed if there is documentation of negative viral load per institutional standard. Participants with HIV who have CD4+T-cell counts  $\geq 350$  cells/microliter (mCL), negative viral load per institutional standard, and no history of acquired immune deficiency syndrome (AIDS)-defining opportunistic infections in the last year are allowed.
- \* Known active central nervous system lymphoma or meningeal involvement. Participants with a history of CNS disease treated into remission may be enrolled.
- \* DLBCL with MALT lymphoma, composite lymphoma (Hodgkin's lymphoma + NHL), DLBCL arising from CLL (Richter's transformation), or high-grade B-cell lymphoma.
- \* Received strong cytochrome P450 3A (CYP3A) inhibitors  $\leq 7$  days prior to Day 1 dosing or strong CYP3A inducers  $\leq 14$  days prior to Day 1 dosing.

**Supplementary Table 2. Unstructured eligibility criteria:** Selinexor (KPT-330) in Patients With Relapsed/Refractory Diffuse Large B-Cell Lymphoma (DLBCL). This trial's eligibility criteria highlight the challenges faced by LLMs. Criteria are presented as free text and include multiple, nested inclusion and exclusion conditions and hierarchies (e.g. any, all). Formatting inconsistencies are common, with variations in line breaks, paragraphs, and enumeration symbols (e.g., bullets and roman numerals). Also, criteria headers can even be mixed with conditions (e.g. adequate hematopoietic function: (i) ...).

LLM-structured Eligibility Criteria for NCT02227251

**Inclusion:**

**LEVEL 1 CRITERION:** Inclusion Criteria (Parts 1 and 2):

**LOGIC:** Patients who meet all of the following criteria are eligible for trial participation:

**LEVEL 2 CRITERION:**

[

**LEVEL 3 CRITERION:** \* Written informed consent in accordance with federal, local, and institutional guidelines. The participant must provide informed consent prior to the first screening procedure.

**LEVEL 3 CRITERION:** \* Age greater than or equal to ( $\geq$ ) 18 years.

**LEVEL 3 CRITERION:** \* ECOG performance status of less than or equal to ( $\leq$ ) 2.

**LEVEL 3 CRITERION:** \* Participants should have estimated life expectancy of greater than ( $>$ ) 3 months at study entry.

**LEVEL 3 CRITERION:** \* Previously treated, pathologically confirmed de novo DLBCL, or DLBCL transformed from previously diagnosed indolent lymphoma (e.g., follicular lymphoma).

**LEVEL 3 CRITERION:** \* Participants must have received at least 2 but no more than 5 previous systemic regimens for the treatment of their de novo or transformed DLBCL including (i) at least 1 course of anthracycline-based chemotherapy (unless absolutely contraindicated due to cardiac dysfunction, in which case other active agents such as etoposide, bendamustine, or gemcitabine must have been given) and (ii) at least 1 course of anti-CD20 immunotherapy (e.g., rituximab), unless contraindicated due to severe toxicity. Participants who were considered ineligible for standard multi-agent immunochemotherapy must have received at least 2 and no more than 5 prior treatment regimens including at least 1 course of anti-CD20 antibodies and must be approved by the Medical Monitor. Prior stem cell transplantation is allowed; induction, consolidation, stem cell collection, preparative regimen and transplantation  $\pm$  maintenance are considered a single line of therapy.

**LEVEL 3 CRITERION:** \* Female participants of child-bearing potential must have a negative serum pregnancy test at screening and agree to use reliable methods of contraception for 3 months after their last dose of medication. Male participants must use a reliable method of contraception if sexually active with a female of child-bearing potential. For both male and female participants, effective methods of contraception must be used throughout the study and for 3 months following the last dose.

]

**Inclusion:** (continued ...)**LEVEL 1 CRITERION:** Part 1 additional inclusion criteria:**LOGIC:** Patients who meet all of the following criteria are eligible for trial participation:**LEVEL 2 CRITERION:**

[

**LEVEL 3 CRITERION:** \* For participants whose most recent systemic anti-DLBCL therapy induced a PR or CR, at least 60 days must have elapsed since the end of that therapy. For all other participants, at least 14 weeks (98 days) must have elapsed since the end of their most recent systemic anti-DLBCL therapy. .

Palliative localized radiation within the therapy-free interval is allowed. Non-chemotherapy maintenance will not be considered anti DLBCL therapy, and therefore is allowed during the therapy-free interval.

**LEVEL 3 CRITERION:** \* Documented clinical or radiographic evidence of progressive DLBCL prior to dosing.**LEVEL 3 CRITERION:** \* Participants must have measurable disease per the revised criteria for response assessment of lymphoma. Lymph nodes should be considered abnormal if the long axis is  $>1.5$  centimeter (cm), regardless of the short axis. If a lymph node has a long axis of 1.1 to 1.5 cm, it should only be considered abnormal if its short axis is  $>1.0$ . Lymph nodes  $\leq 1.0$  by  $\leq 1.0$  will not be considered abnormal for relapse or PD.

]

**LEVEL 1 CRITERION:** Part 2 additional inclusion criteria:**LOGIC:** Patients who meet all of the following criteria are eligible for trial participation:**LEVEL 2 CRITERION:**

[

**LEVEL 3 CRITERION:** • At least 3 weeks (21 days) must have elapsed since the end of participant's most recent systemic anti-DLBCL therapy (prior to Cycle 1 Day 1). Palliative localized radiation within the therapy-free interval is allowed. Non-chemotherapy maintenance will not be considered anti-DLBCL therapy, and therefore is allowed during the therapy-free interval.

[

**LEVEL 4 CRITERION:** • Adequate hematopoietic function: (i) Hemoglobin  $\geq 10.0$  grams per deciliters (g/dL) within 14 days of starting therapy (participant may receive red blood cell [RBC] transfusion within 14 days).**LEVEL 4 CRITERION:** (ii) Absolute neutrophil count  $\geq 1000$  cells/millimeter ( $\text{mm}^3$ ) (use of granulocyte growth factors prior to and during the study is acceptable).**LEVEL 4 CRITERION:** (iii) Platelet count  $\geq 100,000/\text{mm}^3$  within 14 days of starting therapy (use of platelet growth factors prior to and during the study is acceptable).

]

**LEVEL 3 CRITERION:** \* Participants must have measurable disease per the revised criteria for response assessment of lymphoma. Lymph nodes should be considered abnormal if the long axis is  $>1.5$  cm, regardless of the short axis. Extranodal lesion should be considered abnormal if the long axis is  $>1.0$  cm.

]

**Exclusion:****LEVEL 1 CRITERION:** Exclusion Criteria (Parts 1 and 2):**LOGIC:** Patients who meet any of the following criteria are not eligible for trial participation:**LEVEL 2 CRITERION:**

[

**LEVEL 3 CRITERION:** \* Participants who are pregnant or lactating.**LEVEL 3 CRITERION:** \* Primary mediastinal (thymic) large B-cell lymphoma (PMBL)**LEVEL 3 CRITERION:** \* Participants must not be eligible for high-dose chemotherapy with autologous stem cell transplantation rescue (Investigator must provide detailed documentation for ineligibility).**LEVEL 3 CRITERION:** \* Participants who have not recovered to Grade  $\leq 1$  clinically significant adverse events, or to their baseline, from their most recent systemic anti-DLBCL therapy.**LEVEL 3 CRITERION:** \* Major surgery within 2 weeks of first dose of study treatment.**LEVEL 3 CRITERION:** \* Participants with active hepatitis B virus (HBV), hepatitis C virus (HCV), or human immunodeficiency virus (HIV) infections.**LEVEL 3 CRITERION:** \* Psychiatric illness or substance use that would prevent the participant from giving informed consent or being compliant with the study procedures.

**Exclusion:** (continued ...)  
(continued ...)

- [
  - LEVEL 4 CRITERION:** \* Any of the following laboratory abnormalities:
  - LEVEL 4 CRITERION:** (i) A circulating lymphocyte count of  $>50,000/L$ . (ii) Hepatic dysfunction: bilirubin  $>2.0$  times the upper limit of normal (ULN) (except participants with Gilbert's syndrome: total bilirubin of  $>3 \times ULN$ ) and alanine aminotransferase (ALT) and aspartate aminotransferase (AST)  $>2.5$  times ULN. In participants with known liver involvement of their DLBCL, AST and ALT  $>5 \times ULN$ .
  - LEVEL 4 CRITERION:** (iii) Severe renal dysfunction: estimated creatinine clearance of  $<30$  mL/min, measured in 24-hour urine or calculated using the formula of Cockcroft and Gault  $\left[ \frac{140 - \text{Age}}{72} \times \frac{\text{Mass (kg)}}{\text{creatinine mg/dL}} \right]$ ; multiply by 0.85 if female.
- ]
  - LEVEL 3 CRITERION:** \* Any life-threatening illness, medical condition, or organ system dysfunction which, in the Investigator's opinion, could compromise the participant's safety.
  - LEVEL 3 CRITERION:** \* Participants with active graft-versus-host disease after allogeneic stem cell transplantation. At least 4 months must have elapsed since completion of allogeneic stem cell transplantation.
  - LEVEL 3 CRITERION:** \* Uncontrolled (i.e., clinically unstable) infection requiring parenteral antibiotics, antivirals, or antifungals on Cycle 1 Day 1; however, prophylactic use of these agents is acceptable even if parenteral.
  - LEVEL 3 CRITERION:** \* Participants unable to swallow tablets, participants with malabsorption syndrome, or any other gastrointestinal disease or gastrointestinal dysfunction that could interfere with absorption of study treatment.
- ]
  - LEVEL 1 CRITERION:** Part 1 additional exclusion criteria:
  - LOGIC:** Patients who meet any of the following criteria are not eligible for trial participation:
  - LEVEL 2 CRITERION:**
    - [
      - LEVEL 3 CRITERION:** \* For participants whose most recent systemic anti-DLBCL therapy induced a PR or CR: Radiation, chemotherapy, immunotherapy, radio-immunotherapy, or any other anticancer therapy other than glucocorticoids  $<60$  days or  $<14$  weeks prior to Cycle 1 Day 1.
      - LEVEL 3 CRITERION:** \* Known central nervous system lymphoma or meningeal involvement.
      - LEVEL 3 CRITERION:** \* DLBCL with mucosa-associated lymphoid tissue (MALT) lymphoma, composite lymphoma (Hodgkin's lymphoma+NHL), or DLBCL transformed from diseases other than indolent NHL.
    - [
      - LEVEL 4 CRITERION:** \* Unstable cardiovascular function:
      - LEVEL 4 CRITERION:** (i) Symptomatic ischemia, or (ii) Uncontrolled clinically significant conduction abnormalities (i.e., ventricular tachycardia on anti-arrhythmia are excluded; 1st degree atrioventricular block or asymptomatic left anterior fascicular block /right bundle branch block will not be excluded), or (iii) Congestive heart failure of New York Heart Association Class  $\geq 3$ , or (iv) Myocardial infarction within 3 months.
    - ]
      - LEVEL 3 CRITERION:** \* Participants with a BSA  $<1.4$  m<sup>2</sup> as calculated per Dubois 1916 or Mosteller 1987.
    - [
      - LEVEL 4 CRITERION:** \* Any of the following laboratory abnormalities:
      - LEVEL 4 CRITERION:** (i) Absolute neutrophil count (ANC)  $<1000$  cells/mm<sup>3</sup> or platelet count  $<75,000/mm^3$  during screening and on Cycle 1 Day 1. Use of granulocyte-stimulating factors and platelet growth factors prior to and during the study is acceptable.
      - LEVEL 4 CRITERION:** (ii) Hematopoietic dysfunction: hemoglobin  $<10.0$  g/dL within 14 days of and including Cycle 1 Day 1 and/or patients receiving red blood cell (RBC) transfusion within 14 days of and including Cycle 1 Day 1.
    - ]
      - LEVEL 3 CRITERION:** \* Participants who have been committed to an institution by official or judicial order.
      - LEVEL 3 CRITERION:** \* Participants with dependency on the Sponsor, Investigator or study site.
    - ]
      -



LLM-structured Eligibility Criteria for NCT02227251

**Exclusion:** (continued ...)

**LEVEL 1 CRITERION:** Part 2 additional exclusion criteria:

**LOGIC:** Patients who meet any of the following criteria are not eligible for trial participation:

**LEVEL 2 CRITERION:**

[

**LEVEL 3 CRITERION:** \* Participants with active HBV, HVC, or HIV infections. Participants with active HBV are allowed if antiviral therapy for hepatitis B has been given for  $\geq 8$  weeks and viral load is  $< 100$  International units per milliliters (IU/mL) prior to first dose of study treatment. Participants with known history of HCV or found to be HCV antibody positive on screening, are allowed if there is documentation of negative viral load per institutional standard. Participants with HIV who have CD4+T-cell counts  $\geq 350$  cells/microliter (mCL), negative viral load per institutional standard, and no history of acquired immune deficiency syndrome (AIDS)-defining opportunistic infections in the last year are allowed.

**LEVEL 3 CRITERION:** \* Known active central nervous system lymphoma or meningeal involvement. Participants with a history of CNS disease treated into remission may be enrolled.

**LEVEL 3 CRITERION:** \* DLBCL with MALT lymphoma, composite lymphoma (Hodgkin's lymphoma + NHL), DLBCL arising from CLL (Richter's transformation), or high-grade B-cell lymphoma.

**LEVEL 3 CRITERION:** \* Received strong cytochrome P450 3A (CYP3A) inhibitors  $\leq 7$  days prior to Day 1 dosing or strong CYP3A inducers  $\leq 14$  days prior to Day 1 dosing.

]

**Supplementary Table 3. LLM-structured eligibility criteria:** Selinexor (KPT-330) in Patients With Relapsed/Refractory Diffuse Large B-Cell Lymphoma (DLBCL). This table provides an example of structured eligibility criteria using GPT-4o. From high to low levels, the eligibility criteria are organized hierarchically, starting with separating inclusion and exclusion fields. Each field is then further divided into logical conditions and individual criteria. The criteria themselves can be either single conditions (Level 3) or nested criteria (Level 4). To achieve this structure, a strategy analogous to Disjunctive Normal Form (DNF) is employed, resulting in a hierarchical tree. Our results indicate that reasonable structuring can be achieved with two levels of nesting, although at the most granular level, single statements (conditions) could serve as the leaves, while all logical connectors (AND, OR, ALL, ANY) are placed as the edges. We will explore further optimization and refinement strategies of this approach in future iterations. Please note that the annotations (LEVEL X CRITERION and LOGIC) are only for readability purposes here, while the criteria hierarchy in reality is nested within the program code.

———— GPT-4o Eligibility criteria check for Trial NCT05254184 ————

**Inclusion Criteria:**

- ✔ Histologically- or cytologically-proven adenocarcinoma of the lung deemed to be locally advanced/unresectable or metastatic as per American Joint Committee on Cancer (AJCC) version 8, who has not received prior therapy for this stage of disease.

*(The patient has a histologically-proven adenocarcinoma of the lung, which is Stage IV and unresectable. The patient has not received prior therapy for this stage of the disease.)*

- ✔ • Prior therapy for early stage NSCLC allowed. Progressive disease after at least 6 months of anti-programmed death (PD) ligand therapy (anti-PD-L1 therapy) (i.e. Durvalumab) for Stage III disease is allowed.

*(There is no mention of prior therapy for early-stage NSCLC or anti-PD-L1 therapy.)*

- ✘ Must have tumor lesions amenable to repeated biopsy, and patient's acceptance to have a tumor biopsy of an accessible lesion at baseline and on treatment if the lesion can be biopsied with acceptable clinical risk (as judged by the Principal Investigator).

*(The patient has a tumor lesion that was biopsied, but there is no explicit mention of the patient's acceptance for repeated biopsies.)*

- ✔ Measurable disease as defined by RECIST v1.1.

*(The patient has a tumor size of approximately 4.7 cm in diameter, which is measurable.)*

- ✔ Have one of the six KRAS mutations (KRAS G12C, KRAS G12V, KRAS G12D, KRAS G12A, KRAS G13D or KRAS G12R) in vaccine expressed in tumor as defined by a Clinical Laboratory Improvement Amendments (CLIA) certified tumor or plasma based genomic testing platform performed either through a local laboratory or through the investigators' central laboratory.

*(The patient has a KRAS p.G13D mutation.)*

- ✔ Age ≥18 years.

*(The patient is older than 18 years.)*

- ✔ Eastern Cooperative Oncology Group (ECOG) performance status 0 or 1 (Appendix A).

*(The patient's ECOG performance status is 1, which meets the criterion.)*

- ✘ Women of childbearing potential (WOCBP) must have a negative serum pregnancy

test (minimum sensitivity 25 IU/L or equivalent units of human chorionic gonadotropin (HCG). WOCBP is defined in Section 4.6. Note: If a patient has a positive or indeterminate serum or urine pregnancy test, then an ultrasound must be done to rule out pregnancy to enroll on trial.

*(There is no information about a serum pregnancy test result.)*

🚫 WOCBP must agree to follow instructions for method(s) of contraception from the time of enrollment for the duration of treatment with study drug(s) plus 5 half-lives of study drug(s) plus 4 weeks (duration of ovulatory cycle) for a total of 5 months post treatment completion.

*(There is no information about the patient's agreement to follow contraception instructions.)*

✅ Men who are sexually active with WOCBP must agree to follow instructions for method(s) of contraception for the duration of treatment with study drug(s) plus 5 half-lives of study drug(s) plus 90 days (duration of sperm turnover) for a total of 7 months post-treatment completion.

*(The criterion is not applicable to the patient, so she effectively passes this criterion.)*

🚫 At least one barrier method of contraception must be employed by all sexually active patients (male and female), regardless of other methods, to prevent the transfer of body fluids.

*(There is no information provided about the patient's use of contraception or sexual activity.)*

🚫 Ability to understand and willingness to sign a written informed consent document.

*(There is no explicit information provided about the patient's cognitive ability or willingness to sign a consent document.)*

❌ Last dose of adjuvant chemotherapy or radiation therapy administered within 6 months of screening date

*(The patient has not received any initial treatment, including chemotherapy or radiation therapy.)*

✅ Patients must have adequate organ and marrow function as defined below:

*(Global condition: Patients must have adequate organ and marrow function as defined below.)*

✅ Microliters (mL) Microliter (uL)

*(Not a criterion that can be evaluated.)*

❌ Leukocytes  $\geq$  3,000/mcL

*(Patient's leukocytes: 2,700/mcL. This does not meet the criterion.)*

❌ Lymphocytes  $\geq$  500/mm<sup>3</sup>

*(Patient's lymphocytes: 438/mm<sup>3</sup>. This does not meet the criterion.)*

✓ Absolute neutrophil count  $\geq 1,000/\text{mcl}$

*(Patient's ANC: 1,200/mcl. This meets the criterion.)*

✓ Platelets  $\geq 75 \times 10^3/\text{uL}$

*(Patient's platelets:  $150 \times 10^3/\text{uL}$ . This meets the criterion.)*

✓ Hemoglobin  $\geq 8.0 \text{ g/dL}$

*(Patient's hemoglobin: 9.0 g/dL. This meets the criterion.)*

✓ Total bilirubin  $\leq 1.5 \times \text{ULN}$  ( $< 2.0 \times \text{ULN}$  for subjects with documented Gilbert's syndrome)

*(Patient's total bilirubin: 1.3 mg/dL. This meets the criterion.)*

✓ aspartate aminotransferase (AST) (SGOT) and alanine aminotransferase (ALT)(SGPT)  $\leq 2.5 \times \text{ULN}$  (if liver metastases are present,  $\leq 5 \times \text{ULN}$ )

*(Patient's AST: 50 U/L, ALT: 60 U/L. Both are within normal limits. This meets the criterion.)*

✓ Alkaline phosphatase  $\leq 5.0 \times \text{ULN}$

*(Patient's alkaline phosphatase: 200 U/L. This meets the criterion.)*

**Decision:** ✗

✓ Creatinine  $\leq 1.5 \times \text{ULN}$  or creatinine clearance (CrCl)  $\geq 40 \text{ mL/min}$  (if using the Cockcroft-Gault formula below):

*(The patient's creatinine level is 1.4 mg/dL, which is  $\leq 1.5 \times \text{ULN}$  (1.8 mg/dL).)*

👉 Female CrCl =  $(140 - \text{age in years}) \times \text{weight in kg} \times 0.85 / 72 \times \text{serum creatinine in mg/dL}$

*(The patient's weight is not provided, so we cannot calculate the creatinine clearance (CrCl).)*

✓ Male CrCl =  $(140 - \text{age in years}) \times \text{weight in kg} \times 1.00 / 72 \times \text{serum creatinine in mg/dL}$

*(This criterion is not applicable as the patient is female.)*

**Decision:** 👉

**Exclusion Criteria:**

- ✔ Patient is expected to require any other form of systemic or localized antineoplastic therapy while on study.

*(The patient has not started any treatment yet and there is no indication that she will require other forms of antineoplastic therapy while on the study.)*

- ✔ Patients with a history of prior treatment with immunotherapy agents (including, but not limited to: Interleukin 2 (IL-2), interferon, anti-PD-L2, anti-cluster of differentiation 137 (anti-CD137), anti-oxidation (OX) 40 (anti-OX-40), anti-cluster of differentiation 40 (anti-CD40), anti-cytotoxic T-lymphocyte-associated (CTLA) antigen 4 (anti-CTLA-4), or anti-lymphocyte activating gene (LAG) 3 (anti-LAG-3) antibodies).

*(There is no mention of the patient having received any prior immunotherapy agents.)*

- ✔ Prior anti-PD-(L)1 therapy for non-metastatic NSCLC (ie/Durvalumab) is allowed if patient had received at least 6 months of therapy prior to having disease progression.

*(There is no mention of the patient having received any prior anti-PD-(L)1 therapy.)*

- ✔ History of severe hypersensitivity reaction to any monoclonal antibodies or related compounds or to any of these agents' components (e.g., history of severe hypersensitivity reactions to drugs formulated with polysorbate 80).

*(There is no mention of any history of severe hypersensitivity reactions to monoclonal antibodies or related compounds.)*

- ✔ This includes any prior immunotherapy agents; patients having toxicity with prior anti-PD-L1 therapy requiring cessation of treatment must be excluded.

*(There is no mention of the patient having received any prior immunotherapy agents or having toxicity with prior anti-PD-L1 therapy.)*

- ✔ Untreated or symptomatic brain metastases.

*(The patient information does not mention brain metastases. Therefore, we assume the patient does not have brain metastases.)*

- ✔ Treated brain metastases allowed on study if asymptomatic and therapy was completed at least 2 weeks prior to treatment start, and steroid dosing is as 3.2.2

*(Since there is no mention of brain metastases, this criterion is not applicable.)*

- ✔ Has an active known or suspected autoimmune disease or which has required systemic therapy in the last 2 years. Subjects with type I diabetes mellitus, hypothyroidism only requiring hormone replacement, skin disorders (such as vitiligo, psoriasis, or alopecia) not requiring

systemic treatment, or conditions not expected to recur in the absence of an external trigger are permitted to enroll.

*(The patient has Type 2 Diabetes Mellitus, which is not an exclusion criterion. There is no mention of any other autoimmune disease.)*

✔ Known history of interstitial lung disease or of (non-infectious) pneumonitis that required steroids or current pneumonitis.

*(The patient has mild COPD but there is no mention of interstitial lung disease or pneumonitis.)*

✘ Has a pulse oximetry  $\leq$  90% on room air.

*(There is no information provided about the patient's pulse oximetry levels.)*

✔ Requires the use of home oxygen.

*(The patient information does not mention the use of home oxygen, so the patient is eligible.)*

✔ Has a known history of Human Immunodeficiency Virus (HIV) (HIV1/2 antibodies), hepatitis B, or hepatitis C infection.

*(The patient information does not mention any history of HIV, hepatitis B, or hepatitis C, so the patient is eligible.)*

✘ Uncontrolled intercurrent illness including, but not limited to, ongoing or active infection, symptomatic congestive heart failure, unstable angina, cardiac arrhythmia, metastatic cancer, or psychiatric illness that would limit compliance with study requirements.

*(The patient has metastatic cancer (Stage IV lung adenocarcinoma), so the patient is not eligible.)*

✔ Patients who have been diagnosed with another cancer or myeloproliferative disorder in the past 5 years except for superficial bladder cancer, non-melanoma skin cancers, or a low grade prostate cancer not requiring therapy.

*(The patient has not been diagnosed with another cancer or myeloproliferative disorder in the past 5 years, so the patient is eligible.)*

✔ Has a diagnosis of immunodeficiency.

*(The patient information does not mention any diagnosis of immunodeficiency, so the patient is eligible.)*

- ✔ Presence of any tissue or organ allograft, regardless of need for immunosuppression, including corneal allograft. Patients with a history of allogeneic hematopoietic stem cell transplant will be excluded.

*(The patient information does not mention any tissue or organ allograft or history of allogeneic hematopoietic stem cell transplant. Therefore, we assume the patient does not have any such history.)*

- ✘ Any other sound medical or psychiatric reason as determined by the Investigator.

*(This criterion is subjective and depends on the investigator's judgment. The patient has multiple comorbidities, but they are well-managed and not contraindicating any treatment. However, without the investigator's specific input, we cannot definitively decide.)*

- ✔ Patient is, at the time of signing informed consent, a regular user (including "recreational use") of any illicit drugs or other substance abuse (including alcohol) that could potentially interfere with adherence to study procedures or requirements.

*(The patient information does not mention any substance abuse or illicit drug use. Therefore, we assume the patient does not have any such history.)*

- ✘ Patient is unwilling or unable to follow the study schedule for any reason.

*(There is no information provided about the patient's willingness or ability to follow the study schedule. Therefore, we cannot make a definitive decision.)*

- ✔ Patient is pregnant or breastfeeding.

*(The patient is 56 years old, and there is no mention of pregnancy or breastfeeding in the provided information. Given the age and lack of information, it is highly unlikely that the patient is pregnant or breastfeeding.)*

- ✔ Any of the following procedures or medications:

*(Global condition: Any of the following procedures or medications.)*

- ✔ Within 2 weeks prior to initiation of study treatment:

*(Subcriterion 1: Within 2 weeks prior to initiation of study treatment. This sets the timeframe for the following specific exclusions.)*

- ✔ Systemic or topical corticosteroids at immunosuppressive doses ( $\gt$  10 mg/day of prednisone or equivalent). Inhaled or topical steroids, and adrenal replacement steroid doses  $\leq$  10 mg daily prednisone equivalent, are permitted in the absence of active autoimmune disease.

*(Subcriterion 2: Systemic or topical corticosteroids at immunosuppressive doses ( $>$  10 mg/day of prednisone or equivalent).*

*Inhaled or topical steroids, and adrenal replacement steroid doses  $\leq$  10 mg daily prednisone equivalent, are permitted in the absence of active autoimmune disease. The patient is not on systemic or topical corticosteroids at immunosuppressive doses.)*

**✓ Palliative or adjuvant radiation or gamma knife radiosurgery.**

*(Subcriterion 3: Palliative or adjuvant radiation or gamma knife radiosurgery. The patient has not undergone palliative or adjuvant radiation or gamma knife radiosurgery within the last 2 weeks.)*

**✓ Chemotherapy**

*(Subcriterion 4: Chemotherapy. The patient has not received any chemotherapy treatment.)*

**Decision: ✓**

**✓ Within 4 weeks prior to initiation of study treatment:**

*(The global condition applies to the following subcriteria.)*

**✓ Any investigational cytotoxic drug. Exposure to any cytotoxic drug within 4 weeks or 5 half-lives (whichever is shorter) is prohibited. If 5 half-lives are shorter than 4 weeks, agreement with Investigational New Drug (IND) Sponsor is mandatory.**

*(The patient is eligible as there is no evidence of exposure to investigational cytotoxic drugs.)*

**✓ Any investigational device**

*(The patient is eligible as there is no evidence of using investigational devices.)*

**✓ Non-oncology vaccines containing live virus. Examples include, but are not limited to, the following: measles, mumps, rubella, chicken pox, yellow fever, rabies, Bacillus Calmette-Guérin (BCG), and typhoid vaccine. Influenza, pneumonia vaccines (polysaccharide and conjugated forms) and Corona Virus Disease 2019 (COVID-19) vaccines will be allowed, however the investigators recommend that subjects not receive any dose of vaccine within 7 days before or after the subjects' scheduled KRAS peptide vaccination.**

*(The patient is eligible as there is no evidence of receiving non-oncology vaccines containing live virus.)*

**✓ Allergen hyposensitization therapy.**

*(The patient is eligible as there is no evidence of undergoing allergen hyposensitization therapy.)*



✔ Growth factors, e.g. granulocyte-colony stimulating factor (G-CSF), granulocyte macrophage-colony stimulating factor (GM-CSF), erythropoietin  
*(The patient is eligible as there is no evidence of receiving growth factors.)*

✔ Major surgery (excludes celiac plexus block, biliary stent placement, and other minor procedures such as dental work, skin biopsy, etc.).  
*(The patient is eligible as there is no evidence of undergoing major surgery.)*

**Decision:** ✔

**Supplementary Table 4. Fully evaluated clinical trial eligibility criteria for Patient 1.1.1.** This table presents the fully annotated (evaluated) eligibility criteria for the clinical trial “KRAS-Targeted Vaccine With Nivolumab and Ipilimumab for Patients With NSCLC” (NCT05254184) as determined by our model for patient 1.1.1 (see Supplementary Table 5). The shown trial is a single-institution, Phase 1 study aimed to evaluate the safety and feasibility of a mutant-KRAS peptide vaccine in combination with Nivolumab and Ipilimumab for the first-line treatment of patients with advanced stage III/IV unresectable KRAS-mutated non-small cell lung cancer, and to estimate progression-free survival and T cell responses in the peripheral blood. The model’s decisions are indicated on a single criterion level basis and include a final “Decision” statement whenever encountering a situation where multiple criteria are nested. Symbols denote patient eligibility (✔), ineligibility (✘), and insufficient information (👉). Gray italic text provides the model’s comments (reasoning) on its decision for each criterion. Note that we did not perform any attempts to optimize for the model’s outputs at this step, which could include referencing the patient’s EHR as source text or providing a more detailed chain of thought reasoning. Please also note that the order in which independent criteria are displayed here is not necessarily the same as on [clinicaltrials.gov](https://clinicaltrials.gov), which is a side effect of running evaluation across criteria in parallel to speed up the process.

## Survey for Trial NCT05254184

### Official Title

Pooled Mutant KRAS-Targeted Long Peptide Vaccine Combined With Nivolumab and Ipilimumab for Patients With Advanced KRAS Mutated Non-Small Cell Lung Cancer

### Brief Summary

This is a single institution, Phase 1 study for patients with Stage III/IV unresectable Kirsten rat sarcoma (KRAS) mutated NSCLC to evaluate safety of the pooled mutant-KRAS peptide vaccine (KRAS peptide vaccine) with polyinosinic-polycytidylic acid (poly-I:CLC) adjuvant in combination with nivolumab and ipilimumab in the first line treatment setting. The primary objectives of this study are to determine the safety and feasibility of administering the KRAS peptide vaccine with poly-I:CLC adjuvant in combination with nivolumab and ipilimumab. The secondary objectives are to estimate the progression free survival (PFS) of pooled mutant-KRAS long peptide vaccine with poly-I:CLC adjuvant in combination with ipilimumab + Nivolumab for the first line treatment of patients with unresectable Stage III/IV NSCLC whose tumors harbor selected KRAS mutations (KRAS glycine-to-cysteine substitution at codon 12 (G12C), KRAS glycine-to-valine substitution at codon 12 (G12V), KRAS glycine-to-Detoxoglyphosate substitution at codon 12 (G12D), KRAS glycine-to-arginine substitution at codon 12 (G12A), KRAS glycine-to-Aspartic Acid "D" at codon 13 (G13D) or KRAS G12R) and to assess the impact of predicted KRAS mutations on mutant-KRAS specific T cell responses in the peripheral blood of these patients. Exploratory objectives will assess the impact of predicted KRAS mutations on mutant-KRAS specific T cell responses in the peripheral blood, as well as changes in circulating tumor deoxyribonucleic acid (ctDNA). Approximately 15 subjects will be enrolled to have 12 evaluable subjects for T cell response assessment. Safety analysis will include all enrolled patients who receive at least one dose of vaccine. The evaluable population for T cell response will consist of all patients who receive at least one dose of vaccine and have baseline and post-treatment T cell measures in the peripheral blood at 12 weeks.

### Patient ID

1\_1\_mod\_2

### Patient Description

**Patient Information**  
Name: Emily Johnson  
Born: October 15, 1967  
Address: 5678 Maple Avenue, Springfield, IL, United States

**Overview of Tumor Diagnosis and Therapy**  
**Tumor Diagnosis**  
Diagnosis: Stage IV and unresectable lung adenocarcinoma, M+ (BRAIN); adenocarcinoma histology.  
Initial Detection: March 10, 2023, following persistent chest pain and dyspnea  
Biopsy Date: March 25, 2023  
Molecular Profile: KRAS p.G13D, TP53 p.A276G, PTPRS R238\*, ZFH3 p.F2994L, CDH1 p.D433N

**Therapy Overview**  
Initial Treatment: None  
Comorbidities: Well-managed and not contraindicating any treatment

**Comorbidities**  
Hyperlipidemia  
Osteoarthritis  
Gastroesophageal Reflux Disease (GERD)  
Iron deficiency anemia  
HIV

**Medication**  
Simvastatin 40mg once daily (0-0-1)  
Esomeprazole 20mg once daily (1-0-0)  
Ferrous sulfate one tablet daily (1-0-0)  
Biktarvy (1-0-0)

Performance Status: ECOG Performance Status 1

**Chronological Medical Findings:**  
January 15, 2020: Routine annual physical examination revealed elevated

Author:

Patients who meet all of the following criteria are eligible for trial participation:

#### Inclusion Criteria:

\* Histologically- or cytologically-proven adenocarcinoma of the lung deemed to be locally advanced/unresectable or metastatic as per American Joint Committee on Cancer (AJCC) version 8, who has not received prior therapy for this stage of disease.

Eligible Not Eligible ?

\* Prior therapy for early stage NSCLC allowed. Progressive disease after at least 6 months of anti-programmed death (PD) ligand therapy (anti-PD-L1 therapy) (i.e. Durvalumab) for Stage III disease is allowed.

Eligible Not Eligible ?

\* Must have tumor lesions amenable to repeated biopsy, and patient's acceptance to have a tumor biopsy of an accessible lesion at baseline and on treatment if the lesion can be biopsied with acceptable clinical risk (as judged by the Principal Investigator).

Eligible Not Eligible ?

\* Measurable disease as defined by RECIST v1.1.

Eligible Not Eligible ?

\* Have one of the six KRAS mutations (KRAS G12C, KRAS G12V, KRAS

**Supplementary Figure 1:** Web-based user interface for assessing trial eligibility criteria on a per patient basis. The top section shows the trial title and a free-text summary. On the left is the full text patient description. The right side features an interactive interface for selecting trial criteria.

**Supplementary Table 5. Clinical Cases EHRs.**

**Note:** Color highlighting is for illustration only, and not provided to the model.

===== Patient 1.1 =====

**Patient Information**

Name: Emily Johnson

Born: October 15, 1967

Address: 5678 Maple Avenue, Springfield, IL, United States

**Overview of Tumor Diagnosis and Therapy**

**Tumor Diagnosis**

Diagnosis: Stage IV and unresectable lung adenocarcinoma; adenocarcinoma histology, PD-L1

Initial Detection: March 10, 2023, following persistent chest pain and dyspnea

Biopsy Date: March 25, 2023

Molecular Profile: KRAS p.G13D, TP53 p.A276G, PTPRS R238\*, ZFH3 p.F2994L, CDH1 p.D433N

**Therapy Overview**

Initial Treatment: None

Comorbidities: Well-managed and not contraindicating any treatment

**Comorbidities**

Hyperlipidemia

Osteoarthritis

Gastroesophageal Reflux Disease (GERD)

Iron deficiency anemia

**Medication**

Simvastatin 40mg once daily (0-0-1)

Esomeprazole 20mg once daily (1-0-0)

Ferrous sulfate one tablet daily (1-0-0)

**Performance Status:** ECOG Performance Status 1

**Chronological Medical Findings:**

**January 15, 2020:** Routine annual physical examination revealed elevated blood pressure. Diagnosed with hypertension and prescribed Lisinopril 10 mg daily.

**March 20, 2020:** Complaints of frequent heartburn and acid reflux. Diagnosed with GERD and prescribed Esomeprazole 20 mg daily.

**February 5, 2021:** Follow-up for hypertension showed well-controlled blood pressure. Lisinopril dosage maintained.

**May 25, 2021:** Complained of knee pain and stiffness. Diagnosed with osteoarthritis. Recommended over-the-counter NSAIDs for pain management.

**April 15, 2022:** Routine check-up revealed elevated blood glucose levels. Diagnosed with Type 2 Diabetes Mellitus and prescribed Metformin 500 mg twice daily.

**August 10, 2022:** Routine cholesterol check indicated high cholesterol levels. Diagnosed with hyperlipidemia and prescribed Simvastatin 20 mg daily.

**November 15, 2022:** Follow-up for diabetes and hyperlipidemia. Dosages adjusted: Metformin increased to 1000 mg twice daily, Simvastatin increased to 40 mg daily.

**February 20, 2023:** Complained of shortness of breath and chronic cough. Diagnosed with mild COPD. Prescribed Salbutamol inhaler.

**July 10, 2023:** Routine follow-up showed stable condition with controlled comorbidities. Blood pressure, blood sugar, and cholesterol levels within target ranges.

**March 10, 2024:** Experienced persistent chest pain and shortness of breath. Chest X-ray and CT scan revealed a mass in the right lung.

**March 15, 2024:** CT Angiography, Pulmonary Arteries: Tumor Size: Approximately 4.7 cm in diameter. Bronchial Obstruction: Partial obstruction of the right main bronchus leading to atelectasis of the right upper lobe. Urgent suspicion of a tumor-atelectasis complex in the right upper lobe of the lung. Mucus present in the lower lobe bronchi on the right. Suspicion of mediastinal lymph node metastases. No evidence of pulmonary artery embolism. Lymph Nodes: Enlarged, FDG-positive lymph nodes in the mediastinum.

**March 25, 2024:** CT-guided lung biopsy: Diagnosed with non-small cell lung cancer (NSCLC), adenocarcinoma. Molecular diagnostics: KRAS p.G13D, TP53 p.A276G, PTPRS R238\*, ZFH3 p.F2994L, CDH1 p.D433N.

**April 20, 2024:** Detailed assessment of health status. ECOG performance status 1.

**April 21, 2024: Routine Lab:**

Leukocytes 4,200/mcL, Lymphocytes 600/mm<sup>3</sup>, Absolute Neutrophil Count (ANC) 1,200/mcL

Platelets 150 × 10<sup>3</sup>/uL

Hemoglobin 9.0 g/dL

Total Bilirubin 1.3 mg/dL

Aspartate Aminotransferase (AST) 50 U/L

Alanine Aminotransferase (ALT) 60 U/L

Alkaline Phosphatase 200 U/L

Creatinine 1.4 mg/dL

L-thyroxin (T4) 8.5 µg/dL  
Thyroid Stimulating Hormone (TSH) 2.0 µIU/mL  
Blood Glucose 90 mg/dL  
Cholesterol 180 mg/dL  
HCG within normal range.

**April 22, 2024:** Molecular tumor board: Recommendation for trial inclusion.

===== **Patient 1.1.1** =====

**Patient Information**

Name: Emily Johnson  
Born: October 15, 1967  
Address: 5678 Maple Avenue, Springfield, IL, United States

**Overview of Tumor Diagnosis and Therapy**

**Tumor Diagnosis**

Diagnosis: Stage IV and unresectable lung adenocarcinoma; adenocarcinoma histology, PD-L1  
Initial Detection: March 10, 2023, following persistent chest pain and dyspnea  
Biopsy Date: March 25, 2023  
Molecular Profile: KRAS p.G13D, TP53 p.A276G, PTPRS R238\*, ZFH3 p.F2994L, CDH1 p.D433N

**Therapy Overview**

Initial Treatment: None  
Comorbidities: Well-managed and not contraindicating any treatment

**Comorbidities**

Hyperlipidemia  
Osteoarthritis  
Gastroesophageal Reflux Disease (GERD)  
Iron deficiency anemia

**Medication**

Simvastatin 40mg once daily (0-0-1)  
Esomeprazole 20mg once daily (1-0-0)  
Ferrous sulfate one tablet daily (1-0-0)

**Performance Status:** ECOG Performance Status 1

**Chronological Medical Findings:**

**January 15, 2020:** Routine annual physical examination revealed elevated blood pressure. Diagnosed with hypertension and prescribed Lisinopril 10 mg daily.

**March 20, 2020:** Complaints of frequent heartburn and acid reflux. Diagnosed with GERD and prescribed Esomeprazole 20 mg daily.

**February 5, 2021:** Follow-up for hypertension showed well-controlled blood pressure. Lisinopril dosage maintained.

**May 25, 2021:** Complained of knee pain and stiffness. Diagnosed with osteoarthritis. Recommended over-the-counter NSAIDs for pain management.

**April 15, 2022:** Routine check-up revealed elevated blood glucose levels. Diagnosed with Type 2 Diabetes Mellitus and prescribed Metformin 500 mg twice daily.

**August 10, 2022:** Routine cholesterol check indicated high cholesterol levels. Diagnosed with hyperlipidemia and prescribed Simvastatin 20 mg daily.

**November 15, 2022:** Follow-up for diabetes and hyperlipidemia. Dosages adjusted: Metformin increased to 1000 mg twice daily, Simvastatin increased to 40 mg daily.

**February 20, 2023:** Complained of shortness of breath and chronic cough. Diagnosed with mild COPD. Prescribed Salbutamol inhaler.

**July 10, 2023:** Routine follow-up showed stable condition with controlled comorbidities. Blood pressure, blood sugar, and cholesterol levels within target ranges.

**March 10, 2024:** Experienced persistent chest pain and shortness of breath. Chest X-ray and CT scan revealed a mass in the right lung.

**March 15, 2024:** CT Angiography, Pulmonary Arteries: Tumor Size: Approximately 4.7 cm in diameter. Bronchial Obstruction: Partial obstruction of the right main bronchus leading to atelectasis of the right upper lobe. Urgent suspicion of a tumor-atelectasis complex in the right upper lobe of the lung. Mucus present in the lower lobe bronchi on the right. Suspicion of mediastinal lymph node metastases. No evidence of pulmonary artery embolism. Lymph Nodes: Enlarged, FDG-positive lymph nodes in the mediastinum.

**March 25, 2024:** CT-guided lung biopsy: Diagnosed with non-small cell lung cancer (NSCLC), adenocarcinoma. Molecular diagnostics: KRAS p.G13D, TP53 p.A276G, PTPRS R238\*, ZFH3 p.F2994L, CDH1 p.D433N.

**April 20, 2024:** Detailed assessment of health status. ECOG performance status 1.

**April 21, 2024: Routine Lab:**

Leukocytes 2,700/mcL, Lymphocytes 438/mm<sup>3</sup>, Absolute Neutrophil Count (ANC) 1,200/mcL

Platelets 150 × 10<sup>3</sup>/uL

Hemoglobin 9.0 g/dL

Total Bilirubin 1.3 mg/dL

Aspartate Aminotransferase (AST) 50 U/L

Alanine Aminotransferase (ALT) 60 U/L  
Alkaline Phosphatase 200 U/L  
Creatinine 1.4 mg/dL  
L-thyroxin (T4) 8.5 µg/dL  
Thyroid Stimulating Hormone (TSH) 2.0 µIU/mL  
Blood Glucose 90 mg/dL  
Cholesterol 180 mg/dL

HCG +++++

**April 22, 2024:** Molecular tumor board: Recommendation for trial inclusion.

===== Patient 1.1.2 =====

**Patient Information**

Name: Emily Johnson  
Born: October 15, 1967  
Address: 5678 Maple Avenue, Springfield, IL, United States

**Overview of Tumor Diagnosis and Therapy**

**Tumor Diagnosis**

Diagnosis: Stage IV and unresectable lung adenocarcinoma, M+ (BRAIN); adenocarcinoma histology,

Initial Detection: March 10, 2023, following persistent chest pain and dyspnea  
Biopsy Date: March 25, 2023  
Molecular Profile: KRAS p.G13D, TP53 p.A276G, PTPRS R238\*, ZFH3 p.F2994L, CDH1 p.D433N

**Therapy Overview**

Initial Treatment: None  
Comorbidities: Well-managed and not contraindicating any treatment

**Comorbidities**

Hyperlipidemia  
Osteoarthritis  
Gastroesophageal Reflux Disease (GERD)  
Iron deficiency anemia

HIV

## Medication

Simvastatin 40mg once daily (0-0-1)

Esomeprazole 20mg once daily (1-0-0)

Ferrous sulfate one tablet daily (1-0-0)

Biktarvy (1-0-0)

**Performance Status:** ECOG Performance Status 1

## Chronological Medical Findings:

**January 15, 2020:** Routine annual physical examination revealed elevated blood pressure. Diagnosed with hypertension and prescribed Lisinopril 10 mg daily.

**March 20, 2020:** Complaints of frequent heartburn and acid reflux. Diagnosed with GERD and prescribed Esomeprazole 20 mg daily.

**February 5, 2021:** Follow-up for hypertension showed well-controlled blood pressure. Lisinopril dosage maintained.

**May 25, 2021:** Complained of knee pain and stiffness. Diagnosed with osteoarthritis. Recommended over-the-counter NSAIDs for pain management.

**April 15, 2022:** Routine check-up revealed elevated blood glucose levels. Diagnosed with Type 2 Diabetes Mellitus and prescribed Metformin 500 mg twice daily.

**August 10, 2022:** Routine cholesterol check indicated high cholesterol levels. Diagnosed with hyperlipidemia and prescribed Simvastatin 20 mg daily.

**November 15, 2022:** Follow-up for diabetes and hyperlipidemia. Dosages adjusted: Metformin increased to 1000 mg twice daily, Simvastatin increased to 40 mg daily.

**February 20, 2023:** Complained of shortness of breath and chronic cough. Diagnosed with mild COPD. Prescribed Salbutamol inhaler.

**July 10, 2023:** Routine follow-up showed stable condition with controlled comorbidities. Blood pressure, blood sugar, and cholesterol levels within target ranges.

**March 10, 2024:** Experienced persistent chest pain and shortness of breath. Chest X-ray and CT scan revealed a mass in the right lung.

**March 15, 2024:** CT Angiography, Pulmonary Arteries: Tumor Size: Approximately 4.7 cm in diameter. Bronchial Obstruction: Partial obstruction of the right main bronchus leading to atelectasis of the right upper lobe. Urgent suspicion of a tumor-atelectasis complex in the right upper lobe of the lung. Mucus present in the lower lobe bronchi on the right. Suspicion of mediastinal lymph node metastases. No evidence of pulmonary artery embolism. Lymph Nodes: Enlarged, FDG-positive lymph nodes in the mediastinum.

**March 20, 2024:** MRI-Brain: three metastatic lesions consistent with primary lung cancer. Lesions are located in the left frontal lobe, left parietal lobe, and



left occipital lobe, measuring 1.2 cm, 1.5 cm, and 1.8 cm in diameter, respectively.

Surrounding vasogenic edema is noted, causing mild mass effect on adjacent

brain structures. No evidence of hemorrhage or hydrocephalus observed.

**March 25, 2024:** CT-guided lung biopsy: Diagnosed with non-small cell lung cancer (NSCLC), adenocarcinoma. Molecular diagnostics: KRAS p.G13D, TP53 p.A276G, PTPRS R238\*, ZFH3 p.F2994L, CDH1 p.D433N.

**April 20, 2024:** Detailed assessment of health status. ECOG performance status 1.

**April 21, 2024: Routine Lab:**

Leukocytes 4,200/mcL, Lymphocytes 600/mm<sup>3</sup>, Absolute Neutrophil Count (ANC) 1,200/mcL

Platelets 150 × 10<sup>3</sup>/uL

Hemoglobin 9.0 g/dL

Total Bilirubin 1.3 mg/dL

Aspartate Aminotransferase (AST) 50 U/L

Alanine Aminotransferase (ALT) 60 U/L

Alkaline Phosphatase 200 U/L

Creatinine 1.4 mg/dL

L-thyroxin (T4) 8.5 µg/dL

Thyroid Stimulating Hormone (TSH) 2.0 µIU/mL

Blood Glucose 90 mg/dL

Cholesterol 180 mg/dL

HCG within normal range.

SO<sub>2</sub> (room air) 87%

**April 22, 2024:** Molecular tumor board: Recommendation for trial inclusion.

===== **Patient 2.1** =====

#### **Patient Information**

Name: Sarah Mitchell

Born: June 12, 1998

Address: 8765 Pine Street, Springfield, IL

#### **Overview of Tumor Diagnosis and Therapy**

##### **Tumor Diagnosis**

Diagnosis: Stage IV urachal adenocarcinoma; m+ (LYM, PULMONARY)

Initial Detection: January 18, 2024, following persistent hematuria and abdominal

discomfort

Biopsy Date: January 28, 2024

Molecular Profile: KRAS p.G12V, BCORL p.R1332\*, TP53 p.H214fs7, *CDKN2C* p.L65F, *MAP3K1* p.T949\_E950insT, *MYCN* p.E47fs8, CTNNA1 p.K577\_L578>TKL, JAK1 p.I597M, FANCL p.T367fs\*12+, PIK3CA amplification (n>6), MYC amplification (n>6), MYCL1 amplification (n>6), SOX2 amplification (n>6), MUTYH amplification (n>6)

### Therapy Overview

Chemotherapy: Began February 1 - April 22, 2024 (Cisplatin + 5-FU)

### Comorbidities

Seasonal Allergies

### Medication

Cetirizine 10mg as needed

**Performance Status:** ECOG Performance Status 1

### Chronological Medical Findings:

**January 18, 2024:** Presented with hematuria and abdominal discomfort. Abdominal ultrasound revealed a mass in the bladder dome.

**January 22, 2024:** CT scan abdomen/pelvis: Mass located at the bladder dome, measuring approximately 3.0 cm in diameter. Evidence of local invasion into surrounding structures + several enlarged local lymph nodes are noted, with the largest lymph node located near the pelvic sidewall, measuring 1.5 cm.

Chest CT scan: Multiple metastatic lesions are present in both lungs. The largest metastasis is located peripherally in the left lung and measures approximately 3.1 cm in diameter. Other smaller metastatic nodules scattered throughout both lung fields.

**January 28, 2024:** Multiple Biopsies of bladder (CT-guided): Histology confirmed urachal adenocarcinoma. Molecular panel sequencing revealed mutations: KRAS p.G12V, BCORL p.R1332\*, TP53 p.H214fs7, *CDKN2C* p.L65F, *MAP3K1* p.T949\_E950insT, *MYCN* p.E47fs8, CTNNA1 p.K577\_L578>TKL, JAK1 p.I597M, FANCL p.T367fs\*12+, PIK3CA amplification (n>6), MYC amplification (n>6), MYCL1 amplification (n>6), SOX2 amplification (n>6), MUTYH amplification (n>6).

**February 1, 2024:** Initiated chemotherapy with Cisplatin + 5-FU.

**April 23, 2024:** CT scan abdomen/pelvis: Mass located at the bladder dome, now measuring approximately 4.5 cm in diameter. Increased evidence of local invasion into surrounding structures. Several enlarged local lymph nodes are noted, with the largest lymph node located near the pelvic sidewall, now measuring 2.0 cm. Chest CT scan:

Increased number and size of metastatic lesions in both lungs. The largest metastasis is located peripherally in the left lung and now measures approximately 4.0 cm in diameter. Numerous other metastatic nodules, with some showing an increase in size, are scattered throughout both lung fields.

**April 25, 2024:** Detailed assessment of health status confirmed adequate organ function. Routine labs within normal limits: ANC 4,500/mcL, platelet count 250,000/mcL, total bilirubin 0.8 mg/dL, AST/ALT within normal limits, creatinine 0.8 mg/dL, hemoglobin 14.0 g/dL, serum albumin 4.0 g/dL, lipase and amylase within normal limits. Serum HCG test negative.

**April 28, 2024:** Tumor board review recommended considering eligibility for clinical trials due to limited response to standard and investigational therapies. Patient in good clinical condition, willing to participate in a trial.

===== Patient 2.1.1 =====

**Patient Information**

Name: Sarah Mitchell  
Born: June 12, 1998  
Address: 8765 Pine Street, Springfield, IL

**Overview of Tumor Diagnosis and Therapy**

**Tumor Diagnosis**

Diagnosis: Stage IV urachal adenocarcinoma; m+ (LYM, PULMONARY)  
Initial Detection: January 18, 2024, following persistent hematuria and abdominal discomfort  
Biopsy Date: January 28, 2024  
Molecular Profile: KRAS p.G12V, BCORL p.R1332\*, TP53 p.H214fs7, *CDKN2C* p.L65F, *MAP3K1* p.T949\_E950insT, *MYCN* p.E47fs8, CTNNA1 p.K577\_L578>TKL, JAK1 p.I597M, FANCL p.T367fs\*12+, PIK3CA amplification (n>6), MYC amplification (n>6), MYCL1 amplification (n>6), SOX2 amplification (n>6), MUTYH amplification (n>6)

**Therapy Overview**

Chemotherapy: Began February 1 - April 22, 2024 (Cisplatin + 5-FU)

**Comorbidities**

Seasonal Allergies

Platin-induced Neuropathy (April 2024)

**Medication**

Cetirizine 10mg as needed

**Performance Status:** ECOG Performance Status 1

**Chronological Medical Findings:**

**January 18, 2024:** Presented with hematuria and abdominal discomfort. Abdominal ultrasound revealed a mass in the bladder dome.

**January 22, 2024:** CT scan abdomen/pelvis: Mass located at the bladder dome, measuring approximately 3.0 cm in diameter. Evidence of local invasion into surrounding structures + several enlarged local lymph nodes are noted, with the largest lymph node located near the pelvic sidewall, measuring 1.5 cm.

Chest CT scan: Multiple metastatic lesions are present in both lungs. The largest metastasis is located peripherally in the left lung and measures approximately 3.1 cm in diameter. Other smaller metastatic nodules scattered throughout both lung fields.

**January 28, 2024:** Multiple Biopsies of bladder (CT-guided): Histology confirmed urachal adenocarcinoma. Molecular panel sequencing revealed mutations: KRAS p.G12V, BCORL p.R1332\*, TP53 p.H214fs7, *CDKN2C* p.L65F, *MAP3K1* p.T949\_E950insT, *MYCN* p.E47fs8, CTNNA1 p.K577\_L578>TKL, JAK1 p.I597M, FANCL p.T367fs\*12+, PIK3CA amplification (n>6), MYC amplification (n>6), MYCL1 amplification (n>6), SOX2 amplification (n>6), MUTYH amplification (n>6).

**February 1, 2024:** Initiated chemotherapy with Cisplatin + 5-FU.

Chemotherapy abrogated before completion of the last cycle due to severe neuropathy limiting daily activities.

**April 23, 2024:** CT scan abdomen/pelvis: Mass located at the bladder dome, now measuring approximately 4.5 cm in diameter. Increased evidence of local invasion into surrounding structures. Several enlarged local lymph nodes are noted, with the largest lymph node located near the pelvic sidewall, now measuring 2.0 cm. Chest CT scan: Increased number and size of metastatic lesions in both lungs. The largest metastasis is located peripherally in the left lung and now measures approximately 4.0 cm in diameter. Numerous other metastatic nodules, with some showing an increase in size, are scattered throughout both lung fields.

cMRI: 1 single brain metastasis in the frontal lobe.

**April 25, 2024:** Detailed assessment of health status confirmed adequate organ function. Routine labs within normal limits: ANC 4,500/mcL, platelet count 250,000/mcL, total bilirubin 0.8 mg/dL, AST/ALT within normal limits, creatinine 0.8 mg/dL, hemoglobin 14.0 g/dL, serum albumin 4.0 g/dL, lipase and amylase within normal limits. Serum HCG test negative.

**April 28, 2024:** Tumor board review recommended considering eligibility for clinical trials due to limited response to standard and investigational therapies.

Patient in overall good clinical condition, however persistent neuropathy (no improvements). She is willing to participate in clinical trials.

===== Patient 2.1.2 =====

**Patient Information**

Name: Sarah Mitchell  
Born: June 12, 1998  
Address: 8765 Pine Street, Springfield, IL

**Overview of Tumor Diagnosis and Therapy**

**Tumor Diagnosis**

Diagnosis: Stage IV urachal adenocarcinoma; m+ (LYM, PULMONARY)  
Initial Detection: January 18, 2024, following persistent hematuria and abdominal discomfort  
Biopsy Date: January 28, 2024  
Molecular Profile: KRAS p.G12V, BCORL p.R1332\*, TP53 p.H214fs7, *CDKN2C* p.L65F, *MAP3K1* p.T949\_E950insT, *MYCN* p.E47fs8, CTNNA1 p.K577\_L578>TKL, JAK1 p.I597M, FANCL p.T367fs\*12+, PIK3CA amplification (n>6), MYC amplification (n>6), MYCL1 amplification (n>6), SOX2 amplification (n>6), MUTYH amplification (n>6)

**Therapy Overview**

Chemotherapy: Began February 1 - April 22, 2024 (Cisplatin + 5-FU)

**Comorbidities**

Diabetes type II

Seasonal Allergies

**Medication**

Cetirizine 10mg as needed  
Ceftriaxone 1g 1-0-0  
Metformin 500mg BID (paused)  
Glyburide 5mg BID (paused)  
Insulin under monitoring

**Performance Status:** ECOG Performance Status 1

**Chronological Medical Findings:**

**January 18, 2024:** Presented with hematuria and abdominal discomfort. Abdominal ultrasound revealed a mass in the bladder dome.

**January 22, 2024:** CT scan abdomen/pelvis: Mass located at the bladder dome, measuring approximately 3.0 cm in diameter. Evidence of local invasion into surrounding structures + several enlarged local lymph nodes are noted, with the largest lymph node located near the pelvic sidewall, measuring 1.5 cm.

Chest CT scan: Multiple metastatic lesions are present in both lungs. The largest metastasis is located peripherally in the left lung and measures approximately 3.1 cm in diameter. Other smaller metastatic nodules scattered throughout both lung fields.

**January 28, 2024:** Multiple Biopsies of bladder (CT-guided): Histology confirmed urachal adenocarcinoma. Molecular panel sequencing revealed mutations: KRAS p.G12V, BCORL p.R1332\*, TP53 p.H214fs7, *CDKN2C* p.L65F, *MAP3K1* p.T949\_E950insT, *MYCN* p.E47fs8, CTNNA1 p.K577\_L578>TKL, JAK1 p.I597M, FANCL p.T367fs\*12+, PIK3CA amplification (n>6), MYC amplification (n>6), MYCL1 amplification (n>6), SOX2 amplification (n>6), MUTYH amplification (n>6).

**February 1, 2024:** Initiated chemotherapy with Cisplatin + 5-FU.

**April 23, 2024:** CT scan abdomen/pelvis: Mass located at the bladder dome, now measuring approximately 4.5 cm in diameter. Increased evidence of local invasion into surrounding structures. Several enlarged local lymph nodes are noted, with the largest lymph node located near the pelvic sidewall, now measuring 2.0 cm. Chest CT scan: Increased number and size of metastatic lesions in both lungs. The largest metastasis is located peripherally in the left lung and now measures approximately 4.0 cm in diameter. Numerous other metastatic nodules, with some showing an increase in size, are scattered throughout both lung fields.

**April 25, 2024:** Detailed assessment of health status confirmed adequate organ function. Routine labs within normal limits: ANC 4,500/mcL, platelet count 250,000/mcL, total bilirubin 0.8 mg/dL, AST/ALT within normal limits, creatinine 0.8 mg/dL, hemoglobin 14.0 g/dL, serum albumin 4.0 g/dL, lipase and amylase within normal limits. Serum HCG test negative.

**April 28, 2024:** Tumor board review recommended considering eligibility for clinical trials due to limited response to standard and investigational therapies. Patient in good clinical condition, willing to participate in a trial.

**May 1, 2024:** Patient presents with fever, flank pain, and dysuria.

Hospitalized for further evaluation and treatment.

Ultrasound: Enlarged kidney with signs of

inflammation, consistent with pyelonephritis.

Blood culture: Pending. Urine culture: Pending. Started on IV antibiotics:

Ceftriaxone 1g. CRP: 15 mg/dL. Leukocytes: 18,000/mcL. HbA1c 8.3%.

Paused Metformin/Glyburide, started on insulin with close monitoring

===== Patient 2.2 =====

#### Patient Information

Name: Sarah Mitchell

Born: June 12, 1998  
Address: 8765 Pine Street, Springfield, IL

## Overview of Tumor Diagnosis and Therapy

### Tumor Diagnosis

Diagnosis: Stage IV urachal adenocarcinoma; m+ (LYM, PULMONARY)

Initial Detection: January 18, 2024, following persistent hematuria and abdominal discomfort

Biopsy Date: January 28, 2024

Molecular Profile: KRAS p.G12V, BCORL p.R1332\*, TP53 p.H214fs7, *CDKN2C* p.L65F, *MAP3K1* p.T949\_E950insT, *MYCN* p.E47fs8, CTNNA1 p.K577\_L578>TKL, JAK1 p.I597M, FANCL p.T367fs\*12+, PIK3CA amplification (n>6), MYC amplification (n>6), MYCL1 amplification (n>6), SOX2 amplification (n>6), MUTYH amplification (n>6)

### Therapy Overview

Chemotherapy: Began February 1 - April 22, 2024 (Cisplatin + 5-FU)

### Comorbidities

Seasonal Allergies

### Medication

Cetirizine 10mg as needed

**Performance Status:** ECOG Performance Status 1

### Chronological Medical Findings:

**January 18, 2024:** Presented with hematuria and abdominal discomfort. Abdominal ultrasound revealed a mass in the bladder dome.

**January 22, 2024:** CT scan abdomen/pelvis: Mass located at the bladder dome, measuring approximately 3.0 cm in diameter. Evidence of local invasion into surrounding structures + several enlarged local lymph nodes are noted, with the largest lymph node located near the pelvic sidewall, measuring 1.5 cm.

Chest CT scan: Multiple metastatic lesions are present in both lungs. The largest metastasis is located peripherally in the left lung and measures approximately 3.1 cm in diameter. Other smaller metastatic nodules scattered throughout both lung fields.

**January 28, 2024:** Multiple Biopsies of bladder (CT-guided): Histology confirmed urachal adenocarcinoma. Molecular panel sequencing revealed mutations: KRAS p.G12V, BCORL p.R1332\*, TP53 p.H214fs7, *CDKN2C* p.L65F, *MAP3K1*

*p.T949\_E950insT*, *MYCN p.E47fs8*, CTNNA1 p.K577\_L578>TKL, JAK1 p.I597M, FANCL p.T367fs\*12+, PIK3CA amplification (n>6), MYC amplification (n>6), MYCL1 amplification (n>6), SOX2 amplification (n>6), MUTYH amplification (n>6).

**February 1, 2024:** Initiated chemotherapy with Cisplatin + 5-FU.

**April 23, 2024:** CT scan abdomen/pelvis: Mass located at the bladder dome, now measuring approximately 4.5 cm in diameter. Increased evidence of local invasion into surrounding structures. Several enlarged local lymph nodes are noted, with the largest lymph node located near the pelvic sidewall, now measuring 2.0 cm. Chest CT scan: Increased number and size of metastatic lesions in both lungs. The largest metastasis is located peripherally in the left lung and now measures approximately 4.0 cm in diameter. Numerous other metastatic nodules, with some showing an increase in size, are scattered throughout both lung fields.

**April 25, 2024:** Detailed assessment of health status confirmed adequate organ function. Routine labs within normal limits: ANC 4,500/mcL, platelet count 250,000/mcL, total bilirubin 0.8 mg/dL, AST/ALT within normal limits, creatinine 0.8 mg/dL, hemoglobin 14.0 g/dL, serum albumin 4.0 g/dL, lipase and amylase within normal limits. Serum HCG test negative.

**April 28, 2024:** Tumor board review recommended considering eligibility for clinical trials due to limited response to standard and investigational therapies. Patient in good clinical condition, willing to participate in a trial.

===== Patient 2.2.1 =====

**Patient Information**

Name: Sarah Mitchell  
Born: June 12, 1998  
Address: 8765 Pine Street, Springfield, IL

**Overview of Tumor Diagnosis and Therapy**

**Tumor Diagnosis**

Diagnosis: Stage IV urachal adenocarcinoma; m+ (LYM, PULMONARY)  
Initial Detection: January 18, 2024, following persistent hematuria and abdominal discomfort  
Biopsy Date: January 28, 2024  
Molecular Profile: KRAS p.G12V, BCORL p.R1332\*, TP53 p.H214fs7, *CDKN2C p.L65F*, *MAP3K1 p.T949\_E950insT*, *MYCN p.E47fs8*, CTNNA1 p.K577\_L578>TKL, JAK1 p.I597M, FANCL p.T367fs\*12+, PIK3CA amplification (n>6), MYC amplification (n>6), MYCL1 amplification (n>6), SOX2 amplification (n>6), MUTYH amplification (n>6)

**Therapy Overview**

Chemotherapy: Began February 1 - April 22, 2024 (Cisplatin + 5-FU)



## Comorbidities

Seasonal Allergies

Recurrent gastrointestinal bleedings due to tumor infiltration of the rectum, requiring transfusions

## Medication

Cetirizine 10mg as needed

**Performance Status:** ECOG Performance Status 1

## Chronological Medical Findings:

**January 18, 2024:** Presented with hematuria and abdominal discomfort. Abdominal ultrasound revealed a mass in the bladder dome.

**January 22, 2024:** CT scan abdomen/pelvis: Mass located at the bladder dome, measuring approximately 3.0 cm in diameter. Evidence of local invasion into surrounding structures + several enlarged local lymph nodes are noted, with the largest lymph node located near the pelvic sidewall, measuring 1.5 cm.

Chest CT scan: Multiple metastatic lesions are present in both lungs. The largest metastasis is located peripherally in the left lung and measures approximately 3.1 cm in diameter. Other smaller metastatic nodules scattered throughout both lung fields.

**January 28, 2024:** Multiple Biopsies of bladder (CT-guided): Histology confirmed urachal adenocarcinoma. Molecular panel sequencing revealed mutations: KRAS p.G12V, BCORL p.R1332\*, TP53 p.H214fs7, *CDKN2C* p.L65F, *MAP3K1* p.T949\_E950insT, *MYCN* p.E47fs8, CTNNA1 p.K577\_L578>TKL, JAK1 p.I597M, FANCL p.T367fs\*12+, PIK3CA amplification (n>6), MYC amplification (n>6), MYCL1 amplification (n>6), SOX2 amplification (n>6), MUTYH amplification (n>6).

**February 1, 2024:** Initiated chemotherapy with Cisplatin + 5-FU.

**April 23, 2024:** CT scan abdomen/pelvis: Mass located at the bladder dome, now measuring approximately 4.5 cm in diameter. **Rectal tumor invasion.** Increased evidence of local invasion into surrounding structures. Several enlarged local lymph nodes are noted, with the largest lymph node located near the pelvic sidewall, now measuring 2.0 cm. Chest CT scan: Increased number and size of metastatic lesions in both lungs. The largest metastasis is located peripherally in the left lung and now measures approximately 4.0 cm in diameter. Numerous other metastatic nodules, with some showing an increase in size, are scattered throughout both lung fields.

**April 25, 2024:** Detailed assessment of health status confirmed adequate organ function. Routine labs within normal limits: ANC 4,500/mcL, platelet count 250,000/mcL, total bilirubin 0.8 mg/dL, AST/ALT within normal limits, creatinine 0.8 mg/dL, hemoglobin 8.4 g/dL

(due to recurrent GI bleedings), serum albumin 4.0 g/dL, lipase and amylase within normal limits. Serum HCG test negative.

**April 28, 2024:** Tumor board review recommended considering eligibility for clinical trials due to limited response to standard and investigational therapies. Patient in good clinical condition, willing to participate in a trial.

===== Patient 3.1 =====

**Patient Information**

Name: Thomas Meyer  
Born: January 12, 1966  
Address: Schlossallee 1, Dresden, Germany

**Overview of Tumor Diagnosis and Therapy**

**Tumor Diagnosis**

Diagnosis: Masaoka-Koga Stage IVb thymic adenocarcinoma (metastases to the lungs, liver and spines T6, T9, L3)

Initial Detection: March 15, 2023, following persistent chest pain and cough, shortness-of-breath

Biopsy Date: March 28, 2023

Molecular Profile: Germline: BRCA2 p.K3326\* (1N); Tumor: SMAD4 p.C363R (1N), TP53 p.305fs (2N\_LOH), CDKN1B p.K100N (2N\_LOH), ATM p.E1666\* (4N), MAP3K8 p.H236Y (1N), TRAF1 p.R70H (2N), HDAC2 p.R409\* (1N), TMEM111-TDRD3 fusion, PRKDC-CDH17 fusion, EXT1-MAGI2 fusion; Overexpressed genes: ERBB2, ERBB3, PDGFRB, TGFA, EGF, FGFR3, MET.

**Therapy Overview**

Initial Treatment:

Chemotherapy: Began April 5, 2023, with combination of Doxorubicin, Cisplatin, Vincristine and Cyclophosphamide (ADOC). Partial response after the initial two chemotherapy cycles completed by June, 2023. Continued chemotherapy until November 2023 (progressive disease).

Subsequent Treatment: Second-line treatment with Carboplatin plus Paclitaxel starting Nov 24, 2023. Current Status: Disease progression as of May 2024, with new metastatic lesions in the lungs.

**Comorbidities**

- Former Smoker 25 py
- Hypertension Stage 2
- Type 2 Diabetes Mellitus
- Hyperlipidemia
- Gastroesophageal Reflux Disease (GERD)
- H/o cholecystectomy 2011

## Medication

Losartan 50mg once daily  
HCT 12.5mg once daily  
Metformin 1000mg once daily  
Atorvastatin 40mg once daily  
Omeprazole 20mg once daily  
XGEVA

**Performance Status:** ECOG Performance Status 1

### Chronological Medical Findings:

**March 15, 2023:** Presented with persistent chest pain and cough and SOB.

**March 20, 2023:** CT scan of the chest: Mass in the anterior mediastinum measuring approximately 6.0 cm with evidence of local invasion into surrounding structures. Multiple pulmonary nodules suggestive of metastasis.

**March 28, 2023:** CT-guided biopsy of mediastinal mass. Histology confirmed thymic adenocarcinoma. Whole exome sequencing revealed germline mutation BRCA2 p.K3326\*, tumor mutations: SMAD4 p.C363R, TP53 p.305fs, CDKN1B p.K100N, ATM p.E1666\*, MAP3K8 p.H236Y, TRAF1 p.R70H, HDAC2 p.R409\*, TMEM111-TDRD3 fusion, PRKDC-CDH17 fusion, EXT1-MAGI2 fusion. Overexpressed genes: ERBB2, ERBB3, PDGFRB, TGFA, EGF, FGFR3, MET.

**April 5, 2023:** Initiated chemotherapy with Doxorubicin, Cisplatin, Vincristine and Cyclophosphamide (ADOC). Patient in sophisticated conditions, first therapy today.

**June 20, 2023:** Follow-up CT scan showed partial response with a decrease in the size of the primary tumor and pulmonary nodules. Continued chemotherapy regimen.

**November 15, 2023:** Follow-up imaging CT chest/abdomen: disease progression with new metastatic lesions. Multiple hepatic lesions, with the largest lesion in segment VIII measuring 4.5 cm, and another lesion in segment II measuring 3.0 cm. Bone scan indicates metastatic involvement of the spine, with lesions identified at T6, T9, and L3 vertebrae. Additional findings include new pulmonary nodules and further enlargement of the primary mass in the anterior mediastinum.

**November 24, 2023:** Started second-line therapy with Carboplatin plus Paclitaxel.

**March 10, 2024:** Follow-up CT scan: PD. Progression of disease with increased size of liver metastases and new bone lesions.

**May 20, 2024:** Tumor board review recommended considering eligibility for clinical trials due to limited response to standard and investigational therapies.

**June 1, 2024:** Detailed assessment of health status confirmed adequate organ function. All routine labs within normal limits.

===== **Patient 3.1.1**=====

### **Patient Information**

Name: Thomas Meyer

Born: January 12, 1966

Address: Schlossallee 1, Dresden, Germany

### **Overview of Tumor Diagnosis and Therapy**

#### **Tumor Diagnosis**

Diagnosis: Masaoka-Koga Stage IVb thymic adenocarcinoma (metastases to the lungs, liver and spines T6, T9, L3)

Initial Detection: March 15, 2023, following persistent chest pain and cough, shortness-of-breath

Biopsy Date: March 28, 2023

Molecular Profile: Germline: BRCA2 p.K3326\* (1N); Tumor: SMAD4 p.C363R (1N), TP53 p.305fs (2N\_LOH), CDKN1B p.K100N (2N\_LOH), ATM p.E1666\* (4N), MAP3K8 p.H236Y (1N), TRAF1 p.R70H (2N), HDAC2 p.R409\* (1N), TMEM111-TDRD3 fusion, PRKDC-CDH17 fusion, EXT1-MAGI2 fusion; Overexpressed genes: ERBB2, ERBB3, PDGFRB, TGFA, EGF, FGFR3, MET.

#### **Therapy Overview**

Initial Treatment:

Chemotherapy: Began April 5, 2023, with combination of Doxorubicin, Cisplatin, Vincristine and Cyclophosphamide (ADOC). Partial response after the initial two chemotherapy cycles completed by June, 2023. Continued chemotherapy until November 2023 (progressive disease).

Subsequent Treatment: Second-line treatment with Carboplatin plus Paclitaxel starting Nov 24, 2023. Current Status: Disease progression as of May 2024, with new metastatic lesions in the lungs.

#### **Comorbidities**

Former Smoker 25 py

Interstitial Lung disease (ILD)

Hypertension Stage 2

Type 2 Diabetes Mellitus

Hyperlipidemia

Gastroesophageal Reflux Disease (GERD)

H/o cholecystectomy 2011

#### **Medication**

Prednisone 10mg 1x

Losartan 50mg once daily

HCT 12.5mg once daily

Metformin 1000mg 1x/d

Atorvastatin 40mg once daily

Omeprazole 20mg daily  
XGEVA q4w

**Performance Status:** ECOG Performance Status 1

**Chronological Medical Findings:**

**March 15, 2023:** Presented with persistent chest pain and cough and SOB.

**March 20, 2023:** CT scan of the chest: Mass in the anterior mediastinum measuring approximately 6.0 cm with evidence of local invasion into surrounding structures. Multiple pulmonary nodules suggestive of metastasis. Evidence of known Interstitial Lung Disease (ILD) with diffuse interstitial markings and fibrosis.

**March 28, 2023:** CT-guided biopsy of mediastinal mass. Histology confirmed thymic adenocarcinoma. Whole exome sequencing revealed germline mutation BRCA2 p.K3326\*, tumor mutations: SMAD4 p.C363R, TP53 p.305fs, CDKN1B p.K100N, ATM p.E1666\*, MAP3K8 p.H236Y, TRAF1 p.R70H, HDAC2 p.R409\*, TMEM111-TDRD3 fusion, PRKDC-CDH17 fusion, EXT1-MAGI2 fusion. Overexpressed genes: ERBB2, ERBB3, PDGFRB, TGFA, EGF, FGFR3, MET.

**April 5, 2023:** Initiated chemotherapy with Doxorubicin, Cisplatin, Vincristine and Cyclophosphamide (ADOC). Patient in sophisticated conditions, first therapy today.

**June 20, 2023:** Follow-up CT scan showed partial response with a decrease in the size of the primary tumor and pulmonary nodules. Continued chemotherapy regimen.

**November 15, 2023:** Follow-up imaging CT chest/abdomen: disease progression with new metastatic lesions. Multiple hepatic lesions, with the largest lesion in segment VIII measuring 4.5 cm, and another lesion in segment II measuring 3.0 cm. Bone scan indicates metastatic involvement of the spine, with lesions identified at T6, T9, and L3 vertebrae. Additional findings include new pulmonary nodules and further enlargement of the primary mass in the anterior mediastinum. Signs of known ILD, stable.

**November 24, 2023:** Started second-line therapy with Carboplatin plus Paclitaxel.

**March 10, 2024:** Follow-up CT scan: PD. Progression of disease with increased size of liver metastases and new bone lesions.

**May 20, 2024:** Tumor board review recommended considering eligibility for clinical trials due to limited response to standard and investigational therapies.

**June 1, 2024:** Detailed assessment of health status confirmed adequate organ function. All routine labs within normal limits.

===== Patient 3.1.2 =====

**Patient Information**

Name: Thomas Meyer  
Born: January 12, 1966  
Address: Schlossallee 1, Dresden, Germany

## Overview of Tumor Diagnosis and Therapy

### Tumor Diagnosis

Diagnosis: Masaoka-Koga Stage IVb thymic adenocarcinoma (metastases to the lungs, liver and spines T6, T9, L3)

Initial Detection: March 15, 2023, following persistent chest pain and cough, shortness-of-breath

Biopsy Date: March 28, 2023

Molecular Profile: Germline: BRCA2 p.K3326\* (1N); Tumor: SMAD4 p.C363R (1N), TP53 p.305fs (2N\_LOH), CDKN1B p.K100N (2N\_LOH), ATM p.E1666\* (4N), MAP3K8 p.H236Y (1N), TRAF1 p.R70H (2N), HDAC2 p.R409\* (1N), TMEM111-TDRD3 fusion, PRKDC-CDH17 fusion, EXT1-MAGI2 fusion; Overexpressed genes: ERBB2, ERBB3, PDGFRB, TGFA, EGF, FGFR3, MET.

### Therapy Overview

Initial Treatment:

Chemotherapy: Began April 5, 2023, with combination of Doxorubicin, Cisplatin, Vincristine and Cyclophosphamide (ADOC). Partial response after the initial two chemotherapy cycles completed by June, 2023. Continued chemotherapy until November 2023 (progressive disease).

Subsequent Treatment: Second-line treatment with Carboplatin plus Paclitaxel starting Nov 24, 2023. Current Status: Disease progression as of May 2024, with new metastatic lesions in the lungs.

### Comorbidities

Coronary Artery Disease (CAD), status post percutaneous coronary intervention

(PCI) with stent placement in 2018

Interstitial Lung disease (ILD)

Hypertension Stage 2

Type 2 Diabetes Mellitus

Hyperlipidemia

Gastroesophageal Reflux Disease (GERD)

H/o cholecystectomy 2011

Former Smoker 25 py

### Medication

Aspirin 100 1-0-0

Clopidogrel 75mg 1-0-0

Prednisone 10mg 1x

Losartan 50mg once daily  
HCT 12.5mg once daily  
Metformin 1000mg 1x/d  
Atorvastatin 40mg once daily  
Omeprazole 20mg daily  
XGEVA q4w

**Performance Status:** ECOG Performance Status 1

**Chronological Medical Findings:**

**March 15, 2023:** Presented with persistent chest pain and cough and SOB.

**March 20, 2023:** CT scan of the chest: Mass in the anterior mediastinum measuring approximately 6.0 cm with evidence of local invasion into surrounding structures. Multiple pulmonary nodules suggestive of metastasis.

Evidence of known Interstitial Lung Disease (ILD) with diffuse interstitial markings and fibrosis.

**March 28, 2023:** CT-guided biopsy of mediastinal mass. Histology confirmed thymic adenocarcinoma. Whole exome sequencing revealed germline mutation BRCA2 p.K3326\*, tumor mutations: SMAD4 p.C363R, TP53 p.305fs, CDKN1B p.K100N, ATM p.E1666\*, MAP3K8 p.H236Y, TRAF1 p.R70H, HDAC2 p.R409\*, TMEM111-TDRD3 fusion, PRKDC-CDH17 fusion, EXT1-MAGI2 fusion. Overexpressed genes: ERBB2, ERBB3, PDGFRB, TGFA, EGF, FGFR3, MET.

**April 5, 2023:** Initiated chemotherapy with Doxorubicin, Cisplatin, Vincristine and Cyclophosphamide (ADOC). Patient in sophisticated conditions, first therapy today.

**June 20, 2023:** Follow-up CT scan showed partial response with a decrease in the size of the primary tumor and pulmonary nodules. Continued chemotherapy regimen.

**November 15, 2023:** Follow-up imaging CT chest/abdomen: disease progression with new metastatic lesions. Multiple hepatic lesions, with the largest lesion in segment VIII measuring 4.5 cm, and another lesion in segment II measuring 3.0 cm. Bone scan indicates metastatic involvement of the spine, with lesions identified at T6, T9, and L3 vertebrae. Additional findings include new pulmonary nodules and further enlargement of the primary mass in the anterior mediastinum. Signs of known ILD, stable.

**November 24, 2023:** Started second-line therapy with Carboplatin plus Paclitaxel.

**March 10, 2024:** Follow-up CT scan: PD. Progression of disease with increased size of liver metastases and new bone lesions.

**May 20, 2024:** Tumor board review recommended considering eligibility for clinical trials due to limited response to standard and investigational therapies.

**June 1, 2024:** Detailed assessment of health status confirmed adequate organ function. All routine labs within normal limits. Patient claims newly intermittent chest pain -> next week appointment at in-house cardiology department.

===== Patient 3.2 =====

### **Patient Information**

Name: Tim Müller

Born: January 03, 1966

Address: Parkallee 10, Dresden, Germany

### **Overview of Tumor Diagnosis and Therapy**

#### **Tumor Diagnosis**

Diagnosis: Masaoka-Koga Stage IVb thymic adenocarcinoma (metastases to the lungs, liver and spines T6, T9, L3)

Initial Detection: March 15, 2023, following persistent chest pain and cough, shortness-of-breath

Biopsy Date: March 28, 2023

Molecular Profile: Germline: **del BRCA2 mutation**; Tumor: SMAD4 p.C363R (1N), TP53 p.305fs (2N\_LOH), CDKN1B p.K100N (2N\_LOH), ATM p.E1666\* (4N), MAP3K8 p.H236Y (1N), TRAF1 p.R70H (2N), HDAC2 p.R409\* (1N), TMEM111-TDRD3 fusion, PRKDC-CDH17 fusion, EXT1-MAGI2 fusion; Overexpressed genes: ERBB2, ERBB3, PDGFRB, TGFA, EGF, FGFR3, MET.

#### **Therapy Overview**

Initial Treatment:

Chemotherapy: Began April 5, 2023, with combination of Doxorubicin, Cisplatin, Vincristine and Cyclophosphamide (ADOC). Partial response after the initial two chemotherapy cycles completed by June, 2023. Continued chemotherapy until November 2023 (progressive disease).

Subsequent Treatment: Second-line treatment with Carboplatin plus Paclitaxel starting Nov 24, 2023. Current Status: Disease progression as of May 2024, with new metastatic lesions in the lungs.

#### **Comorbidities**

Former Smoker 25 py  
Hypertension Stage 2  
Type 2 Diabetes Mellitus  
Hyperlipidemia  
Gastroesophageal Reflux Disease (GERD)  
H/o cholecystectomy 2011

#### **Medication**

Losartan 50mg once daily  
HCT 12.5mg once daily  
Metformin 1000mg once daily  
Atorvastatin 40mg once daily  
Omeprazole 20mg once daily  
XGEVA



**Performance Status:** ECOG Performance Status 1

**Chronological Medical Findings:**

**March 15, 2023:** Presented with persistent chest pain and cough and SOB.

**March 20, 2023:** CT scan of the chest: Mass in the anterior mediastinum measuring approximately 6.0 cm with evidence of local invasion into surrounding structures. Multiple pulmonary nodules suggestive of metastasis.

**March 28, 2023:** CT-guided biopsy of mediastinal mass. Histology confirmed thymic adenocarcinoma. Whole exome sequencing revealed: **germline BRCA2 mutation (del)**, tumor mutations: SMAD4 p.C363R, TP53 p.305fs, CDKN1B p.K100N, ATM p.E1666\*, MAP3K8 p.H236Y, TRAF1 p.R70H, HDAC2 p.R409\*, TMEM111-TDRD3 fusion, PRKDC-CDH17 fusion, EXT1-MAGI2 fusion. Overexpressed genes: ERBB2, ERBB3, PDGFRB, TGFA, EGF, FGFR3, MET.

**April 5, 2023:** Initiated chemotherapy with Doxorubicin, Cisplatin, Vincristine and Cyclophosphamide (ADOC). Patient in sophisticated conditions, first therapy today.

**June 20, 2023:** Follow-up CT scan showed partial response with a decrease in the size of the primary tumor and pulmonary nodules. Continued chemotherapy regimen.

**November 15, 2023:** Follow-up imaging CT chest/abdomen: disease progression with new metastatic lesions. Multiple hepatic lesions, with the largest lesion in segment VIII measuring 4.5 cm, and another lesion in segment II measuring 3.0 cm. Bone scan indicates metastatic involvement of the spine, with lesions identified at T6, T9, and L3 vertebrae. Additional findings include new pulmonary nodules and further enlargement of the primary mass in the anterior mediastinum.

**November 24, 2023:** Started second-line therapy with Carboplatin plus Paclitaxel.

**March 8, 2024:** End of chemotherapy.

**March 10, 2024:** Follow-up CT scan: PD. Progression of disease with increased size of liver metastases and new bone lesions.

**March 20, 2024:** Tumor board review recommended considering eligibility for clinical trials due to limited response to standard and investigational therapies.

**April 5, 2024:** Detailed assessment of health status confirmed adequate organ function. All routine labs within normal limits.

===== **Patient 4.1** =====

**Patient Information**

Name: David Gärtner

Born: March 22, 1965

Address: Cologne, Domstrasse 1, Germany

## Overview of Tumor Diagnosis and Therapy

### Tumor Diagnosis

**Diagnosis:** UICC Stage IV oropharyngeal carcinoma (Metastatic: LYM, HEP, OSS)

Initial Detection: February 10, 2023, following persistent sore throat and difficulty swallowing

Biopsy Date: February 20, 2023

Molecular Profile: PIK3CA p.E545K (AF 25%), MAPK1 p.E322K (AF 10%), FGFR3 p.D786N (AF 30%)

### Therapy Overview

Initial Treatment:

Radiochemotherapy: Began March 1, 2023, with a regimen of Cisplatin (200 mg/m<sup>2</sup>) paired with local radiotherapy (70G). Partial response noted after the initial radiochemotherapy completed by June 15, 2023. Follow-up CT scan shows disease progression in September 2024.

Subsequent Treatment: Began September 15, immunotherapy with Nivolumab (240mg/2weeks).

**Current Status:** Disease progression as of March 2024, with new metastatic lesions identified. ECOG 1.

### Comorbidities

Active Smoker 50 py

Hypertension Stage 1

Hyperlipidemia

Peripheral artery disease Fontaine 2a

Diverticular disease CDD 3a

### Medication

Lisinopril 20mg 1-0-0

Simvastatin 20mg 0-0-0-1

XGEVA, Vitamin D

### Chronological Medical Findings:

**February 10, 2023:** Presented with persistent sore throat and difficulty swallowing. CT scan of the neck revealed a suspicious mass in the oropharynx.

**February 15, 2023:** CT scan of the neck: Mass in the oropharynx measuring approximately 4.5 cm with evidence of local invasion into surrounding structures. Multiple enlarged cervical lymph nodes are noted, with the largest measuring approximately 2.2 cm in the right level II region. These nodes exhibit round morphology and loss of the fatty hilum, characteristics suggestive of metastatic involvement. Additional enlarged lymph nodes are present in the levels III and IV on the right side.

**February 18, 2023:** Staging CT (chest and abdomen): No signs of distant metastasis.

**February 20, 2023:** Biopsy of the oropharyngeal mass performed. Histology confirmed oropharyngeal carcinoma. Molecular panel sequencing revealed mutations: PIK3CA p.E545K (AF 25%), MAPK1 p.E322K (AF 10%), FGFR3 p.D786N (AF 30%). Tumor purity was 60%.

March 1, 2024: Initiated radiochemotherapy with Cisplatin and 5-Fluorouracil alongside local radiotherapy (70G).

**June 15, 2023:** Follow-up CT scan showed partial response with a decrease in the size of the primary tumor and cervical lymph nodes.

**September 10, 2023:** Follow-up imaging CT Neck/Chest/Abdomen: Disease progression (PD). Several new hypodense lesions identified in the liver: The largest lesion located in segment VI, measuring approximately 3.1 cm in diameter. Smaller lesions scattered throughout the right hepatic lobe. Multiple new pulmonary nodules are detected in both lungs. The largest nodule located in the right lower lobe, measuring approximately 1.5 cm in diameter. Additional smaller nodules are distributed throughout the bilateral lung fields. No evidence of pleural effusion or pneumothorax. The oropharyngeal mass remains present, with no significant change in size compared to the previous scan. The previously noted enlarged cervical lymph nodes remain prominent, with no significant interval change in size or number.

**September 15, 2023:** Began immunotherapy with Nivolumab.

**December 18, 2023:** Follow-up CT scan Neck/Chest/abdomen: Stable disease.

**December-February 2023:** Continuation Nivolumab.

**February 20, 2024:** Follow-up CT scan Neck/Chest/Abdomen: Progression of disease. Enlargement of multiple known hypodense lesions in the liver, with the largest now measuring 4.5 cm in segment VI (previously 3.1cm). New lytic lesions in the pelvis. Previously noted pulmonary nodules remain stable with no significant interval change. Stable primary tumor and cervical lymphadenopathy.

**March 3, 2024:** Tumor board review recommended considering eligibility for clinical trials due to limited response to standard and investigational therapies.

**March 10, 2024:** Detailed assessment of health status confirmed adequate organ function. Routine labs within normal limits: ANC 4,500/mcL, platelet count 250,000/mcL, total bilirubin 0.8 mg/dL, AST/ALT within normal limits, creatinine 0.8 mg/dL, hemoglobin 14.0 g/dL, serum albumin 4.0 g/dL, lipase and amylase within normal limits. Patient in good clinical condition.

==== **Patient 4.1.1** ====

## **Patient Information**

Name: David Gärtner

Born: March 22, 1965

Address: Cologne, Domstrasse 1, Germany

## **Overview of Tumor Diagnosis and Therapy**

### **Tumor Diagnosis**

**Diagnosis:** UICC Stage IV oropharyngeal carcinoma (Metastatic: LYM, HEP, OSS)

Initial Detection: February 10, 2023, following persistent sore throat and difficulty swallowing

Biopsy Date: February 20, 2023

Molecular Profile: PIK3CA p.E545K (AF 25%), MAPK1 p.E322K (AF 10%), FGFR3 p.D786N (AF 30%)

### **Therapy Overview**

Initial Treatment:

Radiochemotherapy: Began March 1, 2023, with a regimen of Cisplatin (200 mg/m<sup>2</sup>) paired with local radiotherapy (70G). Partial response noted after the initial radiochemotherapy completed by June 15, 2023. Follow-up CT scan shows disease progression in September 2024.

Subsequent Treatment: Began September 15, immunotherapy with Nivolumab (240mg/2weeks).

**Current Status:** Disease progression as of March 2024, with new metastatic lesions identified. ECOG 1.

### **Comorbidities**

Active Smoker 50 py

Hypertension Stage 1

Hyperlipidemia

Peripheral artery disease Fontaine 2a

Diverticular disease CDD 3a

### **Medication**

Lisinopril 20mg 1-0-0

Simvastatin 20mg 0-0-0-1

XGEVA, Vitamin D

**Chronological Medical Findings:**

**February 10, 2023:** Presented with persistent sore throat and difficulty swallowing. CT scan of the neck revealed a suspicious mass in the oropharynx.

**February 15, 2023:** CT scan of the neck: Mass in the oropharynx measuring approximately 4.5 cm with evidence of local invasion into surrounding structures. Multiple enlarged cervical lymph nodes are noted, with the largest measuring approximately 2.2 cm in the right level II region. These nodes exhibit round morphology and loss of the fatty hilum, characteristics suggestive of metastatic involvement. Additional enlarged lymph nodes are present in the levels III and IV on the right side.

**February 18, 2023:** Staging CT (chest and abdomen): No signs of distant metastasis.

**February 20, 2023:** Biopsy of the oropharyngeal mass performed. Histology confirmed oropharyngeal carcinoma. Molecular panel sequencing revealed mutations: PIK3CA p.E545K (AF 25%), MAPK1 p.E322K (AF 10%), FGFR3 p.D786N (AF 30%). Tumor purity was 60%.

March 1, 2024: Initiated radiochemotherapy with Cisplatin and 5-Fluorouracil alongside local radiotherapy (70G).

**June 15, 2023:** Follow-up CT scan showed partial response with a decrease in the size of the primary tumor and cervical lymph nodes.

**September 10, 2023:** Follow-up imaging CT Neck/Chest/Abdomen: Disease progression (PD). Several new hypodense lesions identified in the liver: The largest lesion located in segment VI, measuring approximately 3.1 cm in diameter. Smaller lesions scattered throughout the right hepatic lobe. Multiple new pulmonary nodules are detected in both lungs. The largest nodule located in the right lower lobe, measuring approximately 1.5 cm in diameter. Additional smaller nodules are distributed throughout the bilateral lung fields. No evidence of pleural effusion or pneumothorax. The oropharyngeal mass remains present, with no significant change in size compared to the previous scan. The previously noted enlarged cervical lymph nodes remain prominent, with no significant interval change in size or number.

**September 15, 2023:** Began immunotherapy with Nivolumab.

**December 18, 2023:** Follow-up CT scan Neck/Chest/abdomen: Stable disease.

**December-February 2023:** Continuation Nivolumab.

**February 20, 2024:** Follow-up CT scan Neck/Chest/Abdomen: Progression of disease. Enlargement of multiple known hypodense lesions in the liver, with the largest now measuring 4.5 cm in segment VI (previously 3.1cm). New lytic lesions in the pelvis. Previously noted pulmonary nodules remain stable with no significant interval change. Stable primary tumor and cervical lymphadenopathy.

**March 3, 2024:** Tumor board review recommended considering eligibility for clinical trials due to limited response to standard and investigational therapies.

**March 10, 2024:** Visit in the Emergency department with fever for 3 days, shortness of breath + cough + severe headaches.  
Routine labs: ANC 15,000/mcL, platelet count 200,000/mcL, total bilirubin 1.2mg/dL, AST/ALT 1.5 x ULN, creatinine 1.1 mg/dL, hemoglobin 12.0 g/dL, serum albumin 3.5 g/dL, leukocytes 18,000/mcL, CRP 23 mg/dL.  
Chest X-ray and CT scan confirmed pneumonia.  
Hospitalized for further evaluation and treatment.  
Blood and sputum cultures were taken and are pending.  
Patient started on IV antibiotics: Ceftriaxone and Azithromycin.

===== **Patient 4.1.2** =====

**Patient Information**

Name: David Gärtner

Born: March 22, 1965

Address: Cologne, Domstrasse 1, Germany

**Overview of Tumor Diagnosis and Therapy**

**Tumor Diagnosis**

**Diagnosis:** UICC Stage IV oropharyngeal carcinoma (Metastatic: LYM, HEP, OSS)

Initial Detection: February 10, 2023, following persistent sore throat and difficulty swallowing

Biopsy Date: February 20, 2023

Molecular Profile: PIK3CA p.E545K (AF 25%), MAPK1 p.E322K (AF 10%), FGFR3 p.D786N (AF 30%)

**Therapy Overview**

Initial Treatment:

Radiochemotherapy: Began March 1, 2023, with a regimen of Cisplatin (200 mg/m<sup>2</sup>) paired with local radiotherapy (70G). Partial response noted after the initial radiochemotherapy completed by June 15, 2023. Follow-up CT scan shows disease progression in September 2024.

Subsequent Treatment: Began September 15, immunotherapy with Nivolumab (240mg/2weeks).

**Current Status:** Disease progression as of March 2024, with new metastatic lesions identified. ECOG 1.

### Comorbidities

Active Smoker 50 py

Hypertension Stage 1

Hyperlipidemia

Peripheral artery disease Fontaine 2a

Diverticular disease CDD 3a

Epilepsy, Focal Onset Impaired Awareness Seizures

NYHA Class II Heart Failure

COPD, GOLD Stage 3 (Severe)

### Medication

Levetiracetam 500mg 1-0-1 (for epilepsy)

Metoprolol Succinate 50mg 1-0-0 (for heart failure)

Tiotropium 18mcg 1-0-0 (for COPD)

Salbutamol Inhaler 100mcg as needed (for COPD)

Lisinopril 20mg 1-0-0

Simvastatin 20mg 0-0-0-1

XGEVA, Vitamin D

### Chronological Medical Findings:

**February 10, 2023:** Presented with persistent sore throat and difficulty swallowing. CT scan of the neck revealed a suspicious mass in the oropharynx.

**February 15, 2023:** CT scan of the neck: Mass in the oropharynx measuring approximately 4.5 cm with evidence of local invasion into surrounding structures. Multiple enlarged cervical lymph nodes are noted, with the largest measuring approximately 2.2 cm in the right level II region. These nodes exhibit round morphology and loss of the fatty hilum, characteristics suggestive of metastatic involvement. Additional enlarged lymph nodes are present in the levels III and IV on the right side.

**February 18, 2023:** Staging CT (chest and abdomen): No signs of distant metastasis.

**February 20, 2023:** Biopsy of the oropharyngeal mass performed. Histology confirmed oropharyngeal carcinoma. Molecular panel sequencing revealed mutations: PIK3CA

p.E545K (AF 25%), MAPK1 p.E322K (AF 10%), FGFR3 p.D786N (AF 30%). Tumor purity was 60%.

March 1, 2024: Initiated radiochemotherapy with Cisplatin and 5-Fluorouracil alongside local radiotherapy (70G).

**June 15, 2023:** Follow-up CT scan showed partial response with a decrease in the size of the primary tumor and cervical lymph nodes.

**September 10, 2023:** Follow-up imaging CT Neck/Chest/Abdomen: Disease progression (PD). Several new hypodense lesions identified in the liver: The largest lesion located in segment VI, measuring approximately 3.1 cm in diameter. Smaller lesions scattered throughout the right hepatic lobe. Multiple new pulmonary nodules are detected in both lungs. The largest nodule located in the right lower lobe, measuring approximately 1.5 cm in diameter. Additional smaller nodules are distributed throughout the bilateral lung fields. No evidence of pleural effusion or pneumothorax. The oropharyngeal mass remains present, with no significant change in size compared to the previous scan. The previously noted enlarged cervical lymph nodes remain prominent, with no significant interval change in size or number.

**September 15, 2023:** Began immunotherapy with Nivolumab.

**December 18, 2023:** Follow-up CT scan Neck/Chest/abdomen: Stable disease.

**December-February 2023:** Continuation Nivolumab.

**February 20, 2024:** Follow-up CT scan Neck/Chest/Abdomen: Progression of disease. Enlargement of multiple known hypodense lesions in the liver, with the largest now measuring 4.5 cm in segment VI (previously 3.1cm). New lytic lesions in the pelvis. Previously noted pulmonary nodules remain stable with no significant interval change. Stable primary tumor and cervical lymphadenopathy.

**March 3, 2024:** Tumor board review recommended considering eligibility for clinical trials due to limited response to standard and investigational therapies.

**March 10, 2024:** Detailed assessment of health status confirmed adequate organ function. Routine labs within normal limits: ANC 4,500/mcL, platelet count 250,000/mcL, total bilirubin 0.8 mg/dL, AST/ALT within normal limits, creatinine 0.8 mg/dL, hemoglobin 14.0 g/dL, serum albumin 4.0 g/dL, lipase and amylase within normal limits. Patient in good clinical condition.

### ===== **Patient 4.1.3**=====

#### **Patient Information**

Name: David Gärtner

Born: March 22, 1965

Address: Cologne, Domstrasse 1, Germany

#### **Overview of Tumor Diagnosis and Therapy**

##### **Tumor Diagnosis**



**Diagnosis:** UICC Stage IV oropharyngeal carcinoma (Metastatic: LYM, HEP, OSS)

Initial Detection: February 10, 2023, following persistent sore throat and difficulty swallowing

Biopsy Date: February 20, 2023

Molecular Profile: PIK3CA p.E545K (AF 25%), MAPK1 p.E322K (AF 10%), FGFR3 p.D786N (AF 30%)

### Therapy Overview

Initial Treatment:

Radiochemotherapy: Began March 1, 2023, with a regimen of Cisplatin (200 mg/m<sup>2</sup>) paired with local radiotherapy (70G). Partial response noted after the initial radiochemotherapy completed by June 15, 2023. Follow-up CT scan shows disease progression in September 2024.

Subsequent Treatment: Began September 15, immunotherapy with Nivolumab (240mg/2weeks).

**Current Status:** Disease progression as of March 2024, with new metastatic lesions identified. ECOG 1.

### Comorbidities

Active hepatitis C virus (HCV) infection (HCV antibody +),

HCV RNA elevated (March 10, 2024)

Active Smoker 50 py

Alcoholic (6 bottles of beer / day) Regular marijuana use (up to 10 joints per day)

Hypertension Stage 1

Hyperlipidemia

Peripheral artery disease Fontaine 2a

Diverticular disease CDD 3a

### Medication

Sofosbuvir/Velpatasvir 400mg/100mg 1-0-0

Lisinopril 20mg 1-0-0

Simvastatin 20mg 0-0-0-1

XGEVA, Vitamin D

### **Chronological Medical Findings:**

**February 10, 2023:** Presented with persistent sore throat and difficulty swallowing. CT scan of the neck revealed a suspicious mass in the oropharynx.

**February 15, 2023:** CT scan of the neck: Mass in the oropharynx measuring approximately 4.5 cm with evidence of local invasion into surrounding structures. Multiple enlarged cervical lymph nodes are noted, with the largest measuring approximately 2.2 cm in the right level II region. These nodes exhibit round morphology and loss of the fatty hilum, characteristics suggestive of metastatic involvement. Additional enlarged lymph nodes are present in the levels III and IV on the right side.

**February 18, 2023:** Staging CT (chest and abdomen): No signs of distant metastasis.

**February 20, 2023:** Biopsy of the oropharyngeal mass performed. Histology confirmed oropharyngeal carcinoma. Molecular panel sequencing revealed mutations: PIK3CA p.E545K (AF 25%), MAPK1 p.E322K (AF 10%), FGFR3 p.D786N (AF 30%). Tumor purity was 60%.

March 1, 2024: Initiated radiochemotherapy with Cisplatin and 5-Fluorouracil alongside local radiotherapy (70G).

**June 15, 2023:** Follow-up CT scan showed partial response with a decrease in the size of the primary tumor and cervical lymph nodes.

**September 10, 2023:** Follow-up imaging CT Neck/Chest/Abdomen: Disease progression (PD). Several new hypodense lesions identified in the liver: The largest lesion located in segment VI, measuring approximately 3.1 cm in diameter. Smaller lesions scattered throughout the right hepatic lobe. Multiple new pulmonary nodules are detected in both lungs. The largest nodule located in the right lower lobe, measuring approximately 1.5 cm in diameter. Additional smaller nodules are distributed throughout the bilateral lung fields. No evidence of pleural effusion or pneumothorax. The oropharyngeal mass remains present, with no significant change in size compared to the previous scan. The previously noted enlarged cervical lymph nodes remain prominent, with no significant interval change in size or number.

**September 15, 2023:** Began immunotherapy with Nivolumab.

**December 18, 2023:** Follow-up CT scan Neck/Chest/abdomen: Stable disease.

**December-February 2023:** Continuation Nivolumab.

**February 20, 2024:** Follow-up CT scan Neck/Chest/Abdomen: Progression of disease. Enlargement of multiple known hypodense lesions in the liver, with the largest now measuring 4.5 cm in segment VI (previously 3.1cm). New lytic lesions in the pelvis. Previously noted pulmonary nodules remain stable with no significant interval change. Stable primary tumor and cervical lymphadenopathy.

**March 3, 2024:** Tumor board review recommended considering eligibility for clinical trials due to limited response to standard and investigational therapies.

**March 10, 2024:** Detailed assessment of health status confirmed adequate organ function. Routine labs within normal limits: ANC 4,500/mcL, platelet count 250,000/mcL, total bilirubin 0.8 mg/dL, AST/ALT within normal limits, creatinine 0.8 mg/dL,

hemoglobin 14.0 g/dL, serum albumin 4.0 g/dL, lipase and amylase within normal limits. HCV RNA at 2,500,000 IU/mL. Patient in good clinical condition.

===== Patient 5.1 =====

**Patient Information**

Name: Lisa Müller  
Born: April 12, 1960  
Address: Hamburg, Hafenstrasse 3, Germany

**Overview of Tumor Diagnosis and Therapy**

**Tumor Diagnosis**

Diagnosis: Stage IV lung adenocarcinoma (M+: HEP, LYM, BONE, ADRENAL)  
Initial Detection: January November 21, 2023, following persistent cough and weight loss  
Biopsy Date: November 28, 2023

Molecular Profile: EGFR p.E746\_A750del (AF 43%), TP53 p.A138\_Q144del (AF 37%), MET Amplification FISH positive; Tumor Purity: 30%; Tumor Mutational Burden (TMB): 3.8 Mut/MB

**Therapy Overview**

Initial Treatment:  
Chemotherapy: Began February December 2023, with a regimen of Pembrolizumab, Carboplatin and Pemetrexed. Partial response after the initial chemotherapy cycle completed by May 1, 2024. Continued chemotherapy until May 2024 (progressive disease).

**Comorbidities**

Hyperlipidemia  
Osteoarthritis  
Psoriasis vulgaris  
H/o cholecystectomy 2007  
45py

**Medication**

Atorvastatin 40mg once daily  
Hydrocortisone cream  
Ibuprofen 400mg as needed  
XGEVA  
Novalgine 500 2-2-2-2

**Performance Status:** ECOG Performance Status 1

**Chronological Medical Findings:**

**November 8, 2023:** Presented with persistent cough and weight loss (-6kg/3 mo) at her primary care physician. 1 week antibiotic treatment for suspected airway infection without clinical improvements, chest x-ray revealed tumorous lesion in the left lung.

**November 21, 2023:** CT scan of the chest: Mass in the left upper lobe measuring approximately 5.0 cm with evidence of local invasion into surrounding structures, including the left main bronchus and adjacent vascular structures. Enlarged mediastinal lymph nodes, particularly in the subcarinal and right paratracheal regions, with the largest node measuring 1.8 cm. Additional moderate pleural effusion on the left side. Multiple liver lesions suggestive of metastasis, with the largest lesion in segment VIII measuring 3.5 cm and another lesion in segment IVa measuring 2.2 cm. Adrenal metastasis on the left side. Bone metastases in C3, T3,4,7.

**November 28, 2023:** CT guided tumor biopsy: Histology confirmed lung adenocarcinoma. Molecular panel sequencing revealed mutations: EGFR p.E746\_A750del (AF 43%), TP53 p.A138\_Q144del (AF 37%), MET Amplification FISH positive. Tumor purity was 30%. Tumor Mutational Burden (TMB) was 3.8 Mut/MB.

**December 5, 2023:** Initiated chemotherapy with Carboplatin and Pemetrexed + immunotherapy with Pembrolizumab.

**March 10, 2024:** Follow-up CT scan: Partial Response. Continued chemotherapy regimen.

**March - May 2024:** Continued therapy with Carbo/Pem + Pembrolizumab.

**May 07, 2024:** CT-scan Chest/Abdomen: Significant disease progression. Mass in the left upper lobe has increased to approximately 6.5 cm with further invasion into the left main bronchus and adjacent vascular structures. Enlarged mediastinal lymph nodes are now more prominent, especially in the subcarinal and right paratracheal regions, with the largest node now measuring 2.5 cm. Progressive pleural effusion left > right.

Abdomen and Pelvis: Multiple liver lesions, with the largest in segment VIII now measuring 4.5 cm and another in segment IVa measuring 3.0 cm. New metastatic lesions observed in segments V and VI. The adrenal metastasis on the left side has increased in size to 2.5 cm.

Bone Metastases: Increased metastatic involvement with new lesions identified in the spine, including C2, T5, and L1, in addition to the previously noted C3, T3, T4, and T7.

**May 10, 2024:** Tumor board review recommended considering eligibility for clinical trials due to limited response to standard and investigational therapies.

**May 15, 2024:** Detailed assessment of health status confirmed adequate organ function. Routine labs within normal limits: ANC 4,800/mcL, platelet count 220,000/mcL, total

bilirubin 0.9 mg/dL, AST/ALT within normal limits, creatinine 0.9 mg/dL, hemoglobin 13.5 g/dL, serum albumin 4.2 g/dL, lipase and amylase within normal limits.

===== Patient 5.1.1 =====

**Patient Information**

Name: Lisa Müller  
Born: April 12, 1960  
Address: Hamburg, Hafenstrasse 3, Germany

**Overview of Tumor Diagnosis and Therapy**

**Tumor Diagnosis**

Diagnosis: Stage IV lung adenocarcinoma (M+: HEP, LYM, BONE, ADRENAL)  
Initial Detection: January November 21, 2023, following persistent cough and weight loss  
Biopsy Date: November 28, 2023

Molecular Profile: EGFR p.E746\_A750del (AF 43%), TP53 p.A138\_Q144del (AF 37%), MET Amplification FISH positive; Tumor Purity: 30%; Tumor Mutational Burden (TMB): 3.8 Mut/MB

**Therapy Overview**

Initial Treatment:  
Chemotherapy: Began February December 2023, with a regimen of Pembrolizumab, Carboplatin and Pemetrexed. Partial response after the initial chemotherapy cycle completed by May 1, 2024. Continued chemotherapy until May 2024 (progressive disease).

**Comorbidities**

Hyperlipidemia  
Osteoarthritis  
Psoriasis vulgaris  
H/o cholecystectomy 2007  
45py

**Medication**

Atorvastatin 40mg once daily  
Hydrocortisone cream  
Ibuprofen 400mg as needed  
XGEVA  
Novalgine 500 2-2-2-2  
Prednisone 40mg daily

**Performance Status:** ECOG Performance Status 2

**Chronological Medical Findings:**

**November 8, 2023:** Presented with persistent cough and weight loss (-6kg/3 mo) at her primary care physician. 1 week antibiotic treatment for suspected airway infection without clinical improvements, chest x-ray revealed tumorous lesion in the left lung.

**November 21, 2023:** CT scan of the chest: Mass in the left upper lobe measuring approximately 5.0 cm with evidence of local invasion into surrounding structures, including the left main bronchus and adjacent vascular structures. Enlarged mediastinal lymph nodes, particularly in the subcarinal and right paratracheal regions, with the largest node measuring 1.8 cm. Additional moderate pleural effusion on the left side. Multiple liver lesions suggestive of metastasis, with the largest lesion in segment VIII measuring 3.5 cm and another lesion in segment IVa measuring 2.2 cm. Adrenal metastasis on the left side. Bone metastases in C3, T3,4,7.

**November 28, 2023:** CT guided tumor biopsy: Histology confirmed lung adenocarcinoma. Molecular panel sequencing revealed mutations: EGFR p.E746\_A750del (AF 43%), TP53 p.A138\_Q144del (AF 37%), MET Amplification FISH positive. Tumor purity was 30%. Tumor Mutational Burden (TMB) was 3.8 Mut/MB.

**December 5, 2023:** Initiated chemotherapy with Carboplatin and Pemetrexed + immunotherapy with Pembrolizumab.

**March 10, 2024:** Follow-up CT scan: Partial Response. Continued chemotherapy regimen.

**March - May 2024:** Continued therapy with Carbo/Pem + Pembrolizumab.

**May 07, 2024:** CT-scan Chest/Abdomen: Significant disease progression. Mass in the left upper lobe has increased to approximately 6.5 cm with further invasion into the left main bronchus and adjacent vascular structures. Enlarged mediastinal lymph nodes are now more prominent, especially in the subcarinal and right paratracheal regions, with the largest node now measuring 2.5 cm. Progressive pleural effusion left > right. Additionally, there are diffuse ground-glass opacities and reticular markings throughout both lungs, suspicious for immune mediated Pneumonitis.

Abdomen and Pelvis: Multiple liver lesions, with the largest in segment VIII now measuring 4.5 cm and another in segment IVa measuring 3.0 cm. New metastatic lesions observed in segments V and VI. The adrenal metastasis on the left side has increased in size to 2.5 cm.

Bone Metastases: Increased metastatic involvement with new lesions identified in the spine, including C2, T5, and L1, in addition to the previously noted C3, T3, T4, and T7.

**May 08, 2024:** Started on Prednisone 40 mg daily because of Lung findings.

Follow-up CT scan and pulmonary function tests scheduled.

Patient advised on potential side effects and the need for regular monitoring.

**May 10, 2024:** Tumor board review recommended considering eligibility for clinical trials due to limited response to standard and investigational therapies.

**May 15, 2024:** Detailed assessment of health status confirmed adequate organ function. Routine labs within normal limits: ANC 4,800/mcL, platelet count 220,000/mcL, total bilirubin 0.9 mg/dL, AST/ALT within normal limits, creatinine 0.9 mg/dL, hemoglobin 13.5 g/dL, serum albumin 4.2 g/dL, lipase and amylase within normal limits.

===== **Patient 6.1** =====

**Patient Information**

Name: Ehrich, Wolfgang

born: 18.08.1968

Address: Kurfürstendamm 1, Berlin, Germany

**Overview of Tumor Diagnosis and Therapy**

**Tumor Diagnosis**

Diagnosis: UICC Stage IVA, M1a (contralateral metastases, malignant pleural effusions),

KRAS G12C mutant non-small cell lung cancer (NSCLC)

Initial Detection: March 22, 2023, following symptoms of persistent cough and weight loss

Biopsy Date: April 15, 2023, squamous cell lung cancer, PDL1 3%

Molecular Profile: Molecular alterations: KRAS p.G12C (AF 18%), KRAS p.G12C (AF 18%), KEAP1 p.L276F (AF 45%), STK11 p.K83Tfs\*13 (AF 38%).

**Therapy Overview**

Combined Immuno-chemotherapy: Began May 5, 2023, with Cisplatin,

Pemetrexed and Pembrolizumab, partial response noted after cycle completion by August 10, 2023, continuation of therapy until October 2023 (progressive disease)

**Current Status**

Health Condition: Stable with an ECOG performance status of 1

**Comorbidities**

Former Smoker: 40 py  
Hypertension Stage I  
COPD GOLD 2  
Type 2 Diabetes Mellitus  
Hyperlipidemia

### Medication

Lisinopril 20mg 1-0-0  
Metformin 1000mg 1-0-1  
Atorvastatin 40mg 0-0-0-1  
Tiotropium (Inhaler) on demand  
Novalgin 500mg 1-1-1-1  
Apixaban 5mg 1-0-1

### Chronological Medical Findings:

March 22, 2023: Experienced persistent cough and weight loss. Chest X-ray and CT scan revealed a mass in the left lung. Referred to oncologist. CT-Angiography: Tumor Size: Approximately 4.5 cm in diameter. At least 2 contralateral metastases. Bronchial Obstruction: Partial obstruction of the left main bronchus leading to atelectasis of the left upper lobe. Suspicion of mediastinal lymph node metastases. No evidence of pulmonary artery embolism. Thrombus in the left atrium at the transition to the auricle. Emphysematous and fibrotic changes in the lung parenchyma. Urgent suspicion of a tumor-atelectasis complex in the left upper lobe of the lung. Mucus present in the lower lobe bronchi on the left. Lymph Nodes: Enlarged, FDG-positive lymph nodes in the mediastinum, particularly in regions 4R and infracarinal.

April 15, 2023: Lung biopsy via bronchoscopy: Endobronchial tumor manifestation in the distal left main bronchus extending to the upper lobe. Acute and chronic atrophic tracheobronchitis. Collapsed bronchial system in the affected area. Biopsy taken. Diagnosed with squamous non-small cell lung cancer (NSCLC), molecular diagnostics: KRAS G12C mutant.

April 27, 2023: Ventilation: Moderate obstruction, no restriction. Increased airway resistance and slight hyperinflation. Tiffeneau index (FEV1/FVC) at 42.34%, z-score -3.32. FEV1: 0.93 L (42% predicted), z-score -2.89. Total lung capacity (TLC): 5.86 L (103% predicted), z-score 0.22. Forced vital capacity (FVC): 2.19 L, z-score -1.5. Residual volume (RV): 3.67 L, z-score 2.44. RV/TLC: 62.68%, z-score -1.18.

May 5, 2023: Initiated on platinum-based immunochemotherapy regimen (Cisplatin, Pemetrexed, Pembrolizumab).



August 10, 2023: Completed initial therapy cycle. Partial response as per CT chest / abdomen +PET CT: Moderate reduction in tumor size to approximately 4.2 cm. Contralateral metastases still present, but no new lesions. Partial bronchial obstruction persists with ongoing atelectasis in the left upper lobe. Mediastinal lymph nodes remain enlarged and FDG-positive, although with reduced metabolic activity. Thrombus in the left atrium remains unchanged. Emphysematous and fibrotic changes are stable. Overall, mild response observed with no significant progression, as per RECIST stable disease.

August-October: Continued chemotherapy with Cisplatin/Pemetrexed and Pembrolizumab.

October 13, 2023: Follow-up CT (chest + abdomen): SD / Progressive Disease. New nodule in the right lung (1cm). Slight increase in the size of previously noted FDG-positive lymph nodes in the mediastinum. No additional metastatic lesions were detected. The patient has continued to tolerate the current treatment regimen well, with no significant adverse effects reported.

October 17, 2023: Tumor board: SD. Continuation of therapy.

October 25, 2023: Continuation of Cisplatin (dose reduced), Pemetrexed and Pembrolizumab.

January 12, 2024: Follow-up CT scan abdomen and chest, FDG-PET-CT: Progressive Disease with three new metastases in the right lung and additional enlarged FDG-positive lymph nodes in the mediastinum. MRI scan of the brain conducted; no evidence of metastatic disease. Incidental findings included mild age-related cerebral atrophy and scattered white matter hyperintensities consistent with chronic microvascular ischemic changes.

March 17, 2024: Tumorboard recommends considering clinical trial options due to limited response to standard therapies.

April 20, 2024: Detailed assessment of health status. ECOG performance status 1. All routine labs, including liver and renal function tests, within normal limits.

## ===== **Patient 6.1.1** =====

### **Patient Information**

Name: Ehrich, Wolfgang

born: 18.08.1968

Address: Kurfürstendamm 1, Berlin, Germany

### **Overview of Tumor Diagnosis and Therapy**

#### **Tumor Diagnosis**

Diagnosis: UICC Stage IVA, M1a (contralateral metastases, malignant pleural effusions),

KRAS G12C mutant non-small cell lung cancer (NSCLC)

Initial Detection: March 22, 2023, following symptoms of persistent cough and weight loss

Biopsy Date: April 15, 2023, squamous cell lung cancer, PDL1 3%

Molecular Profile: Molecular alterations: KRAS p.G12C (AF 18%), KRAS p.G12C (AF 18%), KEAP1 p.L276F (AF 45%), STK11 p.K83Tfs\*13 (AF 38%).

### Therapy Overview

Combined Immuno-chemotherapy: Began May 5, 2023, with Cisplatin,

Pemetrexed and Pembrolizumab, partial response noted after cycle completion by August 10, 2023, continuation of therapy until October 2023 (progressive disease)

### Current Status

Health Condition: Stable with an ECOG performance status of 1

### Comorbidities

Chronic heart failure (NYHA Class III),

reduced ejection fraction (HFrEF) of 35%

Post Myocardial Infarction (2021), 2 coronary stents

Former Smoker: 40 py

Hypertension Stage I

COPD GOLD 2

Type 2 Diabetes Mellitus

Hyperlipidemia

### Medication

Lisinopril 20mg 1-0-0

Metformin 1000mg 1-0-1

ASS 100mg 1-0-0

Carvedilol 12.5mg 1-0-1

Furosemide 40mg 1-0-1

Apixaban 5mg 1-0-1

Atorvastatin 40mg 0-0-0-1

Tiotropium (Inhaler) on demand

Novalglin 500mg 1-1-1-1

### **Chronological Medical Findings:**

March 22, 2023: Experienced persistent cough and weight loss. Chest X-ray and CT scan revealed a mass in the left lung. Referred to oncologist. CT-Angiography: Tumor Size: Approximately 4.5 cm in diameter. At least 2 contralateral metastases. Bronchial Obstruction: Partial obstruction of the left main bronchus leading to atelectasis of the left upper lobe. Suspicion of mediastinal lymph node metastases. No evidence of pulmonary artery embolism. Thrombus in the left atrium at the transition to the auricle. Emphysematous and fibrotic changes in the lung parenchyma. Urgent suspicion of a tumor-atelectasis complex in the left upper lobe of the lung. Mucus present in the lower lobe bronchi on the left. Lymph Nodes: Enlarged, FDG-positive lymph nodes in the mediastinum, particularly in regions 4R and infracarinal.

April 15, 2023: Lung biopsy via bronchoscopy: Endobronchial tumor manifestation in the distal left main bronchus extending to the upper lobe. Acute and chronic atrophic tracheobronchitis. Collapsed bronchial system in the affected area. Biopsy taken. Diagnosed with squamous non-small cell lung cancer (NSCLC), molecular diagnostics: KRAS G12C mutant.

April 27, 2023: Ventilation: Moderate obstruction, no restriction. Increased airway resistance and slight hyperinflation. Tiffeneau index (FEV1/FVC) at 42.34%, z-score -3.32. FEV1: 0.93 L (42% predicted), z-score -2.89. Total lung capacity (TLC): 5.86 L (103% predicted), z-score 0.22. Forced vital capacity (FVC): 2.19 L, z-score -1.5. Residual volume (RV): 3.67 L, z-score 2.44. RV/TLC: 62.68%, z-score -1.18.

May 5, 2023: Initiated on platinum-based immunochemotherapy regimen (Cisplatin, Pemetrexed, Pembrolizumab).

August 10, 2023: Completed initial therapy cycle. Partial response as per CT chest / abdomen +PET CT: Moderate reduction in tumor size to approximately 4.2 cm. Contralateral metastases still present, but no new lesions. Partial bronchial obstruction persists with ongoing atelectasis in the left upper lobe. Mediastinal lymph nodes remain enlarged and FDG-positive, although with reduced metabolic activity. Thrombus in the left atrium remains unchanged. Emphysematous and fibrotic changes are stable. Overall, mild response observed with no significant progression, as per RECIST stable disease.

August-October: Continued chemotherapy with Cisplatin/Pemetrexed and Pembrolizumab.

October 13, 2023: Follow-up CT (chest + abdomen): SD / Progressive Disease. New nodule in the right lung (1cm). Slight increase in the size of previously noted FDG-positive lymph nodes in the mediastinum. No additional metastatic lesions were detected. The patient has continued to tolerate the current treatment regimen well, with no significant adverse effects reported.

October 17, 2023: Tumor board: SD. Continuation of therapy.

October 25, 2023: Continuation of Cisplatin (dose reduced), Pemetrexed and Pembrolizumab.

January 12, 2024: Follow-up CT scan abdomen and chest, FDG-PET-CT: Progressive Disease with three new metastases in the right lung and additional enlarged FDG-positive lymph nodes in the mediastinum.

MRI scan of the brain revealed multiple metastases,

specifically three lesions in the left hemisphere:

one in the left frontal lobe, one in the left parietal lobe,

and one in the left occipital lobe. Incidental findings included mild age-related cerebral atrophy and scattered white matter hyperintensities consistent with chronic microvascular ischemic changes.

March 17, 2024: Tumorboard recommends considering clinical trial options due to limited response to standard therapies.

April 20, 2024: Detailed assessment of health status. Patient currently in ECOG performance status 1. All routine labs, including liver and renal function tests, within normal limits.

## ===== Patient 6.1.2 =====

### **Patient Information**

Name: Ehrich, Wolfgang

born: 18.08.1968

Address: Kurfürstendamm 1, Berlin, Germany

### **Overview of Tumor Diagnosis and Therapy**

#### **Tumor Diagnosis**

Diagnosis: UICC Stage IVA, M1a (contralateral metastases, malignant pleural effusions),

KRAS G12C mutant non-small cell lung cancer (NSCLC)

Initial Detection: March 22, 2023, following symptoms of persistent cough and weight loss

Biopsy Date: April 15, 2023, squamous cell lung cancer, PDL1 3%

Molecular Profile: Molecular alterations: KRAS p.G12C (AF 18%), KRAS p.G12C (AF 18%), KEAP1 p.L276F (AF 45%), STK11 p.K83Tfs\*13 (AF 38%).

### Therapy Overview

Combined Immuno-chemotherapy: Began May 5, 2023, with Cisplatin,

Pemetrexed and Pembrolizumab, partial response noted after cycle completion by August 10, 2023, continuation of therapy until October 2023 (progressive disease)

### Current Status

Health Condition: Stable with an ECOG performance status of 1

### Comorbidities

Chronic heart failure (NYHA Class III), reduced ejection fraction (HFrEF) of 35%

Post Myocardial Infarction (2021), 2 coronary stents

Former Smoker: 40 py

Hypertension Stage I

COPD GOLD 2

Type 2 Diabetes Mellitus

Hyperlipidemia

### Medication

Lisinopril 20mg 1-0-0

Metformin 1000mg 1-0-1

ASS 100mg 1-0-0

Carvedilol 12.5mg 1-0-1

Furosemide 40mg 1-0-1

Apixaban 5mg 1-0-1

Atorvastatin 40mg 0-0-0-1

Tiotropium (Inhaler) on demand

Novalgine 500mg 1-1-1-1

### Chronological Medical Findings:

March 22, 2023: Experienced persistent cough and weight loss. Chest X-ray and CT scan revealed a mass in the left lung. Referred to oncologist. CT-Angiography: Tumor Size: Approximately 4.5 cm in diameter. At least 2 contralateral metastases. Bronchial Obstruction: Partial obstruction of the left main bronchus leading to atelectasis of the left upper lobe. Suspicion of mediastinal lymph node metastases. No evidence of pulmonary artery embolism. Thrombus in the left atrium at the transition to the auricle. Emphysematous and fibrotic changes in the lung parenchyma. Urgent suspicion of a tumor-atelectasis complex in the left upper lobe of the lung. Mucus present in the lower lobe bronchi on the left. Lymph Nodes: Enlarged, FDG-positive lymph nodes in the mediastinum, particularly in regions 4R and infracarinal.

April 15, 2023: Lung biopsy via bronchoscopy: Endobronchial tumor manifestation in the distal left main bronchus extending to the upper lobe. Acute and chronic atrophic tracheobronchitis. Collapsed bronchial system in the affected area. Biopsy taken. Diagnosed with squamous non-small cell lung cancer (NSCLC), molecular diagnostics: KRAS G12C mutant.

April 27, 2023: Ventilation: Moderate obstruction, no restriction. Increased airway resistance and slight hyperinflation. Tiffeneau index (FEV1/FVC) at 42.34%, z-score -3.32. FEV1: 0.93 L (42% predicted), z-score -2.89. Total lung capacity (TLC): 5.86 L (103% predicted), z-score 0.22. Forced vital capacity (FVC): 2.19 L, z-score -1.5. Residual volume (RV): 3.67 L, z-score 2.44. RV/TLC: 62.68%, z-score -1.18.

May 5, 2023: Initiated on platinum-based immunochemotherapy regimen (Cisplatin, Pemetrexed, Pembrolizumab).

August 10, 2023: Completed initial therapy cycle. Partial response as per CT chest / abdomen +PET CT: Moderate reduction in tumor size to approximately 4.2 cm. Contralateral metastases still present, but no new lesions. Partial bronchial obstruction persists with ongoing atelectasis in the left upper lobe. Mediastinal lymph nodes remain enlarged and FDG-positive, although with reduced metabolic activity. Thrombus in the left atrium remains unchanged. Emphysematous and fibrotic changes are stable. Overall, mild response observed with no significant progression, as per RECIST stable disease.

August-October: Continued chemotherapy with Cisplatin/Pemetrexed and Pembrolizumab.

October 13, 2023: Follow-up CT (chest + abdomen): SD / Progressive Disease. New nodule in the right lung (1cm). Slight increase in the size of previously noted FDG-positive lymph nodes in the mediastinum. No additional metastatic lesions were detected. The patient has continued to tolerate the current treatment regimen well, with no significant adverse effects reported.

October 17, 2023: Tumor board: SD. Continuation of therapy.

October 25, 2023: Continuation of Cisplatin (dose reduced), Pemetrexed and Pembrolizumab.

January 12, 2024: Follow-up CT scan abdomen and chest, FDG-PET-CT: Progressive Disease with three new metastases in the right lung and additional enlarged FDG-positive lymph nodes in the mediastinum.

MRI scan of the brain revealed multiple metastases,

specifically three lesions in the left hemisphere:

one in the left frontal lobe,

one in the left parietal lobe, and one in the left occipital lobe. Incidental findings included mild age-related cerebral atrophy and scattered white matter hyperintensities consistent with chronic microvascular ischemic changes.

March 17, 2024: Tumorboard recommends considering clinical trial options due to limited response to standard therapies.

April 20, 2024: Detailed assessment of health status.

Patient currently in ECOG performance status 2.

Routine labs: GOT 103 U/L, GPT 112 U/L, Creatinine 2.3 mg/dL

## ===== Patient 6.2 =====

### Patient Information

Name: Ehrich, Wolfgang

born: 18.08.1968

Address: Kurfürstendamm 1, Berlin, Germany

### Overview of Tumor Diagnosis and Therapy

#### Tumor Diagnosis

Diagnosis: UICC Stage IVA, M1a (contralateral metastases, malignant pleural effusions),  
KRAS G12C mutant non-small cell lung cancer (NSCLC)

Initial Detection: March 22, 2023, following symptoms of persistent cough and weight loss

Biopsy Date: April 15, 2023, squamous cell lung cancer, PDL1 3%

Molecular Profile: Molecular alterations: KRAS p.G12C (AF 18%), KRAS p.G12C (AF 18%), KEAP1 p.L276F (AF 45%), STK11 p.K83Tfs\*13 (AF 38%).

#### Therapy Overview

Combined Immuno-chemotherapy: Began May 5, 2023, with Cisplatin,

Pemetrexed and Pembrolizumab, partial response noted after cycle completion by August 10, 2023, continuation of therapy until October 2023 (progressive disease)

### **Current Status**

Health Condition: Stable with an ECOG performance status of 1

### **Comorbidities**

Former Smoker: 40 py  
Hypertension Stage I  
COPD GOLD 2  
Type 2 Diabetes Mellitus  
Hyperlipidemia

### **Medication**

Lisinopril 20mg 1-0-0  
Metformin 1000mg 1-0-1  
Atorvastatin 40mg 0-0-0-1  
Tiotropium (Inhaler) on demand  
Novalgin 500mg 1-1-1-1  
Apixaban 5mg 1-0-1

### **Chronological Medical Findings:**

March 22, 2023: Experienced persistent cough and weight loss. Chest X-ray and CT scan revealed a mass in the left lung. Referred to oncologist. CT-Angiography: Tumor Size: Approximately 4.5 cm in diameter. At least 2 contralateral metastases. Bronchial Obstruction: Partial obstruction of the left main bronchus leading to atelectasis of the left upper lobe. Suspicion of mediastinal lymph node metastases. No evidence of pulmonary artery embolism. Thrombus in the left atrium at the transition to the auricle. Emphysematous and fibrotic changes in the lung parenchyma. Urgent suspicion of a tumor-atelectasis complex in the left upper lobe of the lung. Mucus present in the lower lobe bronchi on the left. Lymph Nodes: Enlarged, FDG-positive lymph nodes in the mediastinum, particularly in regions 4R and infracarinal.

April 15, 2023: Lung biopsy via bronchoscopy: Endobronchial tumor manifestation in the distal left main bronchus extending to the upper lobe. Acute and chronic atrophic tracheobronchitis. Collapsed bronchial system



in the affected area. Biopsy taken. Diagnosed with squamous non-small cell lung cancer (NSCLC), molecular diagnostics: KRAS G12C mutant.

April 27, 2023: Ventilation: Moderate obstruction, no restriction. Increased airway resistance and slight hyperinflation. Tiffeneau index (FEV1/FVC) at 42.34%, z-score -3.32. FEV1: 0.93 L (42% predicted), z-score -2.89. Total lung capacity (TLC): 5.86 L (103% predicted), z-score 0.22. Forced vital capacity (FVC): 2.19 L, z-score -1.5. Residual volume (RV): 3.67 L, z-score 2.44. RV/TLC: 62.68%, z-score -1.18.

May 5, 2023: Initiated on platinum-based immunochemotherapy regimen (Cisplatin, Pemetrexed, Pembrolizumab).

August 10, 2023: Completed initial therapy cycle. Partial response as per CT chest / abdomen +PET CT: Moderate reduction in tumor size to approximately 4.2 cm. Contralateral metastases still present, but no new lesions. Partial bronchial obstruction persists with ongoing atelectasis in the left upper lobe. Mediastinal lymph nodes remain enlarged and FDG-positive, although with reduced metabolic activity. Thrombus in the left atrium remains unchanged. Emphysematous and fibrotic changes are stable. Overall, mild response observed with no significant progression, as per RECIST stable disease.

August-October: Continued chemotherapy with Cisplatin/Pemetrexed and Pembrolizumab.

October 13, 2023: Follow-up CT (chest + abdomen): SD / Progressive Disease. New nodule in the right lung (1cm). Slight increase in the size of previously noted FDG-positive lymph nodes in the mediastinum. No additional metastatic lesions were detected. The patient has continued to tolerate the current treatment regimen well, with no significant adverse effects reported.

October 17, 2023: Tumor board: SD. Continuation of therapy.

October 25, 2023: Continuation of Cisplatin (dose reduced), Pemetrexed and Pembrolizumab.

January 12, 2024: Follow-up CT scan abdomen and chest, FDG-PET-CT: Progressive Disease with three new metastases in the right lung and additional enlarged FDG-positive lymph nodes in the mediastinum. MRI scan of the brain conducted; no evidence of metastatic disease. Incidental findings included mild age-related cerebral atrophy and scattered white matter hyperintensities consistent with chronic microvascular ischemic changes.

March 17, 2024: Tumorboard recommends considering clinical trial options due to limited response to standard therapies.

April 20, 2024: Detailed assessment of health status. ECOG performance status 1. All routine labs, including liver and renal function tests, within normal limits.

#### ===== Patient 6.2.1 =====

#### Patient Information

Name: Ehrich, Wolfgang

born: 18.08.1968

Address: Kurfürstendamm 1, Berlin, Germany

## Overview of Tumor Diagnosis and Therapy

### Tumor Diagnosis

Diagnosis: UICC Stage IVB, M1c (brain metastases),  
KRAS G12C mutant non-small cell lung cancer (NSCLC)

Initial Detection: March 22, 2023, following symptoms of persistent cough and weight loss

Biopsy Date: April 15, 2023, squamous cell lung cancer, PDL1 3%

Molecular Profile: Molecular alterations: KRAS p.G12C (AF 18%), KRAS p.G12C (AF 18%), KEAP1 p.L276F (AF 45%), STK11 p.K83Tfs\*13 (AF 38%).

### Therapy Overview

Combined Immuno-chemotherapy: Began May 5, 2023, with Cisplatin,

Pemetrexed and Pembrolizumab, partial response noted after cycle completion by August 10, 2023, continuation of therapy until October 2023 (progressive disease)

### Current Status

Health Condition: Stable with an ECOG performance status of 1

### Comorbidities

Former Smoker: 40 py  
Hypertension Stage I  
COPD GOLD 2  
Type 2 Diabetes Mellitus  
Hyperlipidemia

### Medication

Lisinopril 20mg 1-0-0  
Metformin 1000mg 1-0-1  
Atorvastatin 40mg 0-0-0-1

Tiotropium (Inhaler) on demand

Novalgín 500mg 1-1-1-1

Apixaban 5mg 1-0-1

### **Chronological Medical Findings:**

March 22, 2023: Experienced persistent cough and weight loss. Chest X-ray and CT scan revealed a mass in the left lung. Referred to oncologist. CT-Angiography: Tumor Size: Approximately 4.5 cm in diameter. At least 2 contralateral metastases. Bronchial Obstruction: Partial obstruction of the left main bronchus leading to atelectasis of the left upper lobe. Suspicion of mediastinal lymph node metastases. No evidence of pulmonary artery embolism. Thrombus in the left atrium at the transition to the auricle. Emphysematous and fibrotic changes in the lung parenchyma. Urgent suspicion of a tumor-atelectasis complex in the left upper lobe of the lung. Mucus present in the lower lobe bronchi on the left. Lymph Nodes: Enlarged, FDG-positive lymph nodes in the mediastinum, particularly in regions 4R and infracarinal.

April 15, 2023: Lung biopsy via bronchoscopy: Endobronchial tumor manifestation in the distal left main bronchus extending to the upper lobe. Acute and chronic atrophic tracheobronchitis. Collapsed bronchial system in the affected area. Biopsy taken. Diagnosed with squamous non-small cell lung cancer (NSCLC), molecular diagnostics: KRAS G12C mutant.

April 27, 2023: Ventilation: Moderate obstruction, no restriction. Increased airway resistance and slight hyperinflation. Tiffeneau index (FEV1/FVC) at 42.34%, z-score -3.32. FEV1: 0.93 L (42% predicted), z-score -2.89. Total lung capacity (TLC): 5.86 L (103% predicted), z-score 0.22. Forced vital capacity (FVC): 2.19 L, z-score -1.5. Residual volume (RV): 3.67 L, z-score 2.44. RV/TLC: 62.68%, z-score -1.18.

May 5, 2023: Initiated on platinum-based immunochemotherapy regimen (Cisplatin, Pemetrexed, Pembrolizumab).

August 10, 2023: Completed initial therapy cycle. Partial response as per CT chest / abdomen +PET CT: Moderate reduction in tumor size to approximately 4.2 cm. Contralateral metastases still present, but no new lesions. Partial bronchial obstruction persists with ongoing atelectasis in the left upper lobe. Mediastinal lymph nodes remain enlarged and FDG-positive, although with reduced metabolic activity. Thrombus in the left atrium remains unchanged. Emphysematous and fibrotic changes are stable. Overall, mild response observed with no significant progression, as per RECIST stable disease.

August-October: Continued chemotherapy with Cisplatin/Pemetrexed and Pembrolizumab.

October 13, 2023: Follow-up CT (chest + abdomen): SD / Progressive Disease. New nodule in the right lung (1cm). Slight increase in the size of previously noted FDG-positive lymph nodes in the mediastinum. No additional metastatic lesions were detected. The patient has continued to

tolerate the current treatment regimen well, with no significant adverse effects reported.

October 17, 2023: Tumor board: SD. Continuation of therapy.

October 25, 2023: Continuation of Cisplatin (dose reduced), Pemetrexed and Pembrolizumab.

January 12, 2024: Follow-up CT scan abdomen and chest, FDG-PET-CT: Progressive Disease with three new metastases in the right lung and additional enlarged FDG-positive lymph nodes in the mediastinum.

MRI scan of the brain: MRI scan of the brain revealed multiple

metastases, specifically three lesions in the left hemisphere:

one in the left frontal lobe,

one in the left parietal lobe, and one in the left occipital lobe.

January 16, 2024: Begin Sotorasib (Lumakras) 960 per day

March 17, 2024: Tumorboard recommends considering clinical trial options due to limited response to standard therapies.

April 20, 2024: Detailed assessment of health status. ECOG performance status 1. All routine labs, including liver and renal function tests, within normal limits.

### ===== Patient 6.3 =====

#### Patient Information

Name: Ehrich, Wolfgang

born: 18.08.1968

Address: Italy

#### Overview of Tumor Diagnosis and Therapy

##### Tumor Diagnosis

Diagnosis: UICC Stage IVA, M1a (contralateral metastases), KRAS G12C mutant non-small cell lung cancer (NSCLC) / adenocarcinoma of the lung

Initial Detection: March 22, 2024, following symptoms of persistent cough and weight loss (-5kg)

Biopsy Date: April 15, 2024, adenocarcinoma, PDL1 3%

Molecular Profile: Molecular alterations: KRAS p.G12C (AF 18%), KRAS p.G12C (AF 18%), KEAP1 p.L276F (AF 45%), STK11 p.K83Tfs\*13 (AF 38%).

### Therapy Overview

None.

### Current Status

Health Condition: Stable with an ECOG performance status of 1

**Allergies:** None.

### Comorbidities

Former Smoker: 40 py  
Hypertension Stage I  
COPD GOLD 2  
Type 2 Diabetes Mellitus  
Hyperlipidemia

### Medication

Lisinopril 20mg 1-0-0  
Metformin 1000mg 1-0-1  
Atorvastatin 40mg 0-0-0-1  
Tiotropium (Inhaler) on demand  
Novalgin 500mg 1-1-1-1  
Apixaban 5mg 1-0-1

### Chronological Medical Findings:

**March 22, 2024:** Experienced persistent cough and weight loss. Chest X-ray and CT scan revealed a mass in the left lung. Referred to oncologist. CT-Angiography: Tumor Size: Approximately 4.5 cm in diameter. At least 2 contralateral metastases. Bronchial Obstruction: Partial obstruction of the left main bronchus leading to atelectasis of the left upper lobe. Suspicion of mediastinal lymph node metastases. No evidence of pulmonary artery embolism. Thrombus in the left atrium at the transition to the auricle. Emphysematous and fibrotic changes in the lung parenchyma. Urgent suspicion of a tumor-atelectasis complex in the left upper lobe of the lung. Mucus present in the lower lobe bronchi on the left. Lymph Nodes: Enlarged, FDG-positive lymph nodes in the mediastinum, particularly in regions 4R and infracarinal.

**April 15, 2024:** Lung biopsy via bronchoscopy: Endobronchial tumor manifestation in the distal left main bronchus extending to the upper lobe.

Acute and chronic atrophic tracheobronchitis. Collapsed bronchial system in the affected area. Biopsy taken. Diagnosed with non-small cell lung cancer (NSCLC) (adenocarcinoma), molecular diagnostics: KRAS G12C mutant.

**April 27, 2024:** Ventilation: Moderate obstruction, no restriction. Increased airway resistance and slight hyperinflation. Tiffeneau index (FEV1/FVC) at 42.34%, z-score -3.32. FEV1: 0.93 L (42% predicted), z-score -2.89. Total lung capacity (TLC): 5.86 L (103% predicted), z-score 0.22. Forced vital capacity (FVC): 2.19 L, z-score -1.5. Residual volume (RV): 3.67 L, z-score 2.44. RV/TLC: 62.68%, z-score -1.18.

**April 20, 2024:** Detailed assessment of health status. ECOG performance status 1. All routine labs, including liver and renal function tests, within normal limits. Discussion in tumor board conference: palliative systemic treatment or clinical trial enrollment.

===== Patient 6.3.1 =====

**Patient Information**

Name: Ehrich, Wolfgang

born: 18.08.1968

Address: Italy

**Overview of Tumor Diagnosis and Therapy**

**Tumor Diagnosis**

Diagnosis: UICC Stage IVA, M1a (contralateral metastases, pleural effusions),

KRAS G12C mutant non-small cell lung cancer (NSCLC) / adenocarcinoma of the lung

Initial Detection: March 22, 2024, following symptoms of persistent cough and weight loss (-5kg)

Biopsy Date: April 15, 2024, adenocarcinoma, PDL1 3%

Molecular Profile: Molecular alterations: KRAS p.G12C (AF 18%), KRAS p.G12C (AF 18%), KEAP1 p.L276F (AF 45%), STK11 p.K83Tfs\*13 (AF 38%).

**Therapy Overview**

None.

**Current Status**

Health Condition: Stable with an ECOG performance status of 1

**Allergies:** None.

**Comorbidities**

Former Smoker: 40 py  
Hypertension Stage I  
COPD GOLD 2  
Type 2 Diabetes Mellitus  
Hyperlipidemia

**Medication**

Lisinopril 20mg 1-0-0  
Metformin 1000mg 1-0-1  
Atorvastatin 40mg 0-0-0-1  
Tiotropium (Inhaler) on demand  
Novalgin 500mg 1-1-1-1  
Apixaban 5mg 1-0-1

**Chronological Medical Findings:**

**March 22, 2024:** Experienced persistent cough and weight loss. Chest X-ray and CT scan revealed a mass in the left lung. Referred to oncologist. CT-Angiography: Tumor Size: Approximately 4.5 cm in diameter. At least 2 contralateral metastases. Bronchial Obstruction: Partial obstruction of the left main bronchus leading to atelectasis of the left upper lobe. Suspicion of mediastinal lymph node metastases. No evidence of pulmonary artery embolism. Thrombus in the left atrium at the transition to the auricle. Emphysematous and fibrotic changes in the lung parenchyma. Urgent suspicion of a tumor-atelectasis complex in the left upper lobe of the lung. Mucus present in the lower lobe bronchi on the left. Lymph Nodes: Enlarged, FDG-positive lymph nodes in the mediastinum, particularly in regions 4R and infracarinal. **Bilateral pleural effusions, additionally mild pericardial effusion.**

**April 15, 2024:** Lung biopsy via bronchoscopy: Endobronchial tumor manifestation in the distal left main bronchus extending to the upper lobe. Acute and chronic atrophic tracheobronchitis. Collapsed bronchial system in the affected area. Biopsy taken. Diagnosed with non-small cell lung cancer (NSCLC) (adenocarcinoma), molecular diagnostics: KRAS G12C mutant.

**April 27, 2024:** Ventilation: Moderate obstruction, no restriction. Increased airway resistance and slight hyperinflation. Tiffeneau index (FEV1/FVC) at 42.34%, z-score -3.32. FEV1: 0.93 L (42% predicted), z-score -2.89. Total lung capacity (TLC): 5.86 L (103% predicted), z-score

0.22. Forced vital capacity (FVC): 2.19 L, z-score -1.5. Residual volume (RV): 3.67 L, z-score 2.44. RV/TLC: 62.68%, z-score -1.18.

**April 20, 2024:** Detailed assessment of health status.

**ECOG performance status 2**. All routine labs, including liver and renal function tests, within normal limits. Discussion in tumor board conference: palliative systemic treatment or clinical trial enrollment.

## ===== Patient 6.4 =====

### Patient Information

Name: Ehrich, Wolfgang

born: 18.08.1968

Address: Kurfürstendamm 1, Berlin, Germany

### Overview of Tumor Diagnosis and Therapy

#### Tumor Diagnosis

Diagnosis: UICC Stage IVA, M1a (contralateral metastases, malignant pleural effusions),

KRAS G12C mutant non-small cell lung cancer (NSCLC)

Initial Detection: March 22, 2023, following symptoms of persistent cough and weight loss

Biopsy Date: April 15, 2023, squamous cell lung cancer, PDL1 3%

Molecular Profile: Molecular alterations: KRAS p.G12C (AF 18%), KRAS p.G12C (AF 18%), KEAP1 p.L276F (AF 45%), STK11 p.K83Tfs\*13 (AF 38%).

#### Therapy Overview

Combined Immuno-chemotherapy: Began May 5, 2023, with Cisplatin,

Pemetrexed and Pembrolizumab, partial response noted after cycle completion by August 10, 2023, continuation of therapy until October 2023 (progressive disease)

#### Current Status

Health Condition: Stable with an ECOG performance status of 1

#### Comorbidities



Former Smoker: 40 py  
Hypertension Stage I  
COPD GOLD 2  
Type 2 Diabetes Mellitus  
Hyperlipidemia

### Medication

Lisinopril 20mg 1-0-0  
Metformin 1000mg 1-0-1  
Atorvastatin 40mg 0-0-0-1  
Tiotropium (Inhaler) on demand  
Novalgine 500mg 1-1-1-1  
Apixaban 5mg 1-0-1

### Chronological Medical Findings:

March 22, 2023: Experienced persistent cough and weight loss. Chest X-ray and CT scan revealed a mass in the left lung. Referred to oncologist. CT-Angiography: Tumor Size: Approximately 4.5 cm in diameter. At least 2 contralateral metastases. Bronchial Obstruction: Partial obstruction of the left main bronchus leading to atelectasis of the left upper lobe. Suspicion of mediastinal lymph node metastases. No evidence of pulmonary artery embolism. Thrombus in the left atrium at the transition to the auricle. Emphysematous and fibrotic changes in the lung parenchyma. Urgent suspicion of a tumor-atelectasis complex in the left upper lobe of the lung. Mucus present in the lower lobe bronchi on the left. Lymph Nodes: Enlarged, FDG-positive lymph nodes in the mediastinum, particularly in regions 4R and infracarinal.

April 15, 2023: Lung biopsy via bronchoscopy: Endobronchial tumor manifestation in the distal left main bronchus extending to the upper lobe. Acute and chronic atrophic tracheobronchitis. Collapsed bronchial system in the affected area. Biopsy taken. Diagnosed with squamous non-small cell lung cancer (NSCLC), molecular diagnostics: KRAS G12C mutant.

April 27, 2023: Ventilation: Moderate obstruction, no restriction. Increased airway resistance and slight hyperinflation. Tiffeneau index (FEV1/FVC) at 42.34%, z-score -3.32. FEV1: 0.93 L (42% predicted), z-score -2.89. Total lung capacity (TLC): 5.86 L (103% predicted), z-score 0.22. Forced vital capacity (FVC): 2.19 L, z-score -1.5. Residual volume (RV): 3.67 L, z-score 2.44. RV/TLC: 62.68%, z-score -1.18.

May 5, 2023: Initiated on platinum-based immunochemotherapy regimen (Cisplatin, Pemetrexed, Pembrolizumab).

August 10, 2023: Completed initial therapy cycle. Partial response as per CT chest / abdomen +PET CT: Moderate reduction in tumor size to approximately 4.2 cm. Contralateral metastases still present, but no new lesions. Partial bronchial obstruction persists with ongoing atelectasis in the left upper lobe. Mediastinal lymph nodes remain enlarged and FDG-positive, although with reduced metabolic activity. Thrombus in the left atrium remains unchanged. Emphysematous and fibrotic changes are stable. Overall, mild response observed with no significant progression, as per RECIST stable disease.

August-October: Continued chemotherapy with Cisplatin/Pemetrexed and Pembrolizumab.

October 13, 2023: Follow-up CT (chest + abdomen): SD / Progressive Disease. New nodule in the right lung (1cm). Slight increase in the size of previously noted FDG-positive lymph nodes in the mediastinum. No additional metastatic lesions were detected. The patient has continued to tolerate the current treatment regimen well, with no significant adverse effects reported.

October 17, 2023: Tumor board: SD. Continuation of therapy.

October 25, 2023: Continuation of Cisplatin (dose reduced), Pemetrexed and Pembrolizumab.

January 12, 2024: Follow-up CT scan abdomen and chest, FDG-PET-CT: Progressive Disease with three new metastases in the right lung and additional enlarged FDG-positive lymph nodes in the mediastinum. Primary tumor 5.1 cm in diameter. MRI scan of the brain conducted; no evidence of metastatic disease. Incidental findings included mild age-related cerebral atrophy and scattered white matter hyperintensities consistent with chronic microvascular ischemic changes.

March 17, 2024: Tumorboard recommends considering clinical trial options due to limited response to standard therapies.

April 20, 2024: Detailed assessment of health status. ECOG performance status 1. All routine labs, including liver and renal function tests, within normal limits.

## ===== **Patient 7.1** =====

### **Patient Information**

Name: Jessica Smith

Born: August 10, 1982

Address: Hamburg, Germany

### **Overview of Tumor Diagnosis and Therapy**

#### **Tumor Diagnosis**

Diagnosis: UICC Stage IV metastatic malignant melanoma (hepatic, M. pectoralis major)

Initial Detection: January 5, 2024, following a rapidly growing mole and enlarged lymph nodes

Biopsy Date: January 15, 2024

Molecular Profile: Tumor Purity: 80%; Tumor Mutational Burden (TMB): 12.8 Mut/Mb; NF1 p.I1605fs (AF 39%), TP53 c.672+1G>A (AF 50%), RB1 p.Q846\* (AF 20%), TERT p.R859Q (AF 41%)

### Therapy Overview

Initial Treatment: None so far.

**Health Condition:** ECOG 1

### Comorbidities

Former smoker 10 py  
Hypertension Stage 1  
Mild Asthma  
H/o appendectomy 2014

### Medication

Amlodipine 10mg 1-0-0  
Albuterol inhaler as needed

### Chronological Medical Findings:

**January 5, 2024:** Presented with a rapidly growing mole on the left arm and enlarged lymph nodes in the axillary region.

**January 10, 2024:** CT scan of the chest and abdomen: Solid tumor in the left axillary region measuring approximately 3.5 cm with evidence of local invasion into surrounding soft tissues and possibly the pectoralis major muscle. Demonstrates irregular borders and heterogeneous enhancement. Multiple hypodense lesions noted throughout the liver, suggestive of metastatic disease. The largest lesion is located in segment VIII, measuring approximately 2.8 cm in diameter. Additional smaller lesions scattered in both hepatic lobes.

**January 15, 2024:** Biopsy of the left axillary mass performed. Histology confirmed melanoma. Molecular panel sequencing: NF1 p.I1605fs (AF 39%), TP53 c.672+1G>A (AF 50%), RB1 p.Q846\* (AF 20%), TERT p.R859Q (AF 41%). Tumor purity 80%. Tumor Mutational Burden (TMB) 12.8 Mut/Mb.

**January 16, 2024:** Detailed assessment of health status confirmed adequate organ function. Routine labs within normal limits: ANC 5,300/mcL, platelet count 140,000/mcL, total bilirubin 1.1 mg/dL, AST/ALT within range, creatinine 1.1 mg/dL, hemoglobin 10.5 g/dL, serum albumin 3.4 g/dL, lipase and amylase within normal limits.

===== **Patient 7.1.1** =====

### **Patient Information**

Name: Jessica Smith  
Born: August 10, 1982  
Address: Hamburg, Germany

### **Overview of Tumor Diagnosis and Therapy**

#### **Tumor Diagnosis**

Diagnosis: UICC Stage IV metastatic malignant melanoma (HEP, M. pectoralis major)

Initial Detection: January 5, 2024, following a rapidly growing mole and enlarged lymph nodes

Biopsy Date: January 15, 2024

Molecular Profile: Tumor Purity: 80%; Tumor Mutational Burden (TMB): 12.8 Mut/Mb; NF1 p.I1605fs (AF 39%), TP53 c.672+1G>A (AF 50%), RB1 p.Q846\* (AF 20%), TERT p.R859Q (AF 41%)

#### **Therapy Overview**

Initial Treatment:

Immunotherapy: Began February 1, 2024, with Nivolumab and Ipilimumab, partial response noted

after the initial treatment cycle completed by May 15, 2024.

Continued Nivolumab maintenance until December 2024 (progressive disease).

**Current Status:** Disease progression as of December 2024, with new metastatic lesions identified.

**Health Condition:** ECOG 1

#### **Comorbidities**

Former smoker 10 py  
Hypertension Stage 1  
Mild Asthma  
H/o appendectomy 2014

#### **Medication**

Amlodipine 10mg 1-0-0  
Albuterol inhaler as needed

#### **Chronological Medical Findings:**

**January 5, 2023:** Presented with a rapidly growing mole on the left arm and enlarged lymph nodes in the axillary region.

**January 10, 2023:** CT scan of the chest and abdomen: Solid tumor in the left axillary region measuring approximately 3.5 cm with evidence of local invasion into surrounding soft tissues and possibly the pectoralis major muscle. Demonstrates irregular borders and heterogeneous enhancement. Multiple hypodense lesions noted throughout the liver, suggestive of metastatic disease. The largest lesion is located in segment VIII, measuring approximately 2.8 cm in diameter. Additional smaller lesions scattered in both hepatic lobes.

**January 15, 2023:** Biopsy of the left axillary mass performed. Histology confirmed melanoma. Molecular panel sequencing: NF1 p.I1605fs (AF 39%), TP53 c.672+1G>A (AF 50%), RB1 p.Q846\* (AF 20%), TERT p.R859Q (AF 41%). Tumor purity 80%. Tumor Mutational Burden (TMB) 12.8 Mut/Mb.

**February 1, 2023:** Initiated combined immunotherapy with Nivolumab and Ipilimumab.

**May 5, 2023:** CT scan showed partial response with a decrease in the size of the primary tumor and axillary lymph nodes. Partial response also regarding liver mets. Continued maintenance therapy with Nivolumab.

**September 15, 2023:** Follow-up imaging: SD.

**September - December 2023:** Continuation of Nivolumab.

**December 18, 2023:** Follow-up CT scan: Disease progression with new metastatic lesions in the liver and bones. Multiple enlarged lymph nodes persistent in the left axillary region, consistent with known metastatic melanoma. No significant change in size or number compared to the previous scan. Liver demonstrates multiple hypodense lesions throughout both hepatic lobes. The large lesion located in segment VIII now measures approximately 5.0 cm in diameter. Previously noted lesions have increased in size, with the largest lesion in segment IVa now measuring 4.2 cm (previously 3.1 cm). New lytic lesions are identified in the thoracic spine, specifically at T5 and T8 vertebral bodies, suggestive of metastatic disease.

**December 21, 2023:** Bone scan confirmed multiple metastatic lesions in the thoracic spine.

**January 4, 2024:** Tumor board review recommended considering eligibility for clinical trials due to limited response to standard and investigational therapies.

**January 16, 2024:** Detailed assessment of health status confirmed adequate organ function. Routine labs within normal limits: ANC 5,300/mcL, platelet count

140,000/mcL, total bilirubin 1.1 mg/dL, AST/ALT within range, creatinine 1.1 mg/dL, hemoglobin 10.5 g/dL, serum albumin 3.4 g/dL, lipase and amylase within normal limits.

===== Patient 7.1.2 =====

**Patient Information**

Name: Jessica Smith  
Born: August 10, 1982  
Address: Hamburg, Germany

**Overview of Tumor Diagnosis and Therapy**

**Tumor Diagnosis**

Diagnosis: IICC Stage IV metastatic malignant melanoma (hepatic, M. pectoralis major, Bone)

Initial Detection: January 5, 2024, following a rapidly growing mole and enlarged lymph nodes

Biopsy Date: January 15, 2024

Molecular Profile: Tumor Purity: 80%; Tumor Mutational Burden (TMB): 12.8 Mut/Mb; NF1 p.I1605fs (AF 39%), TP53 c.672+1G>A (AF 50%), RB1 p.Q846\* (AF 20%), TERT p.R859Q (AF 41%)

**Therapy Overview**

Initial Treatment: None so far.

**Health Condition:** ECOG 1

**Comorbidities**

Former smoker 10 py  
Hypertension Stage 1  
Mild Asthma  
H/o appendectomy 2014

Systemic Lupus Erythematosus (SLE) diagnosed in 2022,  
presenting with joint pain, fatigue, and a malar rash

**Medication**

Hydroxychloroquine 200 mg, once daily  
Prednisone 5 mg, once daily  
Amlodipine 10mg 1-0-0  
Albuterol inhaler as needed

**Chronological Medical Findings:**

**January 5, 2024:** Presented with a rapidly growing mole on the left arm and enlarged lymph nodes in the axillary region.

**January 10, 2024:** CT scan of the chest and abdomen: Solid tumor in the left axillary region measuring approximately 3.5 cm with evidence of local invasion into surrounding soft tissues and possibly the pectoralis major muscle. Demonstrates irregular borders and heterogeneous enhancement. Multiple hypodense lesions noted throughout the liver, suggestive of metastatic disease. The largest lesion is located in segment VIII, measuring approximately 2.8 cm in diameter. Additional smaller lesions scattered in both hepatic lobes.

**January 15, 2024:** Biopsy of the left axillary mass performed. Histology confirmed melanoma. Molecular panel sequencing: NF1 p.I1605fs (AF 39%), TP53 c.672+1G>A (AF 50%), RB1 p.Q846\* (AF 20%), TERT p.R859Q (AF 41%). Tumor purity 80%. Tumor Mutational Burden (TMB) 12.8 Mut/Mb.

**January 16, 2024:** Detailed assessment of health status confirmed adequate organ function. Routine labs within normal limits: ANC 5,300/mcL, platelet count 140,000/mcL, total bilirubin 1.1 mg/dL, AST/ALT within range, creatinine 1.1 mg/dL, hemoglobin 10.5 g/dL, serum albumin 3.4 g/dL, lipase and amylase within normal limits.

### ===== **Patient 7.1.3** =====

#### **Patient Information**

Name: Jessica Smith  
Born: August 10, 1982  
Address: Hamburg, Germany

#### **Overview of Tumor Diagnosis and Therapy**

##### **Tumor Diagnosis**

Diagnosis: UICC Stage IV metastatic malignant melanoma (hepatic, M. pectoralis major, brain)

Initial Detection: January 5, 2024, following a rapidly growing mole and enlarged lymph nodes

Biopsy Date: January 15, 2024

Molecular Profile: Tumor Purity: 80%; Tumor Mutational Burden (TMB): 12.8 Mut/Mb; NF1 p.I1605fs (AF 39%), TP53 c.672+1G>A (AF 50%), RB1 p.Q846\* (AF 20%), TERT p.R859Q (AF 41%)

##### **Therapy Overview**

Initial Treatment: None so far.

**Health Condition:** ECOG 1

##### **Comorbidities**

Former smoker 10 py

Hypertension Stage 1  
Mild Asthma  
H/o appendectomy 2014

Systemic Lupus Erythematosus (SLE) diagnosed in 2022,  
presenting with joint pain, fatigue, and a malar rash

#### Medication

Hydroxychloroquine 200 mg, once daily  
Prednisone 5 mg, once daily  
Amlodipine 10mg 1-0-0  
Albuterol inhaler as needed

#### Chronological Medical Findings:

**January 5, 2024:** Presented with a rapidly growing mole on the left arm and enlarged lymph nodes in the axillary region.

**January 10, 2024:** CT scan of the chest and abdomen: Solid tumor in the left axillary region measuring approximately 3.5 cm with evidence of local invasion into surrounding soft tissues and possibly the pectoralis major muscle. Demonstrates irregular borders and heterogeneous enhancement. Multiple hypodense lesions noted throughout the liver, suggestive of metastatic disease. The largest lesion is located in segment VIII, measuring approximately 2.8 cm in diameter. Additional smaller lesions scattered in both hepatic lobes.

cMRI: Imaging reveals five small brain metastases:

A 1.2 cm lesion in the right frontal lobe.

A 0.8 cm lesion in the left parietal lobe. A 0.6 cm lesion in the right occipital lobe.

A 0.7 cm lesion in the left cerebellum. A 0.9 cm lesion in the right temporal lobe.

All lesions with heterogeneous enhancement and associated with surrounding vasogenic edema.

No evidence of midline shift or significant mass effect at this time.

**January 15, 2024:** Biopsy of the left axillary mass performed. Histology confirmed melanoma. Molecular panel sequencing: NF1 p.I1605fs (AF 39%), TP53 c.672+1G>A (AF 50%), RB1 p.Q846\* (AF 20%), TERT p.R859Q (AF 41%). Tumor purity 80%. Tumor Mutational Burden (TMB) 12.8 Mut/Mb.

**January 16, 2024:** Detailed assessment of health status confirmed adequate organ function. Routine labs within normal limits: ANC 5,300/mcL, platelet count 140,000/mcL, total bilirubin 1.1 mg/dL, AST/ALT within range, creatinine 1.1 mg/dL, hemoglobin 10.5 g/dL, serum albumin 3.4 g/dL, lipase and amylase within normal limits.

===== **Patient 7.2** =====



### **Patient Information**

Name: Jessica Smith

Born: August 10, 1982

Address: Hamburg, Germany

### **Overview of Tumor Diagnosis and Therapy**

#### **Tumor Diagnosis**

**Diagnosis:** UICC Stage IV metastatic malignant melanoma (hepatic, M. pectoralis major)

**Initial Detection:** January 5, 2024, following a rapidly growing mole and enlarged lymph nodes

**Biopsy Date:** January 15, 2024

**Molecular Profile:** Tumor Purity: 80%; Tumor Mutational Burden (TMB): 12.8 Mut/Mb; NF1 p.I1605fs (AF 39%), TP53 c.672+1G>A (AF 50%), RB1 p.Q846\* (AF 20%), TERT p.R859Q (AF 41%)

#### **Therapy Overview**

**Initial Treatment:** None so far.

**Health Condition:** ECOG 1

#### **Comorbidities**

Former smoker 10 py

Hypertension Stage 1

Mild Asthma

H/o appendectomy 2014

Medication

Amlodipine 10mg 1-0-0

Albuterol inhaler as needed

#### **Chronological Medical Findings:**

**January 5, 2024:** Presented with a rapidly growing mole on the left arm and enlarged lymph nodes in the axillary region.

**January 10, 2024:** CT scan of the chest and abdomen: Solid tumor in the left axillary region measuring approximately 3.5 cm with evidence of local invasion into surrounding soft tissues and possibly the pectoralis major muscle. Demonstrates irregular borders

and heterogeneous enhancement. Multiple hypodense lesions noted throughout the liver, suggestive of metastatic disease. The largest lesion is located in segment VIII, measuring approximately 2.8 cm in diameter. Additional smaller lesions scattered in both hepatic lobes.

**January 15, 2024:** Biopsy of the left axillary mass performed. Histology confirmed melanoma. Molecular panel sequencing: NF1 p.I1605fs (AF 39%), TP53 c.672+1G>A (AF 50%), RB1 p.Q846\* (AF 20%), TERT p.R859Q (AF 41%). Tumor purity 80%. Tumor Mutational Burden (TMB) 12.8 Mut/Mb.

**January 16, 2024:** Detailed assessment of health status confirmed adequate organ function. Routine labs within normal limits: ANC 5,300/mcL, platelet count 140,000/mcL, total bilirubin 1.1 mg/dL, AST/ALT within range, creatinine 1.1 mg/dL, hemoglobin 10.5 g/dL, serum albumin 3.4 g/dL, lipase and amylase within normal limits.

#### ===== Patient 7.2.1 =====

##### **Patient Information**

Name: Jessica Smith  
Born: August 10, 1982  
Address: Hamburg, Germany

##### **Overview of Tumor Diagnosis and Therapy**

###### **Tumor Diagnosis**

Diagnosis: UICC Stage IV metastatic malignant melanoma (hepatic, M. pectoralis major, brain)

Initial Detection: January 5, 2024, following a rapidly growing mole and enlarged lymph nodes

Biopsy Date: January 15, 2024

Molecular Profile: Tumor Purity: 80%; Tumor Mutational Burden (TMB): 12.8 Mut/Mb; NF1 p.I1605fs (AF 39%), TP53 c.672+1G>A (AF 50%), RB1 p.Q846\* (AF 20%), TERT p.R859Q (AF 41%)

###### **Therapy Overview**

Initial Treatment: None so far.

**Health Condition:** ECOG 1

###### **Comorbidities**

Former smoker 10 py  
Hypertension Stage 1  
Mild Asthma  
H/o appendectomy 2014

Systemic Lupus Erythematosus (SLE) diagnosed in 2022,  
presenting with joint pain, fatigue, and a malar rash

### Medication

Hydroxychloroquine 200 mg, once daily Prednisone 5 mg, once daily  
Amlodipine 10mg 1-0-0  
Albuterol inhaler as needed

### Chronological Medical Findings:

**January 5, 2024:** Presented with a rapidly growing mole on the left arm and enlarged lymph nodes in the axillary region.

**January 10, 2024:** CT scan of the chest and abdomen: Solid tumor in the left axillary region measuring approximately 3.5 cm with evidence of local invasion into surrounding soft tissues and possibly the pectoralis major muscle. Demonstrates irregular borders and heterogeneous enhancement. Multiple hypodense lesions noted throughout the liver, suggestive of metastatic disease. The largest lesion is located in segment VIII, measuring approximately 2.8 cm in diameter. Additional smaller lesions scattered in both hepatic lobes.

cMRI: Imaging reveals five small brain metastases:

A 1.2 cm lesion in the right frontal lobe.

A 0.8 cm lesion in the left parietal lobe. A 0.6 cm lesion in the right occipital lobe.

A 0.7 cm lesion in the left cerebellum. A 0.9 cm lesion in the right temporal lobe.

All lesions with heterogeneous enhancement and associated with surrounding vasogenic edema.

No evidence of midline shift or significant mass effect at this time.

**January 15, 2024:** Biopsy of the left axillary mass performed. Histology confirmed melanoma. Molecular panel sequencing: NF1 p.I1605fs (AF 39%), TP53 c.672+1G>A (AF 50%), RB1 p.Q846\* (AF 20%), TERT p.R859Q (AF 41%). Tumor purity 80%. Tumor Mutational Burden (TMB) 12.8 Mut/Mb.

**January 16, 2024:** Detailed assessment of health status confirmed adequate organ function. Routine labs within normal limits: ANC 5,300/mcL, platelet count 140,000/mcL, total bilirubin 1.1 mg/dL, AST/ALT within range, creatinine 1.1 mg/dL, hemoglobin 10.5 g/dL, serum albumin 3.4 g/dL, lipase and amylase within normal limits.

### ==== Patient 8.1 =====

Name: Müller, David  
Born: 22.03.1970  
Address: Hauptstraße 1, Heidelberg, Germany

## Overview of Tumor Diagnosis and Therapy

### Tumor Diagnosis

Diagnosis: UICC Stage IV FGFR2 mutant intrahepatic cholangiocarcinoma, peritoneal carcinomatosis

Initial Detection: March 5 2022, following symptoms of jaundice and abdominal pain

Molecular Profile: Panel (Tumor purity 80%), TMB 1.2 Mut/Mb. Molecular alterations: FGFR2::BICC1 Fusion, TP53 p.E258\* (AF 52%).

### Therapy Overview

Initial Treatment:

Right hemihepatectomy with additional lymphadenectomy June 10, 2023. Histopathology: iCCA, T1b, N1, R0 resection.

Adjuvant chemotherapy: Began June 20, 2023, with Capecitabine. Follow-up CT September 2023 shows multiple new liver lesions and peritoneal metastasis.

Subsequent Treatment:

September - December 2023: 6 cycles Gemzar/Cisplatin + Durvalumab.

January - March 2024: Second line chemotherapy with FOLFOX.

Current Status: ECOG 1

### Comorbidities

Hypothyroidism

### Medication

Levothyroxine 75µg 1-0-0

### Chronological Medical Findings:

**February 1, 2023:** Complaint of jaundice and abdominal pain. Ultrasound revealed a mass in the liver. Weight loss of -15kg/5 months.

**March 5, 2023:** MRI of the abdomen: Significant mass measuring approximately 5.5 cm in the right hepatic lobe, consistent with intrahepatic cholangiocarcinoma. Lesion with irregular borders and heterogeneous enhancement patterns. Evidence of bile duct dilation proximal to the mass, suggestive of obstructive cholestasis. Additionally, several enlarged lymph nodes noted in the perihepatic region, displaying increased uptake on FDG-PET, suggestive of potential metastasis. No vascular invasion observed, but the proximity of the mass to the right portal vein concerning for possible future involvement. No signs of distant metastasis present in the visualized organs.

**June 10, 2023:** Right hemihepatectomy and lymphadenectomy. Histopathology reveals intrahepatic cholangiocarcinoma. pT1b, pN2, pM0, R0. Molecular pathol-

ogy report: Panel (Tumor purity 80%), TMB 1.2 Mut/Mb. Molecular alterations: FGFR2::BICC1 Fusion, TP53 p.E258\* (AF 52%).

**June 20, 2023:** DPD status normal. Initiated adjuvant chemotherapy with Capecitabine.

**September 15, 2023:** Follow-up CT (chest + abdomen): Multiple new lesions in the remaining liver tissue, highly suggestive of tumor recurrence. New small nodules in the peritoneum, up to 1 cm, likely peritoneal metastasis. FDG-PET shows elevated activity in hepatic and lymph node lesions. Mild right-sided pleural effusion noted, no significant respiratory compromise.

**September 17, 2023:** Initiated Therapy with Gemzar/Cisplatin + Durvalumab.

**September - December 2023:** 6 cycles Gemzar/Cisplatin + Durvalumab.

**January 5, 2024:** Follow-up MRI scan abdomen/liver: progressive disease (PD) with growth of all liver lesions and increased involvement of adjacent hepatic structures. The peritoneal nodules showed slight growth. Moderate ascites. No evidence of direct vascular invasion, but the tumor's close relationship with the hepatic artery and portal vein concerns potential future involvement. The liver parenchyma shows signs of chronic liver disease, possibly secondary to ongoing cholestasis and tumor-related liver dysfunction.

MRI of the brain was conducted concurrently, revealing no evidence of metastatic disease. Incidental findings included mild age-related cerebral atrophy and scattered white matter hyperintensities, consistent with chronic microvascular ischemic changes.

**January - March 2024:** Second line chemotherapy with FOLFOX.

**March 16, 2024:** Progressive disease (PD) with significant growth of all liver lesions. The largest lesion in segment IVb has increased to 7.5 cm in diameter, with invasion into the adjacent hepatic structures. The peritoneal nodules have shown further growth, with the largest nodule now measuring 2.5 cm. Ascites: Moderate to severe ascites is present, with a noticeable increase compared to the previous scan. Vascular Involvement: No direct vascular invasion detected yet, but the lesions now encase the hepatic artery and portal vein, raising significant concerns for potential imminent involvement. Liver Parenchyma: The liver parenchyma shows worsening signs of chronic liver disease, likely secondary to ongoing cholestasis and tumor-related liver dysfunction. Evidence of hepatic decompensation is apparent, with diffuse nodularity and fibrosis indicative of cirrhosis.

Additional Findings: Splenomegaly, consistent with portal hypertension.

**January 20, 2024:** Tumor board recommends considering clinical trial options due to limited response to standard therapies.

**January 21, 2024:** Patient in good shape, routine lab results within normal ranges. Willing to participate in potential trials.

===== Patient 8.1.1 =====

Name: Müller, David  
Born: 22.03.1970  
Address: Hauptstraße 1, Heidelberg, Germany

### Overview of Tumor Diagnosis and Therapy

#### Tumor Diagnosis

Diagnosis: UICC Stage IV FGFR2 mutant intrahepatic cholangiocarcinoma, peritoneal carcinomatosis

Initial Detection: March 5 2022, following symptoms of jaundice and abdominal pain

Molecular Profile: Panel (Tumor purity 80%), TMB 1.2 Mut/Mb. Molecular alterations: FGFR2::BICC1 Fusion, TP53 p.E258\* (AF 52%).

#### Therapy Overview

Initial Treatment:

Right hemihepatectomy with additional lymphadenectomy June 10, 2023. Histopathology: iCCA, T1b, N1, R0 resection.

Adjuvant chemotherapy: Began June 20, 2023, with Capecitabine. Follow-up CT September 2023 shows multiple new liver lesions and peritoneal metastasis.

Subsequent Treatment:

September - December 2023: 6 cycles Gemzar/Cisplatin + Durvalumab.

January - March 2024: Second line chemotherapy with FOLFOX.

Current Status: ECOG 1

#### Comorbidities

Hypothyroidism

Coronary Artery Disease (CAD)

Status post Myocardial Infarction (MI) on January 10, 2024

ECG January 10, 2024: ST-segment elevation in leads V2-V4,

consistent with anterior wall myocardial infarction.

Reciprocal ST-segment depression in leads II, III, and aVF.

Q waves present in leads VI-V3, indicating myocardial necrosis.

T-wave inversions in leads V2-V4.

QTc time of 485 ms.

Heart rate: 95 bpm. PR interval: 160 ms. QRS duration: 100 ms.

#### Medication

Levothyroxine 75µg 1-0-0

Ass 100, once daily

Clopidogrel 75 mg, once daily

Atorvastatin 80 mg, once daily

Metoprolol 50 mg, twice daily

Lisinopril 10 mg, once daily

#### **Chronological Medical Findings:**

**February 1, 2023:** Complaint of jaundice and abdominal pain. Ultrasound revealed a mass in the liver. Weight loss of -15kg/5 months.

**March 5, 2023:** MRI of the abdomen: Significant mass measuring approximately 5.5 cm in the right hepatic lobe, consistent with intrahepatic cholangiocarcinoma. Lesion with irregular borders and heterogeneous enhancement patterns. Evidence of bile duct dilation proximal to the mass, suggestive of obstructive cholestasis. Additionally, several enlarged lymph nodes noted in the perihepatic region, displaying increased uptake on FDG-PET, suggestive of potential metastasis. No vascular invasion observed, but the proximity of the mass to the right portal vein concerning for possible future involvement. No signs of distant metastasis present in the visualized organs.

**June 10, 2023:** Right hemihepatectomy and lymphadenectomy. Histopathology reveals intrahepatic cholangiocarcinoma. pT1b, pN2, pM0, R0. Molecular pathology report: Panel (Tumor purity 80%), TMB 1.2 Mut/Mb. Molecular alterations: FGFR2::BICC1 Fusion, TP53 p.E258\* (AF 52%).

**June 20, 2023:** DPD status normal. Initiated adjuvant chemotherapy with Capecitabine.

**September 15, 2023:** Follow-up CT (chest + abdomen): Multiple new lesions in the remaining liver tissue, highly suggestive of tumor recurrence. New small nodules in the peritoneum, up to 1 cm, likely peritoneal metastasis. FDG-PET shows elevated activity in hepatic and lymph node lesions. Mild right-sided pleural effusion noted, no significant respiratory compromise.

**September 17, 2023:** Initiated Therapy with Gemzar/Cisplatin + Durvalumab.

**September - December 2023:** 6 cycles Gemzar/Cisplatin + Durvalumab.

**January 5, 2024:** Follow-up MRI scan abdomen/liver: progressive disease (PD) with growth of all liver lesions and increased involvement of adjacent hepatic structures. The peritoneal nodules showed slight growth. Moderate ascites. No evidence of direct vascular invasion, but the tumor's close relationship with the hepatic artery and portal vein concerns potential future involvement. The liver parenchyma shows signs of chronic liver disease, possibly secondary to ongoing cholestasis and tumor-related liver dysfunction.

MRI of the brain was conducted concurrently, revealing no evidence of metastatic disease. Incidental findings included mild age-related cerebral atrophy and scattered white matter hyperintensities, consistent with chronic microvascular ischemic changes.

**January - March 2024:** Second line chemotherapy with FOLFOX.

**March 16, 2024:** Progressive disease (PD) with significant growth of all liver lesions. The largest lesion in segment IVb has increased to 7.5 cm in diameter, with invasion into the adjacent hepatic structures. The peritoneal nodules have shown further growth, with the largest nodule now measuring 2.5 cm. Ascites: Moderate to severe ascites is present, with a noticeable increase compared to the previous scan. Vascular Involvement: No direct vascular invasion detected yet, but the lesions now encase the hepatic artery and portal vein, raising significant concerns for potential imminent involvement. Liver Parenchyma: The liver parenchyma shows worsening signs of chronic liver disease, likely secondary to ongoing cholestasis and tumor-related liver dysfunction. Evidence of hepatic decompensation is apparent, with diffuse nodularity and fibrosis indicative of cirrhosis.

Additional Findings: Splenomegaly, consistent with portal hypertension.

**January 10, 2024:**

Patient presented with severe chest pain.

Diagnosed with an acute myocardial infarction.

Underwent emergency coronary angiography, revealing 90%

Occlusion in the LAD and 70% occlusion in the RCA.

Two DES stents placed. Started on aspirin, clopidogrel, atorvastatin, metoprolol, and lisinopril.

**January 20, 2024:** Tumor board recommends considering clinical trial options due to limited response to standard therapies.

**January 21, 2024:** Patient in good shape, routine lab results within normal ranges. Willing to participate in potential trials.

===== Patient 8.1.2 =====

Name: Müller, David

Born: 22.03.1970

Address: Hauptstraße 1, Heidelberg, Germany

### Overview of Tumor Diagnosis and Therapy

#### Tumor Diagnosis

Diagnosis: UICC Stage IV FGFR2 mutant intrahepatic cholangiocarcinoma, peritoneal carcinomatosis

Initial Detection: March 5 2022, following symptoms of jaundice and abdominal pain

Molecular Profile: Panel (Tumor purity 80%), TMB 1.2 Mut/Mb. Molecular alterations: FGFR2::BICC1 Fusion, TP53 p.E258\* (AF 52%).

#### Therapy Overview

Initial Treatment:

Right hemihepatectomy with additional lymphadenectomy June 10, 2023. Histopathology: iCCA, T1b, N1, R0 resection.



Adjuvant chemotherapy: Began June 20, 2023, with Capecitabine. Follow-up CT September 2023 shows multiple new liver lesions and peritoneal metastasis.

Subsequent Treatment:

September - December 2023: 6 cycles Gemzar/Cisplatin + Durvalumab.

January - March 2024: Second line chemotherapy with FOLFOX.

Current Status: ECOG 1

### Comorbidities

Hypothyroidism

Hepatitis C

### Medication

Levothyroxine 75µg 1-0-0

Sofosbuvir 400 mg, once daily Velpatasvir 100 mg, once daily

### Chronological Medical Findings:

**February 1, 2023:** Complaint of jaundice and abdominal pain. Ultrasound revealed a mass in the liver. Weight loss of -15kg/5 months.

**March 5, 2023:** MRI of the abdomen: Significant mass measuring approximately 5.5 cm in the right hepatic lobe, consistent with intrahepatic cholangiocarcinoma. Lesion with irregular borders and heterogeneous enhancement patterns. Evidence of bile duct dilation proximal to the mass, suggestive of obstructive cholestasis. Additionally, several enlarged lymph nodes noted in the perihepatic region, displaying increased uptake on FDG-PET, suggestive of potential metastasis. No vascular invasion observed, but the proximity of the mass to the right portal vein concerning for possible future involvement. No signs of distant metastasis present in the visualized organs.

**June 10, 2023:** Right hemihepatectomy and lymphadenectomy. Histopathology reveals intrahepatic cholangiocarcinoma. pT1b, pN2, pM0, R0. Molecular pathology report: Panel (Tumor purity 80%), TMB 1.2 Mut/Mb. Molecular alterations: FGFR2::BICC1 Fusion, TP53 p.E258\* (AF 52%).

**June 20, 2023:** DPD status normal. Initiated adjuvant chemotherapy with Capecitabine.

**September 15, 2023:** Follow-up CT (chest + abdomen): Multiple new lesions in the remaining liver tissue, highly suggestive of tumor recurrence. New small nodules in the peritoneum, up to 1 cm, likely peritoneal metastasis. FDG-PET shows elevated activity in hepatic and lymph node lesions. Mild right-sided pleural effusion noted, no significant respiratory compromise.

**September 17, 2023:** Initiated Therapy with Gemzar/Cisplatin + Durvalumab.

**September - December 2023:** 6 cycles Gemzar/Cisplatin + Durvalumab.

**January 5, 2024:** Follow-up MRI scan abdomen/liver: progressive disease (PD) with growth of all liver lesions and increased involvement of adjacent hepatic structures. The peritoneal nodules showed slight growth. Moderate ascites. No evidence of direct vascular invasion, but the tumor's close relationship with the hepatic artery and portal vein concerns potential future involvement. The liver parenchyma shows signs of chronic liver disease, possibly secondary to ongoing cholestasis and tumor-related liver dysfunction.

MRI of the brain was conducted concurrently, revealing no evidence of metastatic disease. Incidental findings included mild age-related cerebral atrophy and scattered white matter hyperintensities, consistent with chronic microvascular ischemic changes.

**January - March 2024:** Second line chemotherapy with FOLFOX.

**March 16, 2024:** Progressive disease (PD) with significant growth of all liver lesions. The largest lesion in segment IVb has increased to 7.5 cm in diameter, with invasion into the adjacent hepatic structures. The peritoneal nodules have shown further growth, with the largest nodule now measuring 2.5 cm. Ascites: Moderate to severe ascites is present, with a noticeable increase compared to the previous scan. Vascular Involvement: No direct vascular invasion detected yet, but the lesions now encase the hepatic artery and portal vein, raising significant concerns for potential imminent involvement. Liver Parenchyma: The liver parenchyma shows worsening signs of chronic liver disease, likely secondary to ongoing cholestasis and tumor-related liver dysfunction. Evidence of hepatic decompensation is apparent, with diffuse nodularity and fibrosis indicative of cirrhosis.

Additional Findings: Splenomegaly, consistent with portal hypertension.

**January 20, 2024:** Tumor board recommends considering clinical trial options due to limited response to standard therapies.

**January 21, 2024:** Patient progressively in bad shape, stays in bed almost all day, routine lab results within normal ranges. Willing to participate in potential trials.

===== Patient 9.1 =====

**Patient Information**

Name: Mueller, Max

Born: 25.03.1945

Address: 456 Oak Street, Hamburg, Germany

**Overview of Tumor Diagnosis and Therapy**

Tumor Diagnosis

Diagnosis: Stage IV salivary duct carcinoma

Initial Detection: June 10, 2023, following symptoms of persistent facial swelling and pain

Biopsy Date: July 5, 2023

Molecular Profile: Tumor Mutational Burden (TMB) of 10.5 Mut/Mb, HRAS p.Q61R (AF 44%), PIK3CA p.E545K (AF 39%), p.H1047R (AF 30%). HER2 FISH positive.

### **Therapy Overview**

Initial Treatment:

Chemotherapy: Initiated on August 1, 2023, with Docetaxel plus Trastuzumab. Partial response noted after three months.

Subsequent Treatment: Second-line chemotherapy with carboplatin and paclitaxel initiated on December 1, 2023, due to disease progression.

Current Status: Progressive disease with lymphatic, pulmonary and hepatic metastasis.

### **ECOG 1**

#### **Comorbidities**

Former smoker 30 py

Hypertension Stage 1

Type 2 Diabetes Mellitus

Hyperlipidemia

Benign Prostatic Hyperplasia (BPH)

#### **Medication**

Amlodipine 10 mg 1-0-0

Metformin 1000 mg 1-0-1

Empagliflozin 10mg 1-0-0

Atorvastatin 40 mg 0-0-0-1

Omeprazole 20 mg 1-0-0

Tamsulosin 0.4 mg 1-0-0

Fentanyl TTS 25 mcg every 3 days

Fentanyl s.l. 100 mcg as needed up to 4 times a day

Ibuprofen 600 1-1-1

#### **Chronological Medical Findings:**

**June 10, 2023:** Patient presented with persistent facial swelling and pain. A CT scan of the head and neck revealed a mass in the left parotid gland measuring approximately 5 cm with extensive local invasion into the surrounding soft tissues and suspected involvement of multiple regional lymph nodes in levels II and III

**June 12, 2023:** Staging CT-scan (chest and abdomen). Multiple nodular lesions are identified in the right lung, consistent with metastatic disease. The largest lesion is located in the right lower lobe, measuring approximately 2.5 cm in diameter. Additional smaller nodules are noted in the right upper and middle lobes, with the largest of these measuring up to 1.2 cm. No signs of metastatic involvement in the abdomen.

**June 15, 2023:** Brain MRI. No signs of brain metastasis.

**July 5, 2023:** Ultrasound-guided biopsy confirmed salivary duct carcinoma with high TMB and specific genetic mutations (HRAS p.Q61R, PIK3CA p.E545K). FISH positive for HER2 amplification.

**July 12, 2023:** Started on Docetaxel and Trastuzumab.

**October 15, 2023:** Follow-Up imaging: CT scan of the head and neck showed a reduction in tumor size to approximately 3.5 cm. Regional lymph nodes remained enlarged but showed decreased metabolic activity on PET scan. All pulmonary lesions show minimal reduction in size compared to previous scan. No new metastatic lesions.

**January 1, 2024:** Follow-up CT scan (neck, chest and abdomen) indicated disease progression. Primary tumor remains stable in size, as well as known lymph node metastases. Pulmonary metastases all show tumor growth with the largest lesion in the right lower lobe now measuring 2.8 cm in diameter. Multiple, previously unknown hypodense lesion within the left liver lobe, compatible with metastatic disease. PET scan shows high metabolic activity.

**January 9, 2024:** Tumor board recommends considering clinical trial options due to limited response to standard therapies.

**March 15, 2024:** Routine Labs: Comprehensive blood work indicated normal liver and renal function. The patient maintained an ECOG performance status of 1.

===== Patient 9.1.1 =====

**Patient Information**

Name: Mueller, Max

Born: 25.03.1945

Address: 456 Oak Street, Hamburg, Germany

**Overview of Tumor Diagnosis and Therapy**

Tumor Diagnosis

Diagnosis: Stage IV salivary duct carcinoma

Initial Detection: June 10, 2023, following symptoms of persistent facial swelling and pain

Biopsy Date: July 5, 2023

Molecular Profile: Tumor Mutational Burden (TMB) of 10.5 Mut/Mb, HRAS p.Q61R (AF 44%), PIK3CA p.E545K (AF 39%), p.H1047R (AF 30%). HER2 FISH positive.

### **Therapy Overview**

Initial Treatment:

Chemotherapy: Initiated on August 1, 2023, with Docetaxel plus Trastuzumab. Partial response noted after three months.

Subsequent Treatment: Second-line chemotherapy with carboplatin and paclitaxel initiated on December 1, 2023, due to disease progression.

Current Status: Progressive disease with lymphatic, pulmonary and hepatic metastasis.

### **ECOG 2**

### **Comorbidities**

Former smoker 30 py

Hypertension Stage 1

Type 2 Diabetes Mellitus

HFrEF NYHA II

Hyperlipidemia

Benign Prostatic Hyperplasia (BPH)

### **Medication**

Candesartan 12 mg 1-0-0

Metoprolol 47,5 mg 1-0-0

Metformin 1000 mg 1-0-1

Empagliflozin 10mg 1-0-0

Atorvastatin 40 mg 0-0-0-1

Omeprazole 20 mg 1-0-0

Tamsulosin 0.4 mg 1-0-0

Fentanyl TTS 25 mcg every 3 days

Fentanyl s.l. 100 mcg as needed up to 4 times a day

Ibuprofen 600 1-1-1

**Chronological Medical Findings:**

**June 10, 2023:** Patient presented with persistent facial swelling and pain. A CT scan of the head and neck revealed a mass in the left parotid gland measuring approximately 5 cm with extensive local invasion into the surrounding soft tissues and suspected involvement of multiple regional lymph nodes in levels II and III

**June 12, 2023:** Staging CT-scan (chest and abdomen). Multiple nodular lesions are identified in the right lung, consistent with metastatic disease. The largest lesion is located in the right lower lobe, measuring approximately 2.5 cm in diameter. Additional smaller nodules are noted in the right upper and middle lobes, with the largest of these measuring up to 1.2 cm. No signs of metastatic involvement in the abdomen.

**June 15, 2023:** Brain MRI. No signs of brain metastasis.

**July 5, 2023:** Ultrasound-guided biopsy confirmed salivary duct carcinoma with high TMB and specific genetic mutations (HRAS p.Q61R, PIK3CA p.E545K). FISH positive for HER2 amplification.

**July 12, 2023:** Started on Docetaxel and Trastuzumab.

**October 15, 2023:** Follow-Up imaging: CT scan of the head and neck showed a reduction in tumor size to approximately 3.5 cm. Regional lymph nodes remained enlarged but showed decreased metabolic activity on PET scan. All pulmonary lesions show minimal reduction in size compared to previous scan. No new metastatic lesions.

**January 1, 2024:** Follow-up CT scan (neck, chest and abdomen) indicated disease progression. Primary tumor remains stable in size, as well as known lymph node metastases. Pulmonary metastases all show tumor growth with the largest lesion in the right lower lobe now measuring 2.8 cm in diameter. Multiple, previously unknown hypodense lesion within the left liver lobe, compatible with metastatic disease. PET scan shows high metabolic activity.

**January 9, 2024:** Tumor board recommends considering clinical trial options due to limited response to standard therapies.

**March 15, 2024:** Routine Labs: Comprehensive blood work indicated normal liver and moderately reduced renal function (eGFR 65 ml/min/1.73m<sup>2</sup>). The patient maintained an ECOG performance status of 2.

===== **Patient 9.1.2**=====

**Patient Information**

Name: Mueller, Max

Born: 25.03.1945

Address: 456 Oak Street, Hamburg, Germany

## Overview of Tumor Diagnosis and Therapy

Tumor Diagnosis

Diagnosis: Stage IV salivary duct carcinoma

Initial Detection: June 10, 2023, following symptoms of persistent facial swelling and pain

Biopsy Date: July 5, 2023

Molecular Profile: Tumor Mutational Burden (TMB) of 10.5 Mut/Mb, HRAS p.Q61R (AF 44%), PIK3CA p.E545K (AF 39%), p.H1047R (AF 30%). HER2 FISH positive.

## Therapy Overview

Initial Treatment:

Chemotherapy: Initiated on August 1, 2023, with Docetaxel plus Trastuzumab. Partial response noted after three months.

Subsequent Treatment: Second-line chemotherapy with carboplatin and paclitaxel initiated on December 1, 2023, due to disease progression.

Current Status: Progressive disease with lymphatic, pulmonary and hepatic metastasis.

## ECOG 3

### Comorbidities

Former smoker 30 py

Hypertension Stage 1

Type 2 Diabetes Mellitus

Hyperlipidemia

Benign Prostatic Hyperplasia (BPH)

### Medication

Candesartan 12 mg 1-0-0

Metoprolol 47,5 mg 1-0-0

Metformin 1000 mg 1-0-1

Empagliflozin 10mg 1-0-0

Atorvastatin 40 mg 0-0-0-1

Omeprazole 20 mg 1-0-0

Tamsulosin 0.4 mg 1-0-0

Fentanyl TTS 25 mcg every 3 days

Fentanyl s.l. 100 mcg as needed up to 4 times a day

Ibuprofen 600 1-1-1

#### **Chronological Medical Findings:**

**June 10, 2023:** Patient presented with persistent facial swelling and pain. A CT scan of the head and neck revealed a mass in the left parotid gland measuring approximately 5 cm with extensive local invasion into the surrounding soft tissues and suspected involvement of multiple regional lymph nodes in levels II and III

**June 12, 2023:** Staging CT-scan (chest and abdomen). Multiple nodular lesions are identified in the right lung, consistent with metastatic disease. The largest lesion is located in the right lower lobe, measuring approximately 2.5 cm in diameter. Additional smaller nodules are noted in the right upper and middle lobes, with the largest of these measuring up to 1.2 cm. No signs of metastatic involvement in the abdomen.

**June 15, 2023:** Brain MRI. No signs of brain metastasis.

**July 5, 2023:** Ultrasound-guided biopsy confirmed salivary duct carcinoma with high TMB and specific genetic mutations (HRAS p.Q61R, PIK3CA p.E545K). FISH positive for HER2 amplification.

**July 12, 2023:** Started on Docetaxel and Trastuzumab.

**October 15, 2023:** Follow-Up imaging: CT scan of the head and neck showed a reduction in tumor size to approximately 3.5 cm. Regional lymph nodes remained enlarged but showed decreased metabolic activity on PET scan. All pulmonary lesions show minimal reduction in size compared to previous scan. No new metastatic lesions.

**January 1, 2024:** Follow-up CT scan (neck, chest and abdomen) indicated disease progression. Primary tumor remains stable in size, as well as known lymph node metastases. Pulmonary metastases all show tumor growth with the largest lesion in the right lower lobe now measuring 2.8 cm in diameter. Multiple, previously unknown hypodense lesion within the left liver lobe, compatible with metastatic disease. PET scan shows high metabolic activity.

**January 9, 2024:** Tumor board recommends considering clinical trial options due to limited response to standard therapies.

**March 15, 2024:** Status assessment before possible study enrollment.

Patient shows reduced overall health, ECOG performance status now 3.

Lab results show liver and kidney injury: Total bilirubin 4.5 mg/dl, AST 230 U/L,

ALT 180 U/L, AP 320 U/L, GGT 30 U/L, Albumin 2.3 g/dl.

Creatinine 3.2 mg/dl, eGFR 20.6 ml/min/m<sup>2</sup>.

===== Patient 9.1.3 =====



### **Patient Information**

Name: Mueller, Max

Born: 25.03.1945

Address: 456 Oak Street, Hamburg, Germany

### **Overview of Tumor Diagnosis and Therapy**

Tumor Diagnosis

Diagnosis: Stage IV salivary duct carcinoma

Initial Detection: June 10, 2023, following symptoms of persistent facial swelling and pain

Biopsy Date: July 5, 2023

Molecular Profile: Tumor Mutational Burden (TMB) of 10.5 Mut/Mb, HRAS p.Q61R (AF 44%), PIK3CA p.E545K (AF 39%), p.H1047R (AF 30%). HER2 FISH positive.

### **Therapy Overview**

Initial Treatment:

Chemotherapy: Initiated on August 1, 2023, with Docetaxel plus Trastuzumab. Partial response noted after three months.

Subsequent Treatment: Second-line chemotherapy with carboplatin and paclitaxel initiated on December 1, 2023, due to disease progression.

Current Status: Progressive disease with lymphatic, pulmonary and hepatic metastasis.

### **ECOG 3**

### **Comorbidities**

Former smoker 30 py

Hypertension Stage 1

Type 2 Diabetes Mellitus

Hyperlipidemia

Benign Prostatic Hyperplasia (BPH)

UICC Stage III melanoma, diagnosed 10/2021

(currently on Nivolumab maintenance)

### **Medication**

Candesartan 12 mg 1-0-0

Metoprolol 47,5 mg 1-0-0

Metformin 1000 mg 1-0-1

Empagliflozin 10mg 1-0-0

Atorvastatin 40 mg 0-0-0-1

Omeprazole 20 mg 1-0-0

Tamsulosin 0.4 mg 1-0-0

Fentanyl TTS 25 mcg every 3 days

Fentanyl s.l. 100 mcg as needed up to 4 times a day

Ibuprofen 600 1-1-1

#### **Chronological Medical Findings:**

**June 10, 2023:** Patient presented with persistent facial swelling and pain. A CT scan of the head and neck revealed a mass in the left parotid gland measuring approximately 5 cm with extensive local invasion into the surrounding soft tissues and suspected involvement of multiple regional lymph nodes in levels II and III

**June 12, 2023:** Staging CT-scan (chest and abdomen). Multiple nodular lesions are identified in the right lung, consistent with metastatic disease. The largest lesion is located in the right lower lobe, measuring approximately 2.5 cm in diameter. Additional smaller nodules are noted in the right upper and middle lobes, with the largest of these measuring up to 1.2 cm. No signs of metastatic involvement in the abdomen.

**June 15, 2023:** Brain MRI. No signs of brain metastasis.

**July 5, 2023:** Ultrasound-guided biopsy confirmed salivary duct carcinoma with high TMB and specific genetic mutations (HRAS p.Q61R, PIK3CA p.E545K). FISH positive for HER2 amplification.

**July 12, 2023:** Started on Docetaxel and Trastuzumab.

**October 15, 2023:** Follow-Up imaging: CT scan of the head and neck showed a reduction in tumor size to approximately 3.5 cm. Regional lymph nodes remained enlarged but showed decreased metabolic activity on PET scan. All pulmonary lesions show minimal reduction in size compared to previous scan. No new metastatic lesions.

**January 1, 2024:** Follow-up CT scan (neck, chest and abdomen) indicated disease progression. Primary tumor remains stable in size, as well as known lymph node metastases. Pulmonary metastases all show tumor growth with the largest lesion in the right lower lobe now measuring 2.8 cm in diameter. Multiple, previously unknown hypodense lesion within the left liver lobe, compatible with metastatic disease. PET scan shows high metabolic activity.

**January 9, 2024:** Tumor board recommends considering clinical trial options due to limited response to standard therapies.

**March 15, 2024:** Status assessment before possible study enrollment.

Patient shows reduced overall health, ECOG performance status now 3.

Lab results show liver and kidney injury: Total bilirubin 4.5 mg/dl, AST 230 U/L,

ALT 180 U/L, AP 320 U/L, GGT 30 U/L, Albumin 2.3 g/dl.

Creatinine 3.2 mg/dl, eGFR 20.6 ml/min/m<sup>2</sup>.

===== **Patient 9.2** =====

**Patient Information**

Name: Mueller, Max

Born: 25.03.1945

Address: 456 Oak Street, Hamburg, Germany

**Overview of Tumor Diagnosis and Therapy**

Tumor Diagnosis

Diagnosis: Stage IV salivary duct carcinoma

Initial Detection: June 10, 2023, following symptoms of persistent facial swelling and pain

Biopsy Date: July 5, 2023

Molecular Profile: Tumor Mutational Burden (TMB) of 10.5 Mut/Mb, HRAS p.Q61R (AF 44%), PIK3CA p.E545K (AF 39%). HER2 FISH positive.

**Therapy Overview**

Initial Treatment:

Chemotherapy: Initiated on August 1, 2023, with Docetaxel (70 mg/m<sup>2</sup>) plus Trastuzumab (8 mg/kg). Partial response noted after three months.

Subsequent Treatment: Second-line chemotherapy with carboplatin (6 mg/m<sup>2</sup>/min) and paclitaxel (200 mg/m<sup>2</sup> q3week) initiated on December 1, 2023, due to disease progression.

Current Status: Progressive disease with lymphatic, pulmonary and hepatic metastasis.

**ECOG 1**

**Comorbidities**

Former smoker 30 py

Hypertension Stage 1  
Type 2 Diabetes Mellitus  
Hyperlipidemia  
Benign Prostatic Hyperplasia (BPH)

**Medication**

Amlodipine 10 mg 1-0-0  
Metformin 1000 mg 1-0-1  
Empagliflozin 10mg 1-0-0  
Atorvastatin 40 mg 0-0-0-1  
Omeprazole 20 mg 1-0-0  
Tamsulosin 0.4 mg 1-0-0  
Fentanyl TTS 25 mcg every 3 days  
Fentanyl s.l. 100 mcg as needed up to 4 times a day  
Ibuprofen 600 1-1-1

**Chronological Medical Findings:**

**June 10, 2023:** Patient presented with persistent facial swelling and pain. A CT scan of the head and neck revealed a mass in the left parotid gland measuring approximately 5 cm with extensive local invasion into the surrounding soft tissues and suspected involvement of multiple regional lymph nodes in levels II and III

**June 12, 2023:** Staging CT-scan (chest and abdomen). Multiple nodular lesions are identified in the right lung, consistent with metastatic disease. The largest lesion is located in the right lower lobe, measuring approximately 2.5 cm in diameter. Additional smaller nodules are noted in the right upper and middle lobes, with the largest of these measuring up to 1.2 cm. No signs of metastatic involvement in the abdomen.

**June 15, 2023:** Brain MRI. No signs of brain metastasis.

**July 5, 2023:** Ultrasound-guided biopsy confirmed salivary duct carcinoma with high TMB and specific genetic mutations (HRAS p.Q61R, PIK3CA p.E545K). FISH positive for HER2 amplification.

**July 12, 2023:** Started on Docetaxel and Trastuzumab.

**October 15, 2023:** Follow-Up imaging: CT scan of the head and neck showed a reduction in tumor size to approximately 3.5 cm. Regional lymph nodes remained enlarged but showed decreased metabolic activity on PET scan. All pulmonary lesions show minimal reduction in size compared to previous scan. No new metastatic lesions.

**January 1, 2024:** Follow-up CT scan (neck, chest and abdomen) indicated disease progression. Primary tumor remains stable in size, as well as known lymph node

metastases. Pulmonary metastases all show tumor growth with the largest lesion in the right lower lobe now measuring 2.8 cm in diameter. Multiple, previously unknown hypodense lesion within the left liver lobe, compatible with metastatic disease. PET scan shows high metabolic activity.

**January 9, 2024:** Tumor board recommends considering clinical trial options due to limited response to standard therapies.

**March 15, 2024:** Routine Labs: Comprehensive blood work indicated normal liver and renal function. The patient maintained an ECOG performance status of 1.

===== **Patient 9.2.1**=====

**Patient Information**

Name: Mueller, Max

Born: 25.03.1945

Address: 456 Oak Street, Hamburg, Germany

**Overview of Tumor Diagnosis and Therapy**

Tumor Diagnosis

Diagnosis: Stage IV salivary duct carcinoma

Initial Detection: June 10, 2023, following symptoms of persistent facial swelling and pain

Biopsy Date: July 5, 2023

Molecular Profile: Tumor Mutational Burden (TMB) of 10.5 Mut/Mb, HRAS p.Q61R (AF 44%), PIK3CA p.E545K (AF 39%). HER2 FISH positive.

**Therapy Overview**

Initial Treatment:

Chemotherapy: Initiated on August 1, 2023, with Docetaxel (70 mg/m<sup>2</sup>) plus Trastuzumab (8 mg/kg). Partial response noted after three months.

Subsequent Treatment: Second-line chemotherapy with carboplatin (6 mg/m<sup>2</sup>/min) and paclitaxel (200 mg/m<sup>2</sup> q3week) initiated on December 1, 2023, due to disease progression.

Current Status: Progressive disease with lymphatic, pulmonary and hepatic metastasis.

**ECOG 1**

**Comorbidities**

HIV (current viral load undetectable)

Former smoker 30 py

Hypertension Stage 1

Type 2 Diabetes Mellitus

Hyperlipidemia

Benign Prostatic Hyperplasia (BPH)

#### **Medication**

Amlodipine 10 mg 1-0-0

Metformin 1000 mg 1-0-1

Empagliflozin 10mg 1-0-0

Atorvastatin 40 mg 0-0-0-1

Omeprazole 20 mg 1-0-0

Tamsulosin 0.4 mg 1-0-0

Fentanyl TTS 25 mcg every 3 days

Fentanyl s.l. 100 mcg as needed up to 4 times a day

Ibuprofen 600 1-1-1

Bictegravir/Emtricitabine/Tenofovir alafenamide 50mg/200mg/25mg 1-0-0

#### **Chronological Medical Findings:**

**June 10, 2023:** Patient presented with persistent facial swelling and pain. A CT scan of the head and neck revealed a mass in the left parotid gland measuring approximately 5 cm with extensive local invasion into the surrounding soft tissues and suspected involvement of multiple regional lymph nodes in levels II and III

**June 12, 2023:** Staging CT-scan (chest and abdomen). Multiple nodular lesions are identified in the right lung, consistent with metastatic disease. The largest lesion is located in the right lower lobe, measuring approximately 2.5 cm in diameter. Additional smaller nodules are noted in the right upper and middle lobes, with the largest of these measuring up to 1.2 cm. No signs of metastatic involvement in the abdomen.

**June 15, 2023:** Brain MRI. No signs of brain metastasis.

**July 5, 2023:** Ultrasound-guided biopsy confirmed salivary duct carcinoma with high TMB and specific genetic mutations (HRAS p.Q61R, PIK3CA p.E545K). FISH positive for HER2 amplification.

**July 12, 2023:** Started on Docetaxel and Trastuzumab.

**October 15, 2023:** Follow-Up imaging: CT scan of the head and neck showed a reduction in tumor size to approximately 3.5 cm. Regional lymph nodes remained enlarged but showed decreased metabolic activity on PET scan. All pulmonary lesions show minimal reduction in size compared to previous scan. No new metastatic lesions.

**January 1, 2024:** Follow-up CT scan (neck, chest and abdomen) indicated disease progression. Primary tumor remains stable in size, as well as known lymph node metastases. Pulmonary metastases all show tumor growth with the largest lesion in the right lower lobe now measuring 2.8 cm in diameter. Multiple, previously unknown hypodense lesion within the left liver lobe, compatible with metastatic disease. PET scan shows high metabolic activity.

**January 9, 2024:** Tumor board recommends considering clinical trial options due to limited response to standard therapies.

**March 15, 2024:** Routine Labs: Comprehensive blood work indicated normal liver and renal function. The patient maintained an ECOG performance status of 1.

===== **Patient 9.2.2** =====

**Patient Information**

Name: Mueller, Max

Born: 25.03.1945

Address: 456 Oak Street, Hamburg, Germany

**Overview of Tumor Diagnosis and Therapy**

Tumor Diagnosis

Diagnosis: Stage IV salivary duct carcinoma

Initial Detection: June 10, 2023, following symptoms of persistent facial swelling and pain

Biopsy Date: July 5, 2023

Molecular Profile: Tumor Mutational Burden (TMB) of 10.5 Mut/Mb, HRAS p.Q61R (AF 44%), PIK3CA p.E545K (AF 39%). HER2 FISH positive.

**Therapy Overview**

Initial Treatment:

Chemotherapy: Initiated on August 1, 2023, with Docetaxel (70 mg/m<sup>2</sup>) plus Trastuzumab (8 mg/kg). Partial response noted after three months.

Subsequent Treatment: Second-line chemotherapy with carboplatin (6 mg/m<sup>2</sup>/min) and paclitaxel (200 mg/m<sup>2</sup> q3week) initiated on December 1, 2023, due to disease progression.

Current Status: Progressive disease with lymphatic, pulmonary and hepatic metastasis.

## ECOG 1

### Comorbidities

Former smoker 30 py

Hypertension Stage 1

HFrEF NYHA II

Type 2 Diabetes Mellitus

Generalized Epilepsy

Hyperlipidemia

Benign Prostatic Hyperplasia (BPH)

### Medication

Candesartan 12 mg 1-0-0 Metoprolol 47,5 mg 1-0-0 Valproic acid 500mg 2-0-2

Metformin 1000 mg 1-0-1

Empagliflozin 10mg 1-0-0

Atorvastatin 40 mg 0-0-0-1

Omeprazole 20 mg 1-0-0

Tamsulosin 0.4 mg 1-0-0

Fentanyl TTS 25 mcg every 3 days

Fentanyl s.l. 100 mcg as needed up to 4 times a day

Ibuprofen 600 1-1-1

### Chronological Medical Findings:

**June 10, 2023:** Patient presented with persistent facial swelling and pain. A CT scan of the head and neck revealed a mass in the left parotid gland measuring approximately 5 cm with extensive local invasion into the surrounding soft tissues and suspected involvement of multiple regional lymph nodes in levels II and III

**June 12, 2023:** Staging CT-scan (chest and abdomen). Multiple nodular lesions are identified in the right lung, consistent with metastatic disease. The largest lesion is located in the right lower lobe, measuring approximately 2.5 cm in diameter. Additional smaller nodules are noted in the right upper and middle lobes, with the largest of these measuring up to 1.2 cm. No signs of metastatic involvement in the abdomen.



**June 15, 2023:** Brain MRI. No signs of brain metastasis.

**July 5, 2023:** Ultrasound-guided biopsy confirmed salivary duct carcinoma with high TMB and specific genetic mutations (HRAS p.Q61R, PIK3CA p.E545K). FISH positive for HER2 amplification.

**July 12, 2023:** Started on Docetaxel and Trastuzumab.

**October 15, 2023:** Follow-Up imaging: CT scan of the head and neck showed a reduction in tumor size to approximately 3.5 cm. Regional lymph nodes remained enlarged but showed decreased metabolic activity on PET scan. All pulmonary lesions show minimal reduction in size compared to previous scan. No new metastatic lesions.

**January 1, 2024:** Follow-up CT scan (neck, chest and abdomen) indicated disease progression. Primary tumor remains stable in size, as well as known lymph node metastases. Pulmonary metastases all show tumor growth with the largest lesion in the right lower lobe now measuring 2.8 cm in diameter. Multiple, previously unknown hypodense lesion within the left liver lobe, compatible with metastatic disease. PET scan shows high metabolic activity.

**January 9, 2024:** Tumor board recommends considering clinical trial options due to limited response to standard therapies.

**March 15, 2024:** Routine Labs: Comprehensive blood work indicated normal liver and renal function. The patient maintained an ECOG performance status of 1.

===== **Patient 9.2.3**=====

**Patient Information**

Name: Mueller, Max

Born: 25.03.1945

Address: 456 Oak Street, Hamburg, Germany

**Overview of Tumor Diagnosis and Therapy**

Tumor Diagnosis

Diagnosis: Stage IV salivary duct carcinoma

Initial Detection: June 10, 2023, following symptoms of persistent facial swelling and pain

Biopsy Date: July 5, 2023

Molecular Profile: Tumor Mutational Burden (TMB) of 10.5 Mut/Mb, HRAS p.Q61R (AF 44%), PIK3CA p.E545K (AF 39%). HER2 FISH positive.

**Therapy Overview**

Initial Treatment:

Chemotherapy: Initiated on August 1, 2023, with Docetaxel (70 mg/m<sup>2</sup>) plus Trastuzumab (8 mg/kg). Partial response noted after three months.

Subsequent Treatment: Second-line chemotherapy with carboplatin (6 mg/m<sup>2</sup>/min) and paclitaxel (200 mg/m<sup>2</sup> q3week) initiated on December 1, 2023, due to disease progression.

Current Status: Progressive disease with lymphatic, pulmonary, hepatic and brain metastasis.

## ECOG 1

### Comorbidities

#### Alcohol dependence

Former smoker 30 py

Hypertension Stage 1

Type 2 Diabetes Mellitus

Hyperlipidemia

Benign Prostatic Hyperplasia (BPH)

### Medication

Amlodipine 10 mg 1-0-0

Metformin 1000 mg 1-0-1

Empagliflozin 10mg 1-0-0

Atorvastatin 40 mg 0-0-0-1

Omeprazole 20 mg 1-0-0

Tamsulosin 0.4 mg 1-0-0

Fentanyl TTS 25 mcg every 3 days

Fentanyl s.l. 100 mcg as needed up to 4 times a day

Ibuprofen 600 1-1-1

### Chronological Medical Findings:

**June 10, 2023:** Patient presented with persistent facial swelling and pain. A CT scan of the head and neck revealed a mass in the left parotid gland measuring approximately 5 cm with extensive local invasion into the surrounding soft tissues and suspected involvement of multiple regional lymph nodes in levels II and III

**June 12, 2023:** Staging CT-scan (chest and abdomen). Multiple nodular lesions are identified in the right lung, consistent with metastatic disease. The largest lesion is located in the right lower lobe, measuring approximately 2.5 cm in diameter. Additional smaller nodules are noted in the right upper and middle lobes, with the largest of these measuring up to 1.2 cm. No signs of metastatic involvement in the abdomen.

**June 15, 2023:** Brain MRI. No signs of brain metastasis.

**July 5, 2023:** Ultrasound-guided biopsy confirmed salivary duct carcinoma with high TMB and specific genetic mutations (HRAS p.Q61R, PIK3CA p.E545K). FISH positive for HER2 amplification.

**July 12, 2023:** Started on Docetaxel and Trastuzumab.

**October 15, 2023:** Follow-Up imaging: CT scan of the head and neck showed a reduction in tumor size to approximately 3.5 cm. Regional lymph nodes remained enlarged but showed decreased metabolic activity on PET scan. All pulmonary lesions show minimal reduction in size compared to previous scan. No new metastatic lesions.

**January 1, 2024:** Follow-up CT scan (neck, chest and abdomen) indicated disease progression. Primary tumor remains stable in size, as well as known lymph node metastases. Pulmonary metastases all show tumor growth with the largest lesion in the right lower lobe now measuring 2.8 cm in diameter. Multiple, previously unknown hypodense lesion within the left liver lobe, compatible with metastatic disease. PET scan shows high metabolic activity.

**January 5, 2024:** MRI scan of the brain revealed multiple metastases, specifically two lesions in the left hemisphere: one in the left frontal lobe and one in the left occipital lobe.

Incidental findings included mild age-related cerebral atrophy and scattered white matter hyperintensities consistent with chronic microvascular ischemic changes.

**January 9, 2024:** Tumor board recommends considering clinical trial options due to limited response to standard therapies.

**March 15, 2024:** Routine Labs: Comprehensive blood work indicated normal liver and renal function. The patient maintained an ECOG performance status of 1.

### ===== Patient 9.3 =====

#### Patient Information

Name: Mueller, Max

Born: 25.03.1945

Address: 456 Oak Street, Hamburg, Germany

#### Overview of Tumor Diagnosis and Therapy

Tumor Diagnosis

Diagnosis: Stage IV salivary duct carcinoma

Initial Detection: June 10, 2023, following symptoms of persistent facial swelling and pain

Biopsy Date: July 5, 2023

Molecular Profile: Tumor Mutational Burden (TMB) of 10.5 Mut/Mb, HRAS p.Q61R (AF 44%), PIK3CA p.E545K (AF 39%). HER2 FISH positive.

### **Therapy Overview**

Initial Treatment:

Chemotherapy: Initiated on August 1, 2023, with Docetaxel plus Trastuzumab. Partial response noted after three months.

Subsequent Treatment: Second-line chemotherapy with carboplatin and paclitaxel initiated on December 1, 2023, due to disease progression.

Current Status: Progressive disease with lymphatic, pulmonary and hepatic metastasis.

### **ECOG 1**

### **Comorbidities**

Former smoker 30 py

Hypertension Stage 1

Type 2 Diabetes Mellitus

Hyperlipidemia

Benign Prostatic Hyperplasia (BPH)

### **Medication**

Amlodipine 10 mg 1-0-0

Metformin 1000 mg 1-0-1

Empagliflozin 10mg 1-0-0

Atorvastatin 40 mg 0-0-0-1

Omeprazole 20 mg 1-0-0

Tamsulosin 0.4 mg 1-0-0

Fentanyl TTS 25 mcg every 3 days

Fentanyl s.l. 100 mcg as needed up to 4 times a day

Ibuprofen 600 1-1-1

### **Chronological Medical Findings:**

**June 10, 2023:** Patient presented with persistent facial swelling and pain. A CT scan of the head and neck revealed a mass in the left parotid gland measuring approximately 5 cm with extensive local invasion into the surrounding soft tissues and suspected involvement of multiple regional lymph nodes in levels II and III

**June 12, 2023:** Staging CT-scan (chest and abdomen). Multiple nodular lesions are identified in the right lung, consistent with metastatic disease. The largest lesion is located in the right lower lobe, measuring approximately 2.5 cm in diameter. Additional smaller nodules are noted in the right upper and middle lobes, with the largest of these measuring up to 1.2 cm. No signs of metastatic involvement in the abdomen.

**June 15, 2023:** Brain MRI. No signs of brain metastasis.

**July 5, 2023:** Ultrasound-guided biopsy confirmed salivary duct carcinoma with high TMB and specific genetic mutations (HRAS p.Q61R, PIK3CA p.E545K). FISH positive for HER2 amplification.

**July 12, 2023:** Started on Docetaxel and Trastuzumab.

**October 15, 2023:** Follow-Up imaging: CT scan of the head and neck showed a reduction in tumor size to approximately 3.5 cm. Regional lymph nodes remained enlarged but showed decreased metabolic activity on PET scan. All pulmonary lesions show minimal reduction in size compared to previous scan. No new metastatic lesions.

**January 1, 2024:** Follow-up CT scan (neck, chest and abdomen) indicated disease progression. Primary tumor remains stable in size, as well as known lymph node metastases. Pulmonary metastases all show tumor growth with the largest lesion in the right lower lobe now measuring 2.8 cm in diameter. Multiple, previously unknown hypodense lesion within the left liver lobe, compatible with metastatic disease. PET scan shows high metabolic activity.

**January 9, 2024:** Tumor board recommends considering clinical trial options due to limited response to standard therapies.

**March 15, 2024:** Routine Labs: Comprehensive blood work indicated normal liver and renal function. The patient maintained an ECOG performance status of 1.

### **==== Patient 9.3.1 =====**

#### **Patient Information**

Name: Mueller, Max

Born: 25.03.1945

Address: 456 Oak Street, Hamburg, Germany

#### **Overview of Tumor Diagnosis and Therapy**

Tumor Diagnosis

Diagnosis: Stage IV salivary duct carcinoma

Initial Detection: June 10, 2023, following symptoms of persistent facial swelling and pain

Biopsy Date: July 5, 2023

Molecular Profile: Tumor Mutational Burden (TMB) of 10.5 Mut/Mb, HRAS p.Q61R (AF 44%), PIK3CA p.E545K (AF 39%). HER2 FISH positive.

### **Therapy Overview**

Initial Treatment:

Chemotherapy: Initiated on August 1, 2023, with Docetaxel plus Trastuzumab. Partial response noted after three months.

Subsequent Treatment: Second-line chemotherapy with carboplatin and paclitaxel initiated on December 1, 2023, due to disease progression.

Current Status: Progressive disease with lymphatic, pulmonary and hepatic metastasis.

### **ECOG 2**

### **Comorbidities**

Former smoker 30 py

Hypertension Stage 1

Type 2 Diabetes Mellitus

Hyperlipidemia

Benign Prostatic Hyperplasia (BPH)

### **CKD KDIGO G4**

### **Medication**

Amlodipine 10 mg 1-0-0

Metformin 1000 mg 1-0-1

Empagliflozin 10mg 1-0-0

Atorvastatin 40 mg 0-0-0-1

Omeprazole 20 mg 1-0-0

Tamsulosin 0.4 mg 1-0-0

Fentanyl TTS 25 mcg every 3 days

Fentanyl s.l. 100 mcg as needed up to 4 times a day

Ibuprofen 600 1-1-1

### **Chronological Medical Findings:**

**June 10, 2023:** Patient presented with persistent facial swelling and pain. A CT scan of the head and neck revealed a mass in the left parotid gland measuring approximately 5 cm with extensive local invasion into the surrounding soft tissues and suspected involvement of multiple regional lymph nodes in levels II and III

**June 12, 2023:** Staging CT-scan (chest and abdomen). Multiple nodular lesions are identified in the right lung, consistent with metastatic disease. The largest lesion is located in the right lower lobe, measuring approximately 2.5 cm in diameter. Additional smaller nodules are noted in the right upper and middle lobes, with the largest of these measuring up to 1.2 cm. No signs of metastatic involvement in the abdomen.

**June 15, 2023:** Brain MRI. No signs of brain metastasis.

**July 5, 2023:** Ultrasound-guided biopsy confirmed salivary duct carcinoma with high TMB and specific genetic mutations (HRAS p.Q61R, PIK3CA p.E545K). FISH positive for HER2 amplification.

**July 12, 2023:** Started on Docetaxel and Trastuzumab.

**October 15, 2023:** Follow-Up imaging: CT scan of the head and neck showed a reduction in tumor size to approximately 3.5 cm. Regional lymph nodes remained enlarged but showed decreased metabolic activity on PET scan. All pulmonary lesions show minimal reduction in size compared to previous scan. No new metastatic lesions.

**January 1, 2024:** Follow-up CT scan (neck, chest and abdomen) indicated disease progression. Primary tumor remains stable in size, as well as known lymph node metastases. Pulmonary metastases all show tumor growth with the largest lesion in the right lower lobe now measuring 2.8 cm in diameter. Multiple, previously unknown hypodense lesion within the left liver lobe, compatible with metastatic disease. PET scan shows high metabolic activity.

**January 9, 2024:** Tumor board recommends considering clinical trial options due to limited response to standard therapies.

**March 15, 2024:** Routine Labs: Comprehensive blood work indicated normal organ function except for known reduced kidney function: eGFR 21.56 ml/min/1.73m<sup>2</sup>,

Creatinine 3.0 mg/dl.

Current ECOG performance status 2.

### **==== Patient 9.3.2 =====**

#### **Patient Information**

Name: Mueller, Max

Born: 25.03.1945

Address: 456 Oak Street, Hamburg, Germany

## Overview of Tumor Diagnosis and Therapy

### Tumor Diagnosis

Diagnosis: Stage IV salivary duct carcinoma

Initial Detection: June 10, 2023, following symptoms of persistent facial swelling and pain

Biopsy Date: July 5, 2023

Molecular Profile: Tumor Mutational Burden (TMB) of 10.5 Mut/Mb, HRAS p.Q61R (AF 44%), PIK3CA p.E545K (AF 39%). HER2 FISH positive.

### Therapy Overview

Initial Treatment:

Chemotherapy: Initiated on August 1, 2023, with Docetaxel plus Trastuzumab. Partial response noted after three months.

Subsequent Treatment: Second-line chemotherapy with carboplatin and paclitaxel initiated on December 1, 2023, due to disease progression.

Current Status: Progressive disease with lymphatic, pulmonary and hepatic metastasis.

### ECOG 1

**Active P. jirovecii pneumonia**

### Comorbidities

Former smoker 30 py

Hypertension Stage 1

Type 2 Diabetes Mellitus

Hyperlipidemia

Benign Prostatic Hyperplasia (BPH)

### Medication

**Sulfamethoxazole/Trimethoprim 400mg/80mg 5-5-5-5**

Amlodipine 10 mg 1-0-0

Metformin 1000 mg 1-0-1

Empagliflozin 10mg 1-0-0

Atorvastatin 40 mg 0-0-0-1

Omeprazole 20 mg 1-0-0



Tamsulosin 0.4 mg 1-0-0

Fentanyl TTS 25 mcg every 3 days

Fentanyl s.l. 100 mcg as needed up to 4 times a day

Ibuprofen 600 1-1-1

#### **Chronological Medical Findings:**

**June 10, 2023:** Patient presented with persistent facial swelling and pain. A CT scan of the head and neck revealed a mass in the left parotid gland measuring approximately 5 cm with extensive local invasion into the surrounding soft tissues and suspected involvement of multiple regional lymph nodes in levels II and III

**June 12, 2023:** Staging CT-scan (chest and abdomen). Multiple nodular lesions are identified in the right lung, consistent with metastatic disease. The largest lesion is located in the right lower lobe, measuring approximately 2.5 cm in diameter. Additional smaller nodules are noted in the right upper and middle lobes, with the largest of these measuring up to 1.2 cm. No signs of metastatic involvement in the abdomen.

**June 15, 2023:** Brain MRI. No signs of brain metastasis.

**July 5, 2023:** Ultrasound-guided biopsy confirmed salivary duct carcinoma with high TMB and specific genetic mutations (HRAS p.Q61R, PIK3CA p.E545K). FISH positive for HER2 amplification.

**July 12, 2023:** Started on Docetaxel and Trastuzumab.

**October 15, 2023:** Follow-Up imaging: CT scan of the head and neck showed a reduction in tumor size to approximately 3.5 cm. Regional lymph nodes remained enlarged but showed decreased metabolic activity on PET scan. All pulmonary lesions show minimal reduction in size compared to previous scan. No new metastatic lesions.

**January 1, 2024:** Follow-up CT scan (neck, chest and abdomen) indicated disease progression. Primary tumor remains stable in size, as well as known lymph node metastases. Pulmonary metastases all show tumor growth with the largest lesion in the right lower lobe now measuring 2.8 cm in diameter. Multiple, previously unknown hypodense lesion within the left liver lobe, compatible with metastatic disease. PET scan shows high metabolic activity.

**January 9, 2024:** Tumor board recommends considering clinical trial options due to limited response to standard therapies.

**March 15, 2024:** Routine Labs: Comprehensive blood work indicated normal liver and renal function. The patient maintained an ECOG performance status of 1.

#### **===== Patient 9.3.3 =====**

#### **Patient Information**

Name: Mueller, Max

Born: 25.03.1945

Address: 456 Oak Street, Hamburg, Germany

### **Overview of Tumor Diagnosis and Therapy**

Tumor Diagnosis

Diagnosis: Stage IV salivary duct carcinoma

Initial Detection: June 10, 2023, following symptoms of persistent facial swelling and pain

Biopsy Date: July 5, 2023

Molecular Profile: Tumor Mutational Burden (TMB) of 10.5 Mut/Mb, HRAS p.Q61R (AF 44%), PIK3CA p.E545K (AF 39%). HER2 FISH positive.

### **Therapy Overview**

Initial Treatment:

Chemotherapy: Initiated on August 1, 2023, with Docetaxel plus Trastuzumab. Partial response noted after three months.

Subsequent Treatment: Second-line chemotherapy with carboplatin and paclitaxel initiated on December 1, 2023, due to disease progression.

Current Status: Progressive disease with lymphatic, pulmonary, hepatic and **brain metastasis**.

### **ECOG 1**

#### **Comorbidities**

Former smoker 30 py

Hypertension Stage 1

Type 2 Diabetes Mellitus

Hyperlipidemia

Benign Prostatic Hyperplasia (BPH)

#### **Medication**

Amlodipine 10 mg 1-0-0

Metformin 1000 mg 1-0-1

Empagliflozin 10mg 1-0-0

Atorvastatin 40 mg 0-0-0-1

Omeprazole 20 mg 1-0-0

Tamsulosin 0.4 mg 1-0-0

Fentanyl TTS 25 mcg every 3 days

Fentanyl s.l. 100 mcg as needed up to 4 times a day

Ibuprofen 600 1-1-1

### **Chronological Medical Findings:**

**June 10, 2023:** Patient presented with persistent facial swelling and pain. A CT scan of the head and neck revealed a mass in the left parotid gland measuring approximately 5 cm with extensive local invasion into the surrounding soft tissues and suspected involvement of multiple regional lymph nodes in levels II and III

**June 12, 2023:** Staging CT-scan (chest and abdomen). Multiple nodular lesions are identified in the right lung, consistent with metastatic disease. The largest lesion is located in the right lower lobe, measuring approximately 2.5 cm in diameter. Additional smaller nodules are noted in the right upper and middle lobes, with the largest of these measuring up to 1.2 cm. No signs of metastatic involvement in the abdomen.

**June 15, 2023:** Brain MRI. No signs of brain metastasis.

**July 5, 2023:** Ultrasound-guided biopsy confirmed salivary duct carcinoma with high TMB and specific genetic mutations (HRAS p.Q61R, PIK3CA p.E545K). FISH positive for HER2 amplification.

**July 12, 2023:** Started on Docetaxel and Trastuzumab.

**October 15, 2023:** Follow-Up imaging: CT scan of the head and neck showed a reduction in tumor size to approximately 3.5 cm. Regional lymph nodes remained enlarged but showed decreased metabolic activity on PET scan. All pulmonary lesions show minimal reduction in size compared to previous scan. No new metastatic lesions.

**January 1, 2024:** Follow-up CT scan (neck, chest and abdomen) indicated disease progression. Primary tumor remains stable in size, as well as known lymph node metastases. Pulmonary metastases all show tumor growth with the largest lesion in the right lower lobe now measuring 2.8 cm in diameter. Multiple, previously unknown hypodense lesion within the left liver lobe, compatible with metastatic disease. PET scan shows high metabolic activity.

**January 4, 2024:** MRI scan of the brain revealed multiple metastases, specifically two lesions in the right hemisphere: one in the right frontal lobe and one in the right parietal lobe.

Incidental findings included mild age-related cerebral atrophy and scattered white matter hyperintensities consistent with chronic microvascular ischemic changes.

**January 9, 2024:** Tumor board recommends considering clinical trial options due to limited response to standard therapies.

**March 15, 2024:** Routine Labs: Comprehensive blood work indicated normal liver and renal function. The patient maintained an ECOG performance status of 1.

===== Patient 10.1 =====

Name: Miller, Jane  
Born: 25.07.1965  
Address: Main Street 78, Potsdam

### Overview of Tumor Diagnosis and Therapy

#### Tumor Diagnosis

Diagnosis: UICC Stage IV EGFR mutated non-small cell lung cancer (NSCLC)  
Initial Detection: January 10, 2023, following symptoms of persistent cough and chest pain  
Biopsy Date: February 5, 2023, adenocarcinoma of the lung  
Molecular Profile: Panel (tumor purity 60%). EGFR p.E746\_A750del (AF 50%), EGFR T790M, EGFR p.C797S (AF 29%), STK11 p.C210\* (AF 39%).

#### Therapy Overview

##### Initial Treatment:

Targeted Therapy: Began March 1, 2023, with Osimertinib (T790M). Partial response noted after initial therapy cycle completed by June 15, 2023. Continued therapy until November 2021 (progressive disease).

##### Subsequent Treatment:

Further treatment with Pembrolizumab in combination with Paclitaxel/Carboplatin/Bevacizumab and Atezolizumab initiated on December 1, 2023. Staging CT shows disease progression after 6 months.

Current Status: **ECOG 1**

#### Comorbidities

Current smoker: 35 py

Hypertension Stage 1

Hyperlipidemia: Managed with Simvastatin 20 mg daily

COPD GOLD 2

#### Medication

Losartan 50mg 1-0-0

Simvastatin 20mg daily 0-0-0-1

Albuterol (inhaler) on demand

Tiotropium (inhaler) on demand

#### Chronological Medical Findings:

**January 2023:** Complaints of persistent cough and bloody sputum. Weight loss of -10kg / 5 months. Chest X-ray revealed a mass in the right lung.

**January 10, 2023:** Comprehensive CT scan (chest and abdomen): Solid, spiculated mass in the right upper lobe of the lung measuring approximately 3.8 cm. Additionally, three small hypoattenuating hepatic lesions noted, to be considered as metastases. Enlarged hilar and subcarinal lymph nodes. Right adrenal gland slightly enlarged, warranting further investigation for metastatic involvement. No evidence of pleural effusion or significant vascular invasion was present. Additional notes: Minor atelectasis in the left lower lobe and mild emphysematous changes in both lungs, consistent with the patient's history of chronic obstructive pulmonary disease (COPD). The abdominal organs, aside from the hepatic lesions and possible adrenal metastasis, appeared unremarkable.

**February 5, 2023:** Biopsy and molecular testing confirmed adenocarcinoma with EGFR T790M mutation. Material sent for further panel testing. Initiated Osimertinib therapy on March 1, 2021. Patient signed consent. Patient in clinical good condition.

**Feb.-June 2023:** Antineoplastic targeted therapy with Osimertinib.

**June 15, 2023:** Follow-up CT scan (chest and abdomen), PET CT scan: Partial response (PR) to treatment. The primary lung mass in the right upper lobe decreased in size, now measuring approximately 3 cm in diameter, down from 3.8 cm. The three previously noted hypoattenuating hepatic lesions have also shown slight reduction in size and decreased metabolic activity, suggesting a positive response to systemic therapy. No new metastatic lesions detected in the liver or other abdominal organs. The previously enlarged hilar and subcarinal lymph nodes have reduced in size, indicating a favorable response to treatment. The right adrenal gland remains slightly enlarged but stable, with no significant change noted, and it continues to show no signs of active disease. Overall: PR.

**July 1, 2023:** Continuation of Osimertinib therapy

**October 3, 2023:** CT scan Chest/Abd.: PD. The primary lung mass in the right upper lobe has increased in size, now measuring approximately 4.5 cm in diameter (prev 3.0 cm). The previously noted hypoattenuating hepatic lesions have also shown slight growth. Additional new metastasis in S7. Small pleural effusion on the right side, minor atelectasis in the left lower lobe has slightly worsened. Hilar and subcarinal lymph nodes drastically enlarged in size. Right adrenal gland with second metastasis. No new metastatic lesions were detected in the liver or other abdominal organs.

**December 1, 2023:** Begin Paclitaxel/Carboplatin/Bevacizumab and Atezolizumab. Received written consent from the patient, ECOG 1.

**May 10, 2024:** CT Lung/Abdomen: Progressive Disease. Primary lung mass in the right upper lobe has increased in size, now measuring approximately 4.5 cm in diameter, up from 3 cm. The previously noted hypoattenuating hepatic lesions have also shown slight growth. Small pleural effusion on the right side. Minor atelectasis in the left lower lobe slightly worsened, likely due to the progressive nature of the disease and the presence of pleural effusion. The hilar and subcarinal lymph nodes, prev. reduced in size, now slightly enlarged again. Right adrenal gland remains slightly enlarged and stable with no significant change in size. No new metastatic lesions were detected in the liver or other abdominal organs.

Summary:

Primary Lung Mass: Increased in size to 4.5 cm.

Hepatic Lesions: Slight growth and increased metabolic activity.  
Lymph Nodes: Slightly re-enlarged hilar and subcarinal nodes.  
Pleural Effusion: Small right-sided pleural effusion noted.  
Atelectasis: Slight worsening of minor atelectasis in the left lower lobe.  
Adrenal Gland: Remains slightly enlarged; increased metabolic activity.

Overall Assessment: Disease progression (PD).

**May 15, 2024:** Tumor board recommends considering clinical trial options due to limited response to standard therapies.

**May 18, 2024:** Detailed assessment of health status. ECOG performance 1. All routine labs, including liver and renal function tests, within normal limits.

===== **Patient 10.1.1**=====

Name: Miller, Jane  
Born: 25.07.1965  
Address: Main Street 78, Potsdam

### **Overview of Tumor Diagnosis and Therapy**

#### **Tumor Diagnosis**

Diagnosis: UICC Stage IV EGFR mutated non-small cell lung cancer (NSCLC)  
Initial Detection: January 10, 2023, following symptoms of persistent cough and chest pain  
Biopsy Date: February 5, 2023, adenocarcinoma of the lung  
Molecular Profile: Panel (tumor purity 60%). EGFR p.E746\_A750del (AF 50%), EGFR T790M, EGFR p.C797S (AF 29%), STK11 p.C210\* (AF 39%).

#### **Therapy Overview**

Initial Treatment:  
Targeted Therapy: Began March 1, 2023, with Osimertinib (T790M). Partial response noted after initial therapy cycle completed by June 15, 2023. Continued therapy until November 2021 (progressive disease).

Subsequent Treatment:  
Further treatment with Pembrolizumab in combination with Paclitaxel/Carboplatin/Bevacizumab and Atezolizumab initiated on December 1, 2023. Staging CT shows disease progression after 6 months.

Current Status:  
**ECOG 1**

**Comorbidities**

Current smoker: 35 py

Hypertension Stage 1

Hyperlipidemia: Managed with Simvastatin 20 mg daily

COPD GOLD 2

**Medication**

Losartan 50mg 1-0-0

Simvastatin 20mg daily 0-0-0-1

Albuterol (inhaler) on demand

Tiotropium (inhaler) on demand

**Chronological Medical Findings:**

**January 2023:** Complaints of persistent cough and bloody sputum. Weight loss of -10kg / 5 months. Chest X-ray revealed a mass in the right lung.

**January 10, 2023:** Comprehensive CT scan (chest and abdomen): Solid, spiculated mass in the right upper lobe of the lung measuring approximately 3.8 cm. Additionally, three small hypoattenuating hepatic lesions noted, to be considered as metastases. Enlarged hilar and subcarinal lymph nodes. Right adrenal gland slightly enlarged, warranting further investigation for metastatic involvement. No evidence of pleural effusion or significant vascular invasion was present. Additional notes: Minor atelectasis in the left lower lobe and mild emphysematous changes in both lungs, consistent with the patient's history of chronic obstructive pulmonary disease (COPD). The abdominal organs, aside from the hepatic lesions and possible adrenal metastasis, appeared unremarkable.

**February 5, 2023:** Biopsy and molecular testing confirmed adenocarcinoma with EGFR T790M mutation. Material sent for further panel testing. Initiated Osimertinib therapy on March 1, 2021. Patient signed consent. Patient in clinical good condition.

**Feb.-June 2023:** Antineoplastic targeted therapy with Osimertinib.

**June 15, 2023:** Follow-up CT scan (chest and abdomen), PET CT scan: Partial response (PR) to treatment. The primary lung mass in the right upper lobe decreased in size, now measuring approximately 3 cm in diameter, down from 3.8 cm. The three previously noted hypoattenuating hepatic lesions have also shown slight reduction in size and decreased metabolic activity, suggesting a positive response to systemic therapy. No new metastatic lesions detected in the liver or other abdominal organs. The previously enlarged hilar and subcarinal lymph nodes have reduced in size, indicating a favorable response to treatment. The right adrenal gland remains slightly enlarged but stable, with no significant change noted, and it continues to show no signs of active disease. Overall: PR.

**July 1, 2023:** Continuation of Osimertinib therapy

**October 3, 2023:** CT scan Chest/Abd.: PD. The primary lung mass in the right upper lobe has increased in size, now measuring approximately 4.5 cm in diameter (prev 3,0 cm). The previously noted hypoattenuating hepatic lesions have also shown slight growth. Additional new metastasis in S7. Small pleural effusion on the right side, minor atelectasis in the left lower lobe has slightly worsened. Hilar and subcarinal lymph nodes drastically enlarged in size. Right adrenal gland with second metastasis. No new metastatic lesions were detected in the liver or other abdominal organs.

**December 1, 2023:** Begin Paclitaxel/Carboplatin/Bevacizumab and Atezolizumab. Received written consent from the patient, ECOG 1.

**May 8, 2024:** Stopped platin because of severe neuropathy (CTCAE III)

**May 10, 2024:** CT Lung/Abdomen: Progressive Disease. Primary lung mass in the right upper lobe has increased in size, now measuring approximately 4.5 cm in diameter, up from 3 cm. The previously noted hypoattenuating hepatic lesions have also shown slight growth. Small pleural effusion on the right side. Minor atelectasis in the left lower lobe slightly worsened, likely due to the progressive nature of the disease and the presence of pleural effusion. The hilar and subcarinal lymph nodes, prev. reduced in size, now slightly enlarged again. Right adrenal gland remains slightly enlarged and stable with no significant change in size. No new metastatic lesions were detected in the liver or other abdominal organs.

Summary:

Primary Lung Mass: Increased in size to 4.5 cm.

Hepatic Lesions: Slight growth and increased metabolic activity.

Lymph Nodes: Slightly re-enlarged hilar and subcarinal nodes.

Pleural Effusion: Small right-sided pleural effusion noted.

Atelectasis: Slight worsening of minor atelectasis in the left lower lobe.

Adrenal Gland: Remains slightly enlarged; increased metabolic activity.

Overall Assessment: Disease progression (PD).

**May 15, 2024:** Tumor board recommends considering clinical trial options due to limited response to standard therapies.

**May 18, 2024:** Detailed assessment of health status. ECOG performance 1. All routine labs, including liver and renal function tests, within normal limits.

**May 20, 2024:** Presentation with shortness of breath via emergency.

CT scan with multiple infiltrates.

CRP elevated at 190. Started on Meropenem. Admitted for inpatient care.

===== **Patient 10.1.2**=====



Name: Miller, Jane  
Born: 25.07.1965  
Address: Main Street 78, Potsdam

## Overview of Tumor Diagnosis and Therapy

### Tumor Diagnosis

Diagnosis: UICC Stage IV EGFR mutated non-small cell lung cancer (NSCLC)  
Initial Detection: January 10, 2023, following symptoms of persistent cough and chest pain  
Biopsy Date: February 5, 2023, adenocarcinoma of the lung  
Molecular Profile: Panel (tumor purity 60%). EGFR p.E746\_A750del (AF 50%), EGFR T790M, EGFR p.C797S (AF 29%), STK11 p.C210\* (AF 39%).

### Therapy Overview

Initial Treatment:

Targeted Therapy: Began March 1, 2023, with Osimertinib (T790M). Partial response noted after initial therapy cycle completed by June 15, 2023. Continued therapy until November 2021 (progressive disease).

Subsequent Treatment:

Further treatment with Pembrolizumab in combination with Paclitaxel/Carboplatin/Bevacizumab and Atezolizumab initiated on December 1, 2023. Staging CT shows disease progression after 6 months.

Current Status:

**ECOG 1**

### Comorbidities

Current smoker: 35 py

Hypertension Stage 1

Hyperlipidemia: Managed with Simvastatin 20 mg daily

COPD GOLD 2

### Medication

Losartan 50mg 1-0-0

Simvastatin 20mg daily 0-0-0-1

Albuterol (inhaler) on demand

Tiotropium (inhaler) on demand

### Chronological Medical Findings:

**January 2023:** Complaints of persistent cough and bloody sputum. Weight loss of -10kg / 5 months. Chest X-ray revealed a mass in the right lung.

**January 10, 2023:** Comprehensive CT scan (chest and abdomen): Solid, spiculated mass in the right upper lobe of the lung measuring approximately 3.8 cm. Additionally,

three small hypoattenuating hepatic lesions noted, to be considered as metastases. Enlarged hilar and subcarinal lymph nodes. Right adrenal gland slightly enlarged, warranting further investigation for metastatic involvement. No evidence of pleural effusion or significant vascular invasion was present. Additional notes: Minor atelectasis in the left lower lobe and mild emphysematous changes in both lungs, consistent with the patient's history of chronic obstructive pulmonary disease (COPD). The abdominal organs, aside from the hepatic lesions and possible adrenal metastasis, appeared unremarkable.

**February 5, 2023:** Biopsy and molecular testing confirmed adenocarcinoma with EGFR T790M mutation. Material sent for further panel testing. Initiated Osimertinib therapy on March 1, 2021. Patient signed consent. Patient in clinical good condition.

**Feb.-June 2023:** Antineoplastic targeted therapy with Osimertinib.

**June 15, 2023:** Follow-up CT scan (chest and abdomen), PET CT scan: Partial response (PR) to treatment. The primary lung mass in the right upper lobe decreased in size, now measuring approximately 3 cm in diameter, down from 3.8 cm. The three previously noted hypoattenuating hepatic lesions have also shown slight reduction in size and decreased metabolic activity, suggesting a positive response to systemic therapy. No new metastatic lesions detected in the liver or other abdominal organs. The previously enlarged hilar and subcarinal lymph nodes have reduced in size, indicating a favorable response to treatment. The right adrenal gland remains slightly enlarged but stable, with no significant change noted, and it continues to show no signs of active disease. Overall: PR.

**July 1, 2023:** Continuation of Osimertinib therapy

**October 3, 2023:** CT scan Chest/Abd.: PD. The primary lung mass in the right upper lobe has increased in size, now measuring approximately 4.5 cm in diameter (prev 3.0 cm). The previously noted hypoattenuating hepatic lesions have also shown slight growth. Additional new metastasis in S7. Small pleural effusion on the right side, minor atelectasis in the left lower lobe has slightly worsened. Hilar and subcarinal lymph nodes drastically enlarged in size. Right adrenal gland with second metastasis. No new metastatic lesions were detected in the liver or other abdominal organs.

**December 1, 2023:** Begin Paclitaxel/Carboplatin/Bevacizumab and Atezolizumab. Received written consent from the patient, ECOG 1.

**May 10, 2024:** CT Lung/Abdomen: Progressive Disease. Primary lung mass in the right upper lobe has increased in size, now measuring approximately 4.5 cm in diameter, up from 3 cm. The previously noted hypoattenuating hepatic lesions have also shown slight growth. Small pleural effusion on the right side. Minor atelectasis in the left lower lobe slightly worsened, likely due to the progressive nature of the disease and the presence of pleural effusion. The hilar and subcarinal lymph nodes, prev. reduced in size, now slightly enlarged again. Right adrenal gland remains slightly enlarged and stable with no significant change in size. No new metastatic lesions were detected in the liver or other abdominal organs.

Summary:

Primary Lung Mass: Increased in size to 4.5 cm.

Hepatic Lesions: Slight growth and increased metabolic activity.

Lymph Nodes: Slightly re-enlarged hilar and subcarinal nodes.  
Pleural Effusion: Small right-sided pleural effusion noted.  
Atelectasis: Slight worsening of minor atelectasis in the left lower lobe.  
Adrenal Gland: Remains slightly enlarged; increased metabolic activity.

Overall Assessment: Disease progression (PD).

**May 11, 2024:** Seizures, CT scan: 3 metastases in the brain:

1x2.5 cm lesion in the left frontal lobe.

A 1.8 cm lesion in the right parietal lobe. A 1.2 cm lesion in the cerebellum.

Initiated Prednisone. Begin with Keppra.

Consultation with the radiation oncology team, recommended

whole-brain radiotherapy (30 Gy in 10 fractions).

Surgical resection deemed not possible due to location of metastases.

**May 15, 2024:** Tumor board recommends considering clinical trial options due to limited response to standard therapies.

**May 18, 2024:** Detailed assessment of health status. ECOG performance 1. All routine labs, including liver and renal function tests, within normal limits.

#### ===== Patient 10.1.3 =====

Name: Miller, Jane  
Born: 25.07.1965  
Address: Main Street 78, Potsdam

### Overview of Tumor Diagnosis and Therapy

#### Tumor Diagnosis

Diagnosis: UICC Stage IV EGFR mutated non-small cell lung cancer (NSCLC)  
Initial Detection: January 10, 2023, following symptoms of persistent cough and chest pain  
Biopsy Date: February 5, 2023, adenocarcinoma of the lung  
Molecular Profile: Panel (tumor purity 60%). EGFR p.E746\_A750del (AF 50%), EGFR T790M, EGFR p.C797S (AF 29%), STK11 p.C210\* (AF 39%).

#### Therapy Overview

Initial Treatment:

Targeted Therapy: Began March 1, 2023, with Osimertinib (T790M). Partial response noted after initial therapy cycle completed by June 15, 2023. Continued therapy until November 2021 (progressive disease).

Subsequent Treatment:

Further treatment with Pembrolizumab in combination with Paclitaxel/Carboplatin/

Bevacizumab and Atezolizumab initiated on December 1, 2023. Staging CT shows disease progression after 6 months.

Current Status:

**ECOG 1**

### **Comorbidities**

Current smoker: 35 py

Hypertension Stage 1

Hyperlipidemia: Managed with Simvastatin 20 mg daily

COPD GOLD 2 Diabetes Mellitus (II) Diabetic Retinopathy

### **Medication**

Losartan 50mg 1-0-0

Simvastatin 20mg daily 0-0-0-1

Metformin (800 mg 1-0-1)

Albuterol (inhaler) on demand

Tiotropium (inhaler) on demand

Lucentis

### **Chronological Medical Findings:**

**January 2023:** Complaints of persistent cough and bloody sputum. Weight loss of -10kg / 5 months. Chest X-ray revealed a mass in the right lung.

**January 10, 2023:** Comprehensive CT scan (chest and abdomen): Solid, spiculated mass in the right upper lobe of the lung measuring approximately 3.8 cm. Additionally, three small hypoattenuating hepatic lesions noted, to be considered as metastases. Enlarged hilar and subcarinal lymph nodes. Right adrenal gland slightly enlarged, warranting further investigation for metastatic involvement. No evidence of pleural effusion or significant vascular invasion was present. Additional notes: Minor atelectasis in the left lower lobe and mild emphysematous changes in both lungs, consistent with the patient's history of chronic obstructive pulmonary disease (COPD). The abdominal organs, aside from the hepatic lesions and possible adrenal metastasis, appeared unremarkable.

**February 5, 2023:** Biopsy and molecular testing confirmed adenocarcinoma with EGFR T790M mutation. Material sent for further panel testing. Initiated Osimertinib therapy on March 1, 2021. Patient signed consent. Patient in clinical good condition.

**Feb.-June 2023:** Antineoplastic targeted therapy with Osimertinib.

**June 15, 2023:** Follow-up CT scan (chest and abdomen), PET CT scan: Partial response (PR) to treatment. The primary lung mass in the right upper lobe decreased in size, now measuring approximately 3 cm in diameter, down from 3.8 cm. The three previously noted hypoattenuating hepatic lesions have also shown slight reduction in size and decreased metabolic activity, suggesting a positive response to systemic therapy. No new metastatic lesions detected in the liver or other abdominal organs. The

previously enlarged hilar and subcarinal lymph nodes have reduced in size, indicating a favorable response to treatment. The right adrenal gland remains slightly enlarged but stable, with no significant change noted, and it continues to show no signs of active disease. Overall: PR.

**July 1, 2023:** Continuation of Osimertinib therapy

**October 3, 2023:** CT scan Chest/Abd.: PD. The primary lung mass in the right upper lobe has increased in size, now measuring approximately 4.5 cm in diameter (prev 3,0 cm). The previously noted hypoattenuating hepatic lesions have also shown slight growth. Additional new metastasis in S7. Small pleural effusion on the right side, minor atelectasis in the left lower lobe has slightly worsened. Hilar and subcarinal lymph nodes drastically enlarged in size. Right adrenal gland with second metastasis. No new metastatic lesions were detected in the liver or other abdominal organs.

**December 1, 2023:** Begin Paclitaxel/Carboplatin/Bevacizumab and Atezolizumab. Received written consent from the patient, ECOG 1.

**May 10, 2024:** CT Lung/Abdomen: Progressive Disease. Primary lung mass in the right upper lobe has increased in size, now measuring approximately 4.5 cm in diameter, up from 3 cm. The previously noted hypoattenuating hepatic lesions have also shown slight growth. Small pleural effusion on the right side. Minor atelectasis in the left lower lobe slightly worsened, likely due to the progressive nature of the disease and the presence of pleural effusion. The hilar and subcarinal lymph nodes, prev. reduced in size, now slightly enlarged again. Right adrenal gland remains slightly enlarged and stable with no significant change in size. No new metastatic lesions were detected in the liver or other abdominal organs.

Summary:

Primary Lung Mass: Increased in size to 4.5 cm.

Hepatic Lesions: Slight growth and increased metabolic activity.

Lymph Nodes: Slightly re-enlarged hilar and subcarinal nodes.

Pleural Effusion: Small right-sided pleural effusion noted.

Atelectasis: Slight worsening of minor atelectasis in the left lower lobe.

Adrenal Gland: Remains slightly enlarged; increased metabolic activity.

Overall Assessment: Disease progression (PD).

**May 15, 2024:** Tumor board recommends considering clinical trial options due to limited response to standard therapies.

**May 18, 2024:** Detailed assessment of health status.

Patient progressively in worse conditions, currently ECOG performance 2.

All routine labs, including liver and renal function tests, within normal limits.

===== **Patient 11.1**=====

**Patient Information**

Name: Smith, Anna

Born: 10.03.1980

Address: Another Avenue 89, Augsburg

**Overview of Tumor Diagnosis and Therapy****Tumor Diagnosis**

**Diagnosis:** UICC Stage IV well-differentiated, non-functioning neuroendocrine tumor of the pancreas

Initial Detection: June 5, 2021, following symptoms of abdominal pain and weight loss

Biopsy Date: July 1, 2021, well-differentiated neuroendocrine tumor of the pancreas

Molecular Profile: High Tumor Mutational Burden (TMB-H,  $\geq 10$  mut/Mb, F1CDx assay)

Therapy Overview

**Initial Treatment:**

Chemotherapy: Began July 20, 2021, with Capecitabine and Temozolomide regimen. Partial response noted after initial chemotherapy cycle completed by October 10, 2021. Continued therapy until January 2022 (progressive disease).

Subsequent Treatment:

Further chemotherapy with Everolimus initiated on February 1, 2022. Staging CT shows disease progression after 6 months.

Current Status: ECOG 1

**Comorbidities**

Hypertension Stage 2

History of appendectomy 2001

Medication

Ramipril 10mg 1-0-0

Amlodipin 5mg 1-0-0

Hydrochlorothiazide 12.5mg 1-0-0

**Chronological Medical Findings:**

**May 10, 2021:** Complained of abdominal pain and weight loss. Abdominal ultrasound revealed a mass in the pancreas. Referred to oncologist. No symptoms attributable to carcinoid syndrome.

**June 5, 2021:** CT scan of the abdomen and pelvis: Revealed a well-defined mass in the head of the pancreas measuring approximately 4.5 cm with surrounding lymphadenopathy. No signs of vascular invasion, but multiple small hepatic lesions were identified, indicating metastatic disease. No evidence of bowel obstruction, but slight dilation of the pancreatic duct was observed.

**July 1, 2021:** Biopsy and molecular testing confirmed a well-differentiated neuroendocrine tumor with a high tumor mutational burden (TMB-H,  $\geq 10$  mut/Mb, F1CDx assay), Grade 3. Initiated Capecitabine and Temozolomide chemotherapy regimen on July 20, 2021.

**October 10, 2021:** Follow-up CT scan (chest, abdomen, and pelvis): Partial response to treatment observed, with the primary pancreatic mass reducing to 3.5 cm in diameter. Hepatic lesions showed slight reduction in size and metabolic activity. No new metastatic lesions were detected, but mild ascites persisted.

**January 1, 2022:** Continued Capecitabine and Temozolomide therapy, with staging scans showing moderate disease progression. Primary mass increased to 4.0 cm, with new peritoneal nodules.

**February 1, 2022:** Initiated Everolimus therapy due to progression on previous regimen.

**August 1, 2022:** Follow-up MRI scan (abdomen and pelvis): MRI indicated further disease progression, with the primary tumor enlarging to 4.8 cm and increased involvement of adjacent hepatic structures. Peritoneal nodules showed slight growth, and moderate ascites was present. There was no evidence of bowel obstruction or significant vascular invasion.

**November 15, 2022:** Tumor board recommends considering clinical trial options due to limited response to standard therapies.

**December 1, 2022:** Detailed assessment of health status. ECOG performance status 1. All routine labs, including liver and renal function tests, within normal limits.

#### ===== Patient 11.1.1 =====

##### **Patient Information**

Name: Smith, Anna

Born: 10.03.1980

Address: Another Avenue 89, Augsburg

##### **Overview of Tumor Diagnosis and Therapy**

##### **Tumor Diagnosis**

**Diagnosis:** UICC Stage IV well-differentiated, non-functioning neuroendocrine tumor of the pancreas

Initial Detection: June 5, 2021, following symptoms of abdominal pain and weight loss

Biopsy Date: July 1, 2021, well-differentiated neuroendocrine tumor of the pancreas

Molecular Profile: High Tumor Mutational Burden (TMB-H,  $\geq 10$  mut/Mb, F1CDx assay)

### Therapy Overview

#### Initial Treatment:

Chemotherapy: Began July 20, 2021, with Capecitabine and Temozolomide regimen. Partial response noted after initial chemotherapy cycle completed by October 10, 2021. Continued therapy until January 2022 (progressive disease).

#### Subsequent Treatment:

Further chemotherapy with Everolimus initiated on February 1, 2022. Staging CT shows disease progression after 6 months.

Current Status: ECOG 1

#### Comorbidities

Hypertension Stage 2

History of appendectomy 2001

Systemic lupus erythematoses (last systemic therapy 09/2020)

#### Medication

Ramipril 10mg 1-0-0

Amlodipin 5mg 1-0-0

Hydrochlorothiazide 12.5mg 1-0-0 Hydroxychloroquine 200mg 1-0-0

#### Chronological Medical Findings:

**May 10, 2021:** Complained of abdominal pain and weight loss. Abdominal ultrasound revealed a mass in the pancreas. Referred to oncologist. No symptoms attributable to carcinoid syndrome.

**June 5, 2021:** CT scan of the abdomen and pelvis: Revealed a well-defined mass in the head of the pancreas measuring approximately 4.5 cm with surrounding lymphadenopathy. No signs of vascular invasion, but multiple small hepatic lesions were identified, indicating metastatic disease. No evidence of bowel obstruction, but slight dilation of the pancreatic duct was observed.

**July 1, 2021:** Biopsy and molecular testing confirmed a well-differentiated neuroendocrine tumor with a high tumor mutational burden (TMB-H,  $\geq 10$  mut/Mb, F1CDx assay), Grade 3. Initiated Capecitabine and Temozolomide chemotherapy regimen on July 20, 2021.

**October 10, 2021:** Follow-up CT scan (chest, abdomen, and pelvis): Partial response to treatment observed, with the primary pancreatic mass reducing to 3.5 cm in diameter. Hepatic lesions showed slight reduction in size and metabolic activity. No new metastatic lesions were detected, but mild ascites persisted.



**January 1, 2022:** Continued Capecitabine and Temozolomide therapy, with staging scans showing moderate disease progression. Primary mass increased to 4.0 cm, with new peritoneal nodules.

**February 1, 2022:** Initiated Everolimus therapy due to progression on previous regimen.

**August 1, 2022:** Follow-up MRI scan (abdomen and pelvis): MRI indicated further disease progression, with the primary tumor enlarging to 4.8 cm and increased involvement of adjacent hepatic structures. Peritoneal nodules showed slight growth, and moderate ascites was present. There was no evidence of bowel obstruction or significant vascular invasion.

**November 15, 2022:** Tumor board recommends considering clinical trial options due to limited response to standard therapies.

**December 1, 2022:** Detailed assessment of health status. ECOG performance status 1. All routine labs, including liver and renal function tests, within normal limits.

===== **Patient 11.1.2** =====

**Patient Information**

Name: Smith, Anna

Born: 10.03.1980

Address: Another Avenue 89, Augsburg

**Overview of Tumor Diagnosis and Therapy**

**Tumor Diagnosis**

**Diagnosis:** UICC Stage IV well-differentiated, non-functioning neuroendocrine tumor of the pancreas

Initial Detection: June 5, 2021, following symptoms of abdominal pain and weight loss

Biopsy Date: July 1, 2021, well-differentiated neuroendocrine tumor of the pancreas

Molecular Profile: High Tumor Mutational Burden (TMB-H,  $\geq 10$  mut/Mb, F1CDx assay)

**Therapy Overview**

**Initial Treatment:**

Chemotherapy: Began July 20, 2021, with Capecitabine and Temozolomide regimen. Partial response noted after initial chemotherapy cycle completed by October 10, 2021. Continued therapy until January 2022 (progressive disease).

Subsequent Treatment:

Further chemotherapy with Everolimus initiated on February 1, 2022. Staging CT shows disease progression after 6 months.

**Current Status:**

ECOG 1

### Comorbidities

Smoker 35 py

Alcohol dependence

Hepatitis C

Hypertension Stage 2

History of appendectomy 2001

### Medication

Glecaprevir/Pibrentasvir 100mg/40mg 3-0-0

Ramipril 10mg 1-0-0

Amlodipin 5mg 1-0-0

Hydrochlorothiazide 12.5mg 1-0-0

### Chronological Medical Findings:

**May 10, 2021:** Complained of abdominal pain and weight loss. Abdominal ultrasound revealed a mass in the pancreas. Referred to oncologist. No symptoms attributable to carcinoid syndrome.

**June 5, 2021:** CT scan of the abdomen and pelvis: Revealed a well-defined mass in the head of the pancreas measuring approximately 4.5 cm with surrounding lymphadenopathy. No signs of vascular invasion, but multiple small hepatic lesions were identified, indicating metastatic disease. No evidence of bowel obstruction, but slight dilation of the pancreatic duct was observed.

**July 1, 2021:** Biopsy and molecular testing confirmed a well-differentiated neuroendocrine tumor with a high tumor mutational burden (TMB-H,  $\geq 10$  mut/Mb, F1CDx assay), Grade 3. Initiated Capecitabine and Temozolomide chemotherapy regimen on July 20, 2021.

**October 10, 2021:** Follow-up CT scan (chest, abdomen, and pelvis): Partial response to treatment observed, with the primary pancreatic mass reducing to 3.5 cm in diameter. Hepatic lesions showed slight reduction in size and metabolic activity. No new metastatic lesions were detected, but mild ascites persisted.

**January 1, 2022:** Continued Capecitabine and Temozolomide therapy, with staging scans showing moderate disease progression. Primary mass increased to 4.0 cm, with new peritoneal nodules.

**February 1, 2022:** Initiated Everolimus therapy due to progression on previous regimen.

**August 1, 2022:** Follow-up MRI scan (abdomen and pelvis): MRI indicated further disease progression, with the primary tumor enlarging to 4.8 cm and increased involvement of adjacent hepatic structures. Peritoneal nodules showed slight growth, and moderate ascites was present. There was no evidence of bowel obstruction or significant vascular invasion.

**November 15, 2022:** Tumor board recommends considering clinical trial options due to limited response to standard therapies.

**December 1, 2022:** Detailed assessment of health status. ECOG performance status 1. Routine labs show elevated liver enzymes: ALT 100 U/L, AST 89 U/L, total bilirubin 2.8 mg/dl, direct bilirubin 1.6 mg/dl, Albumin 3.0 g/dl .

### ===== **Patient 11.1.3** =====

#### **Patient Information**

Name: Smith, Anna

Born: 10.03.1980

Address: Another Avenue 89, Augsburg

#### **Overview of Tumor Diagnosis and Therapy**

##### **Tumor Diagnosis**

**Diagnosis:** UICC Stage IV well-differentiated, non-functioning neuroendocrine tumor of the pancreas

Initial Detection: June 5, 2021, following symptoms of abdominal pain and weight loss

Biopsy Date: July 1, 2021, well-differentiated neuroendocrine tumor of the pancreas

Molecular Profile: High Tumor Mutational Burden (TMB-H,  $\geq 10$  mut/Mb, F1CDx assay)

##### **Therapy Overview**

###### **Initial Treatment:**

Chemotherapy: Began July 20, 2021, with Capecitabine and Temozolomide regimen. Partial response noted after initial chemotherapy cycle completed by October 10, 2021. Continued therapy until January 2022 (progressive disease).

###### **Subsequent Treatment:**

Further chemotherapy with Everolimus initiated on February 1, 2022. Staging CT shows disease progression after 6 months.

Current Status: ECOG 1

## Comorbidities

Hypertension Stage 2

History of appendectomy 2001

History of active tuberculosis 2003

## Medication

Ramipril 10mg 1-0-0

Amlodipin 5mg 1-0-0

Hydrochlorothiazide 12.5mg 1-0-0

## Chronological Medical Findings:

**May 10, 2021:** Complained of abdominal pain and weight loss. Abdominal ultrasound revealed a mass in the pancreas. Referred to oncologist. No symptoms attributable to carcinoid syndrome.

**June 5, 2021:** CT scan of the abdomen and pelvis: Revealed a well-defined mass in the head of the pancreas measuring approximately 4.5 cm with surrounding lymphadenopathy. No signs of vascular invasion, but multiple small hepatic lesions were identified, indicating metastatic disease. No evidence of bowel obstruction, but slight dilation of the pancreatic duct was observed.

**July 1, 2021:** Biopsy and molecular testing confirmed a well-differentiated neuroendocrine tumor with a high tumor mutational burden (TMB-H,  $\geq 10$  mut/Mb, F1CDx assay), Grade 3. Initiated Capecitabine and Temozolomide chemotherapy regimen on July 20, 2021.

**October 10, 2021:** Follow-up CT scan (chest, abdomen, and pelvis): Partial response to treatment observed, with the primary pancreatic mass reducing to 3.5 cm in diameter. Hepatic lesions showed slight reduction in size and metabolic activity. No new metastatic lesions were detected, but mild ascites persisted.

**January 1, 2022:** Continued Capecitabine and Temozolomide therapy, with staging scans showing moderate disease progression. Primary mass increased to 4.0 cm, with new peritoneal nodules.

**February 1, 2022:** Initiated Everolimus therapy due to progression on previous regimen.

**August 1, 2022:** Follow-up MRI scan (abdomen and pelvis): MRI indicated further disease progression, with the primary tumor enlarging to 4.8 cm and increased involvement of adjacent hepatic structures. Peritoneal nodules showed slight growth, and moderate ascites was present. There was no evidence of bowel obstruction or significant vascular invasion.

**August 5, 2022:** Brain MRI. Multiple metastases, specifically three lesions in the right hemisphere: two in the right parietal lobe, and one in the right occipital lobe. Incidental findings included scattered white matter hyperintensities consistent with chronic microvascular ischemic changes.

**November 15, 2022:** Tumor board recommends considering clinical trial options due to limited response to standard therapies.

**December 1, 2022:** Detailed assessment of health status. ECOG performance status 1. All routine labs, including liver and renal function tests, within normal limits.